

GOLDEN ISLES MEDICAL SPA

PROPERTY OF DR. JILL LEZAIC

Under the direction of Dr. Anna Cabecca & Dr. Jill Lezaic

WELCOME TO OUR PRACTICE

✘ The treatments & products outlined this evening are designed to:

+ Eliminate wrinkles

✘ Around the eyes

✘ Above the lips

✘ Between the eyes

✘ Across the forehead

+ Remove sun spots or age spots

+ Tighten the skin of the face, neck & body

PROPERTY OF DR. JILL LEZAIC

COMPLETE SOLUTION FOR LASER SERVICES

○ Laser Procedures

- > Hair Removal
- > Vein Removal
- > Texture, Pores Improvement
- > Sun Spot Removal
- > Acne Treatment
- > Skin Resurfacing: Eliminate Wrinkles & Folds, Tighten Eyelids, Improve Acne scars
- > Skin Tightening: Improve Nasolabial Folds, Tighten Jowls & Neck, Lift Eyebrows
- > Tattoo Removal

× Fillers

- + Juvederm
- + Restylane

× Sclerotherapy

× Vibrationabrasion

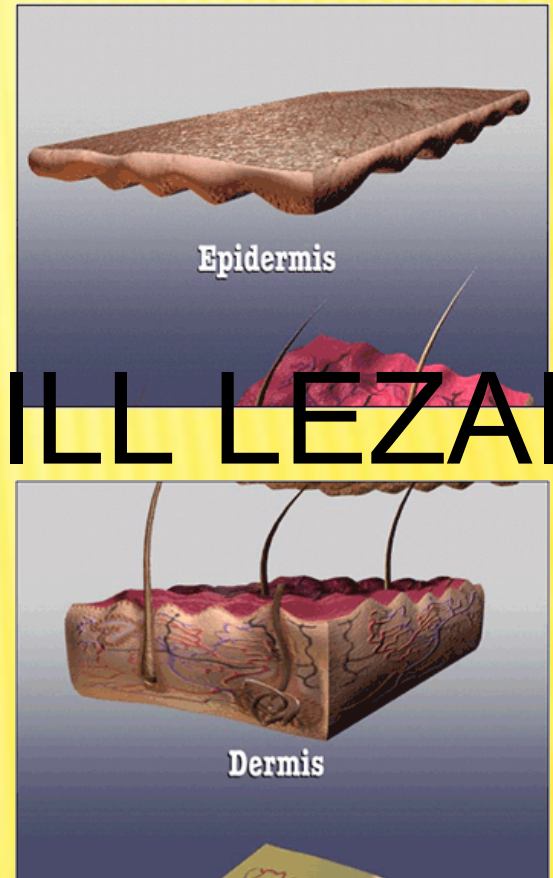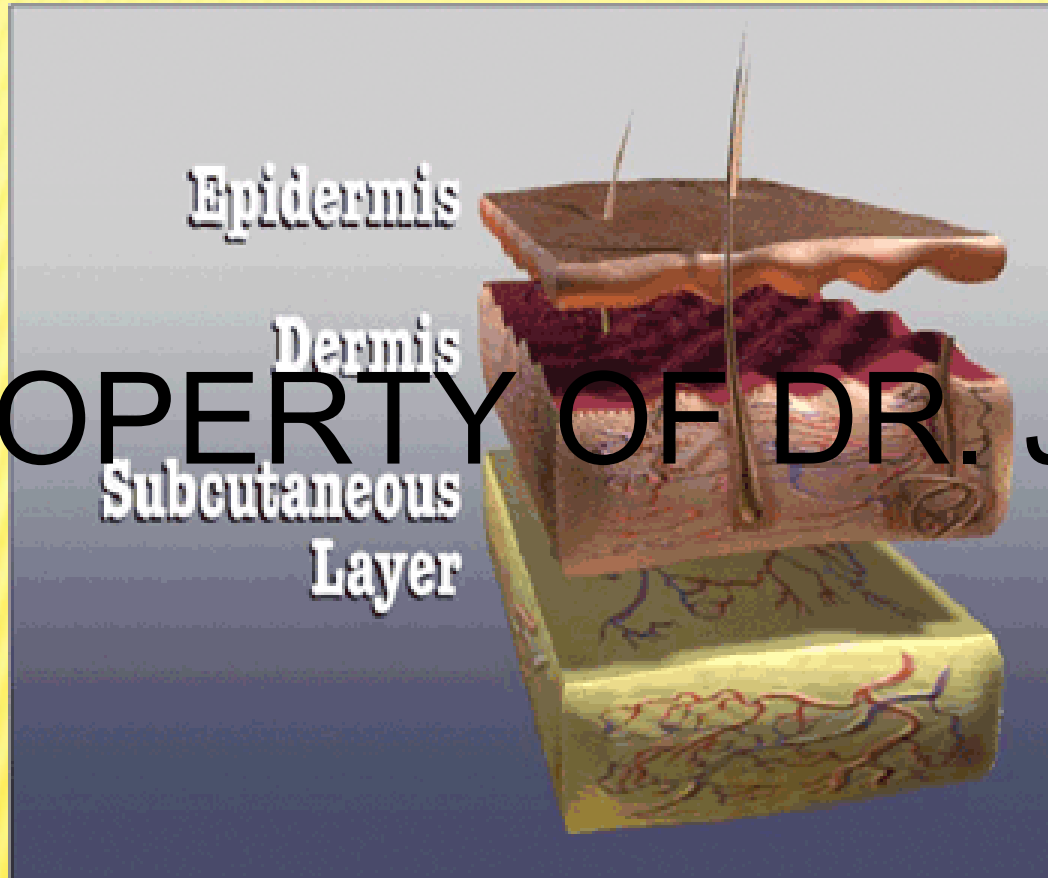
× Vibrafusion

× Chemical Peels

× Facials

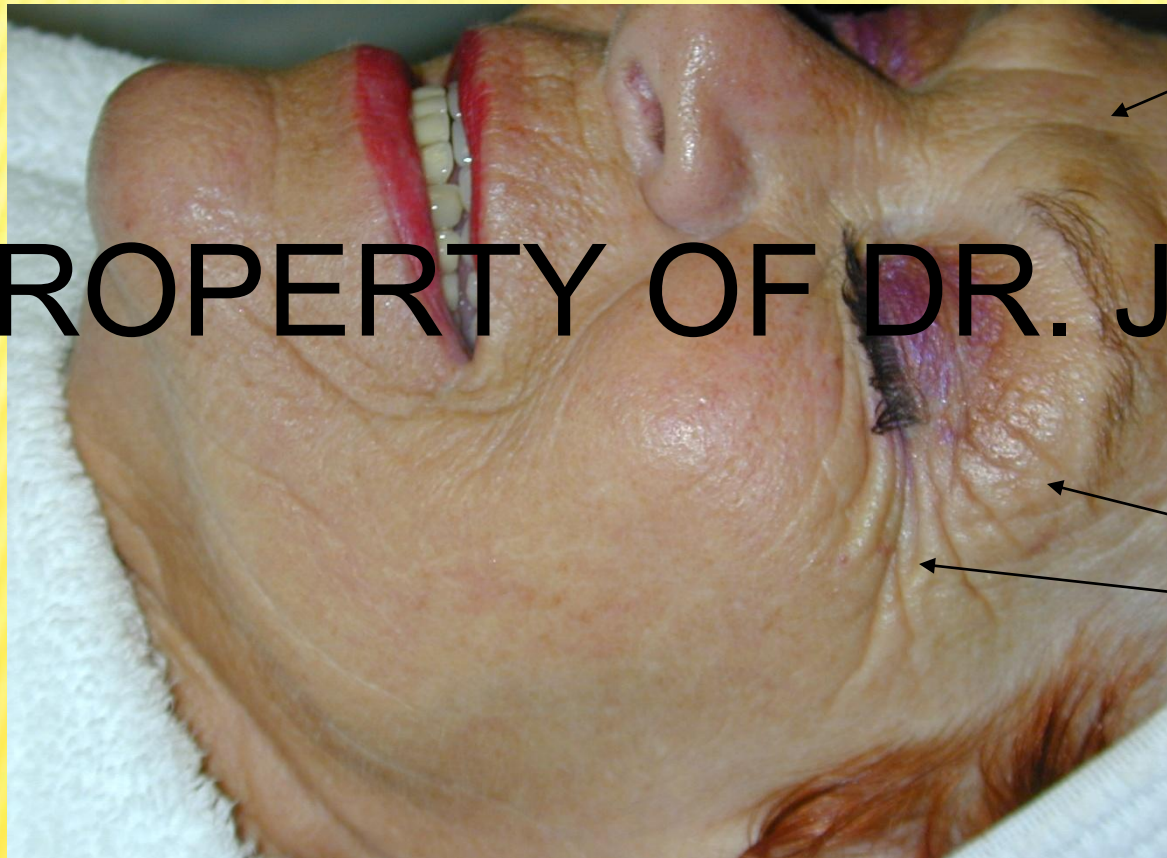PROPERTY OF DR. JILL LEZAIC

STRUCTURE OF HUMAN SKIN



PROPERTY OF DR. JILL LEZAIC

DYNAMIC WRINKLES

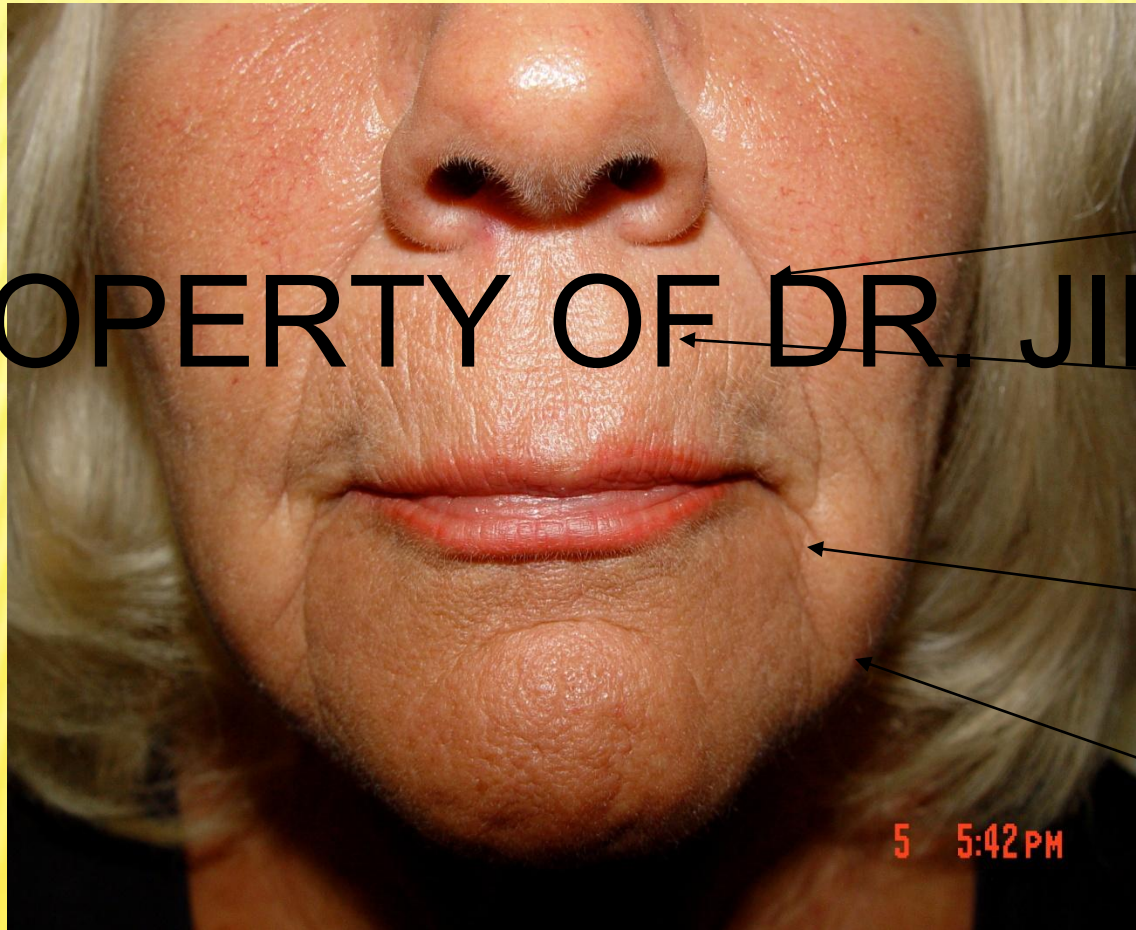

← Glabellar Vertical
"Frown" Lines

← Periorbital Rhytides
"Crow's Feet"

PROPERTY OF DR. JILL LEZAIC

WRINKLES, FOLDS, SAGGING



Nasolabial Folds

PROPERTY OF DR. JILL LEZAIC

Perioral

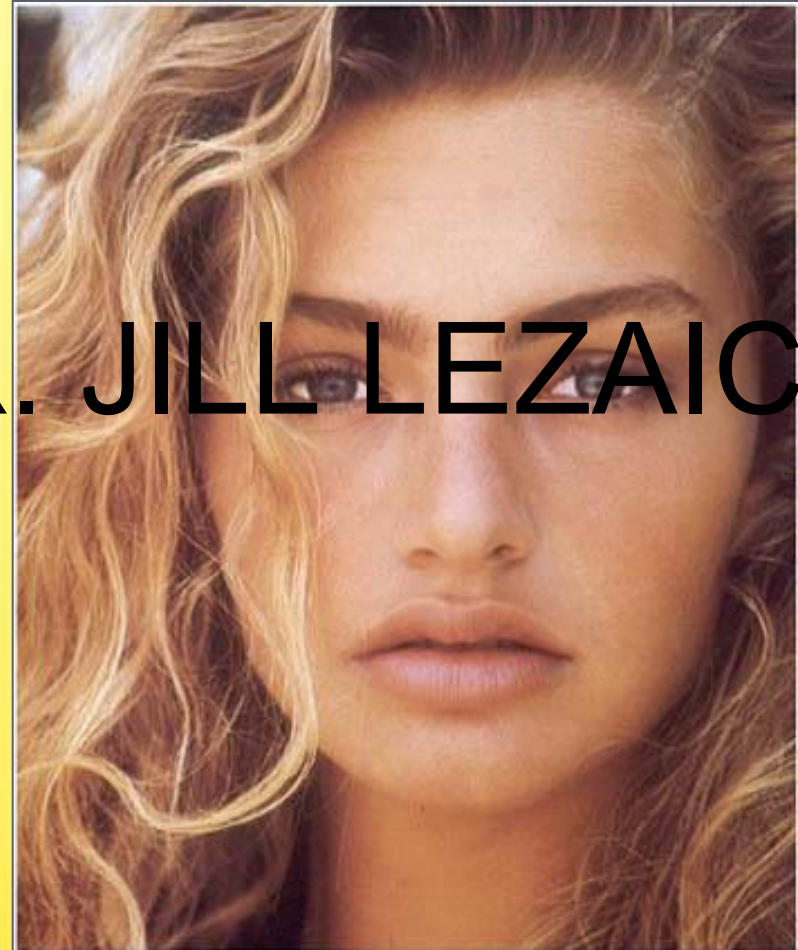
"Smokers Lines"

Oral Commisures

Jowls

LASERS & FILLERS

- ✘ Produces significant overall greater improvements than either one alone.
- ✘ Ex. Genesis immediately before the filler.
- ✘ Absolutely the best thing to immediately improve wrinkles.
- ✘ In the same tx time, you can benefit from permanent collagen stimultaiothn.
- ✘ Fillers will prolong the effects of laser treatments .



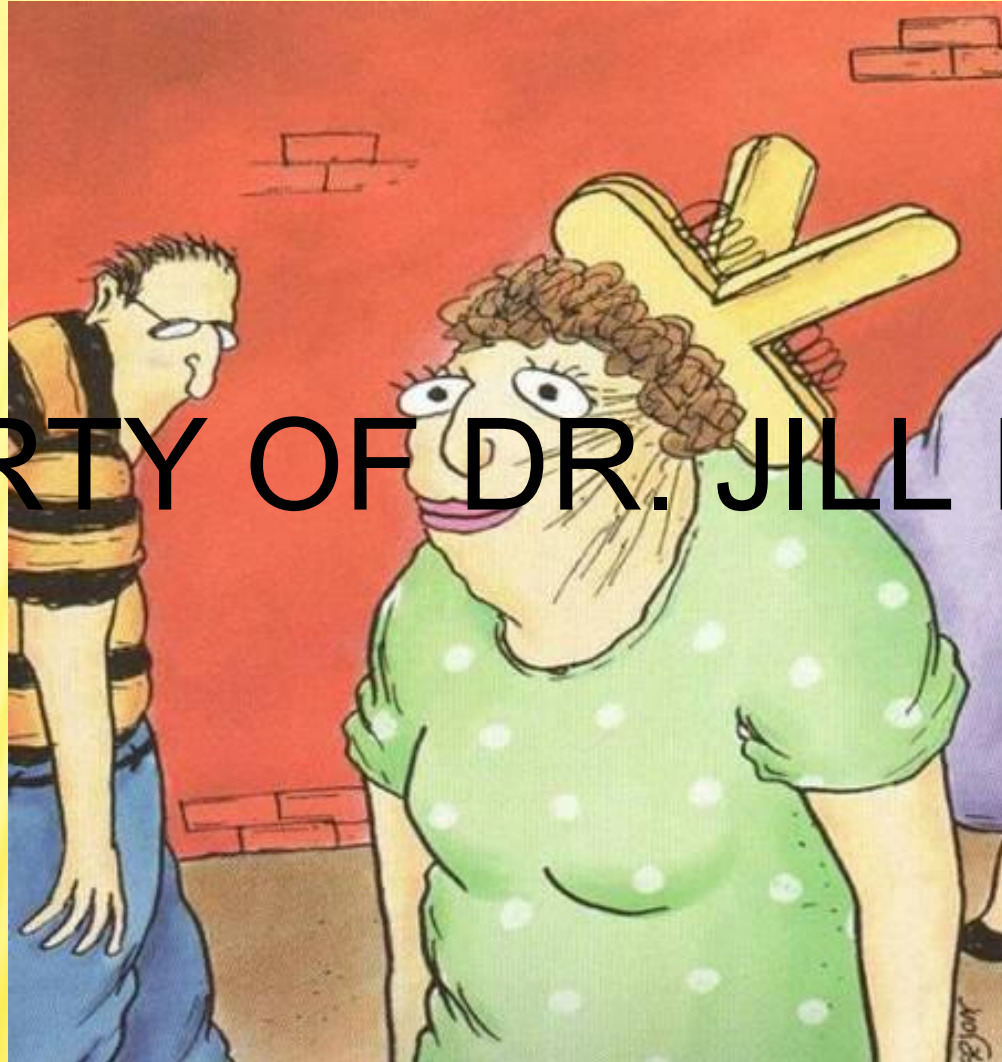PROPERTY OF DR. JILL LEZAIO

PROPERTY OF DR. JILL LEZAIC

TITAN SKIN TIGHTENING

Golden Isles Medical Spa

WHAT IS SKIN LAXITY?



PROPERTY OF DR. JILL LEZAIC

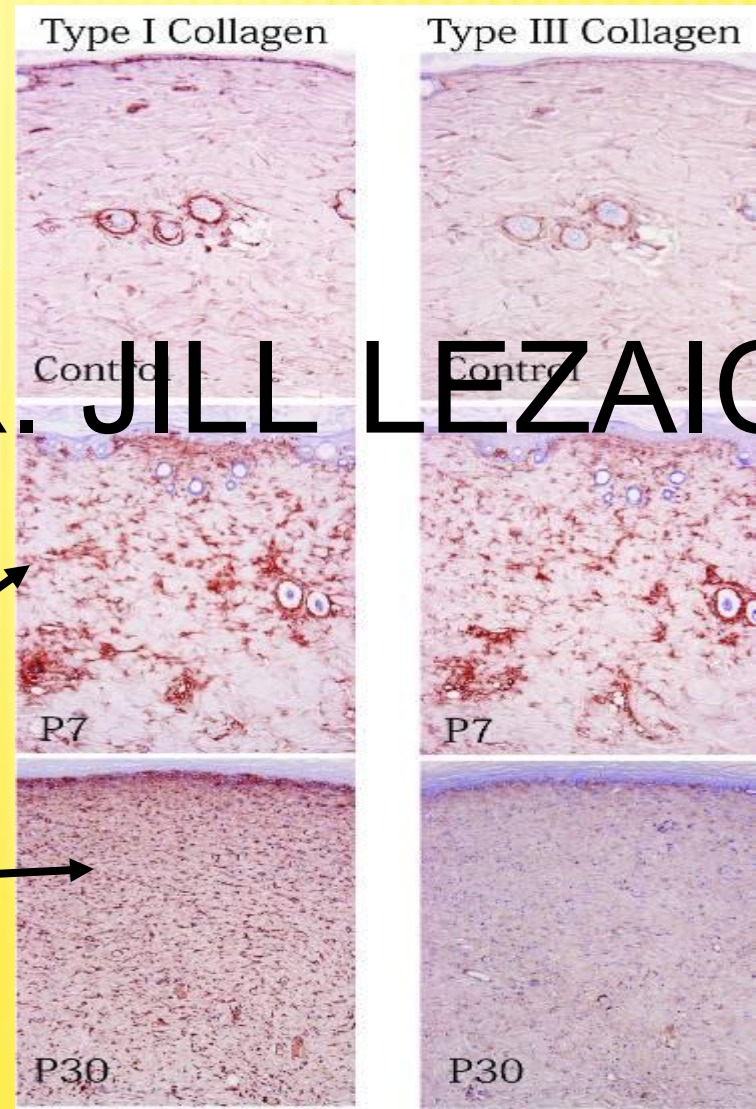
Now offering the incredibly affordable face lift clip

COLLAGEN STIMULATION

- ✗ Measures collagen stimulation of Type I and Type III collagen
- ✗ Preferential proliferation of Type I to type III collagen 7 and 30 days post treatment
- ✗ Type I collagen is smooth
- ✗ Type III is rougher
- + Nominally a product wants to preferentially stimulate Type I collagen

PROPERTY OF DR. JILL LEZAIC

New collagen shows as higher contrast red
Over 16 published Titan clinical studies are available



TITAN LOWER FACE & NECK



PROPERTY OF DR. JILL LEZAIC

Treatment of Cheek and Neck Facial Laxity

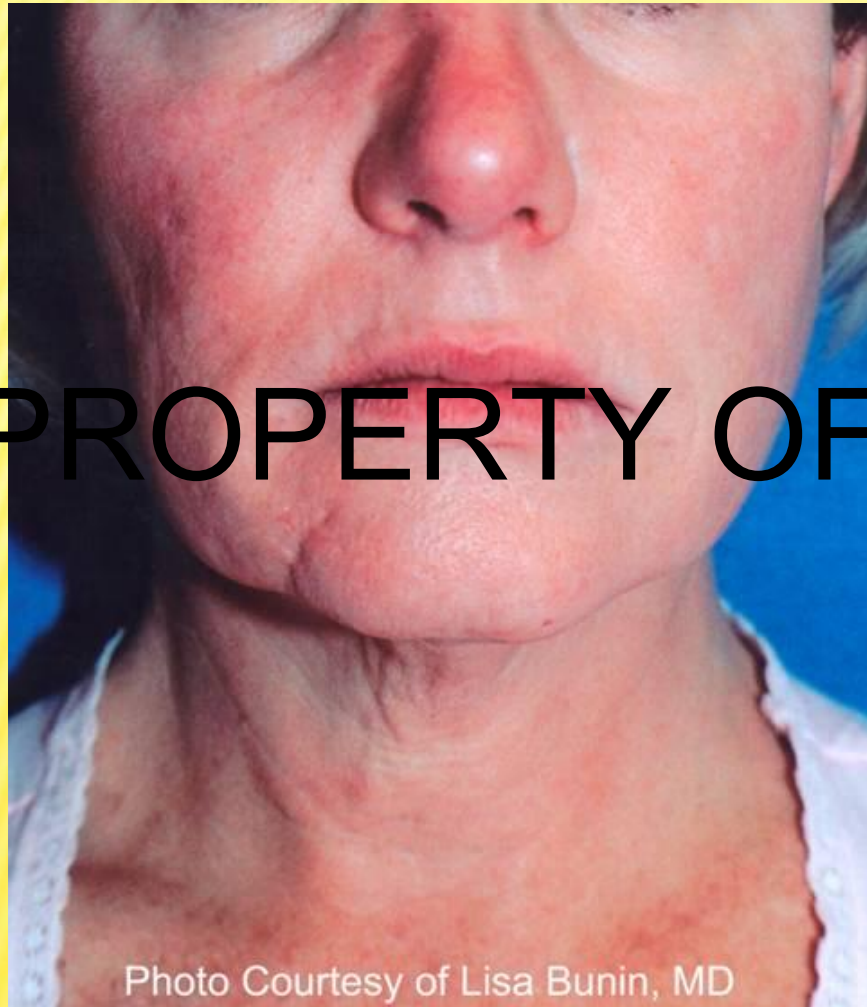

Photo Courtesy of Lisa Bunin, MD

Pre-treatment

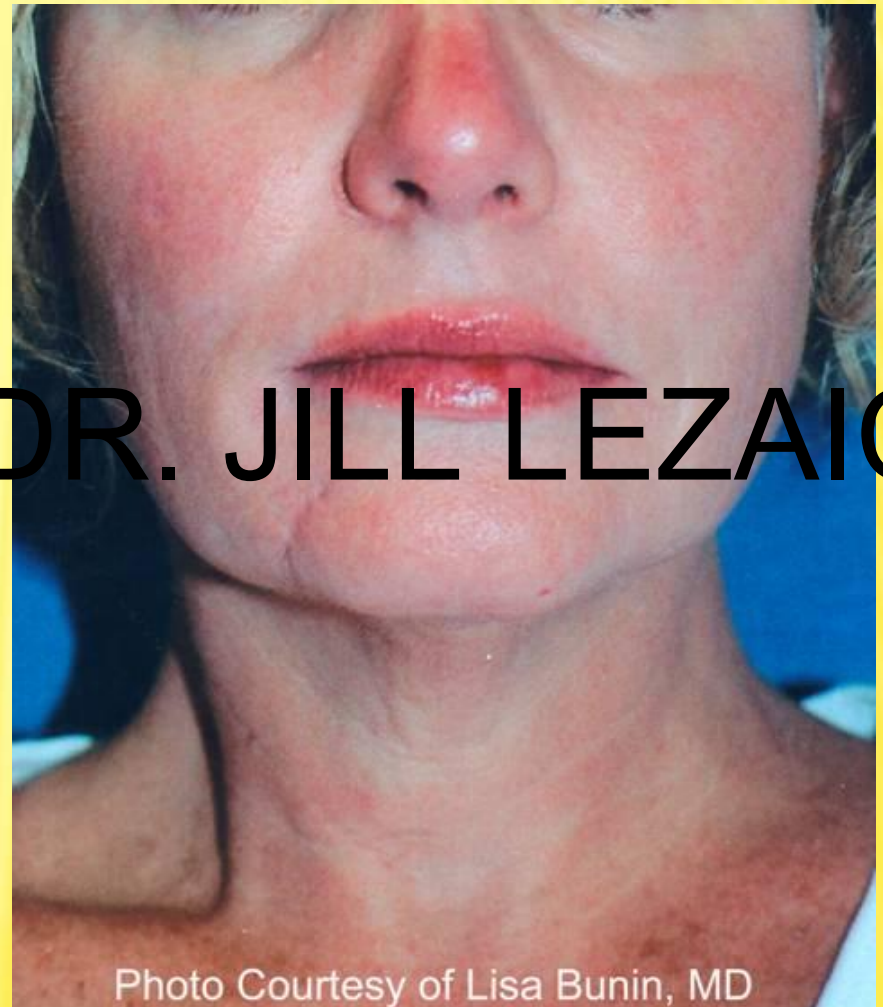

Photo Courtesy of Lisa Bunin, MD

6.5 weeks after 1
treatment

PROPERTY OF DR. JILL LEZAIC

Treatment of Facial Laxity

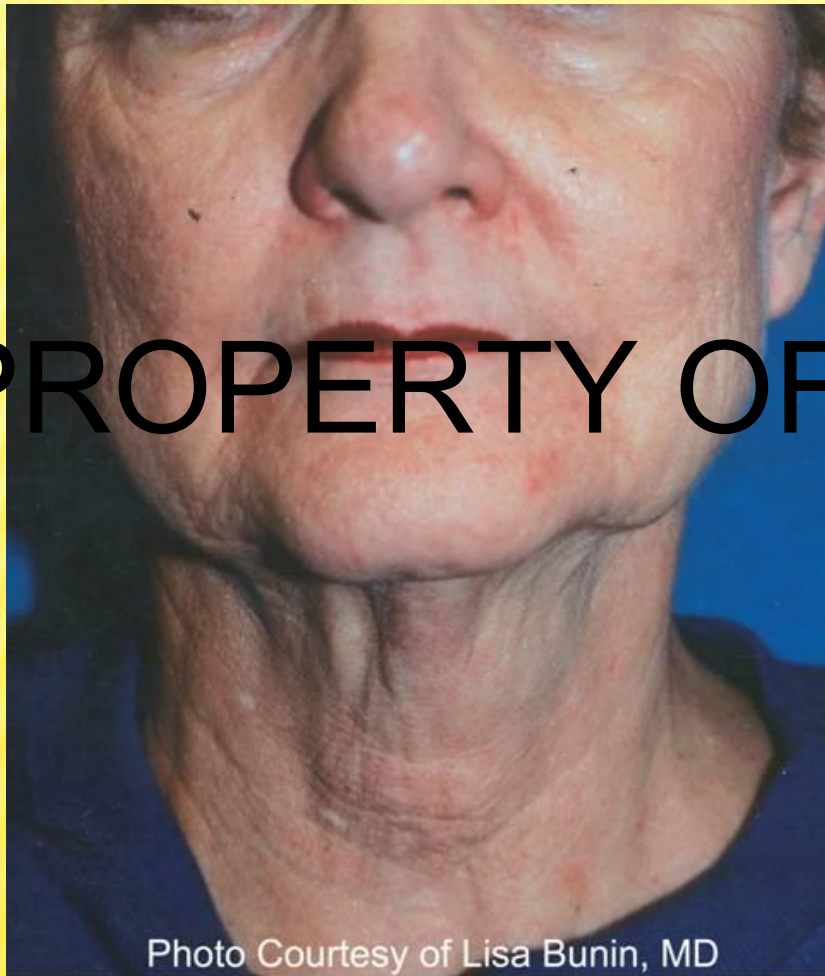

Photo Courtesy of Lisa Bunin, MD

Pre-treatment

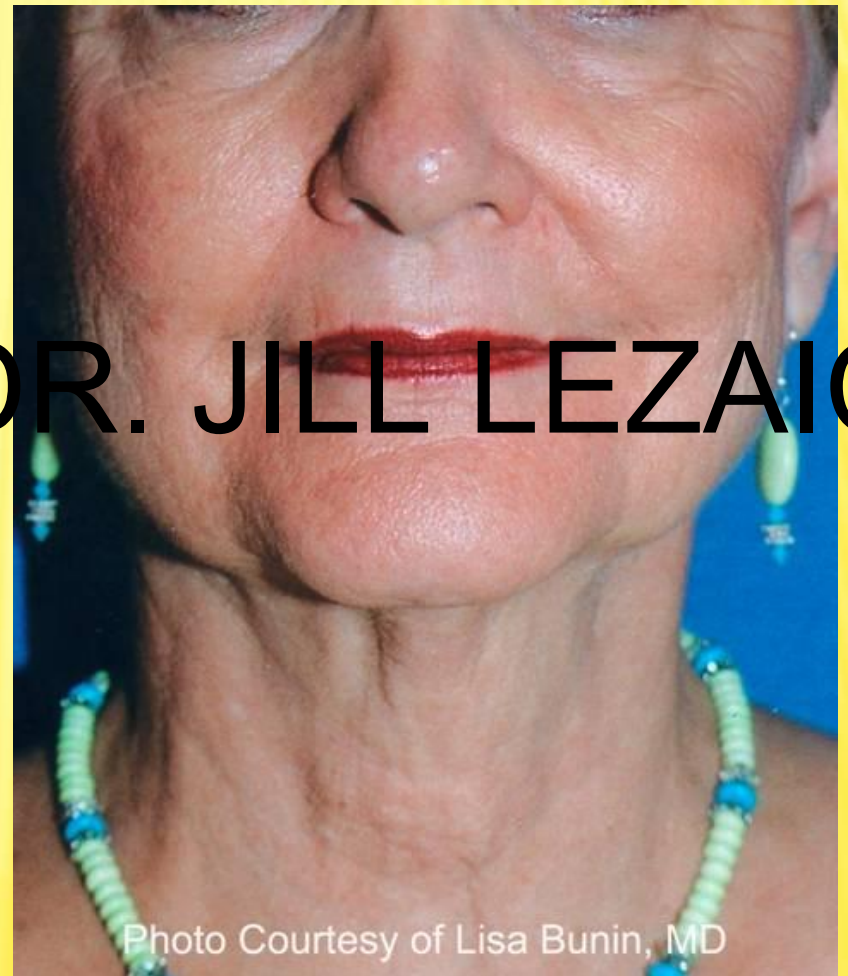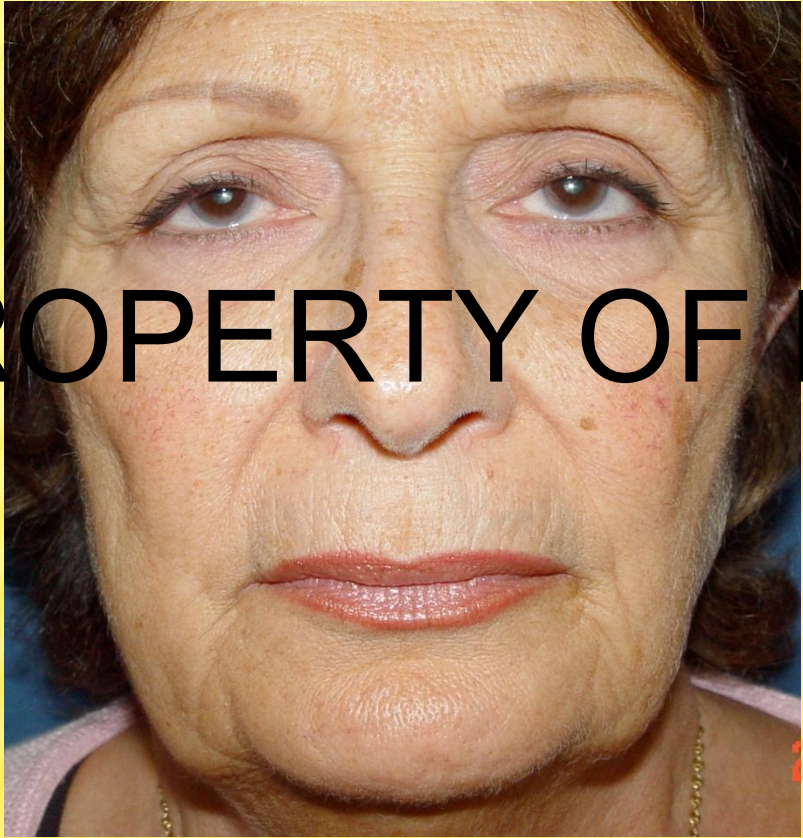


Photo Courtesy of Lisa Bunin, MD

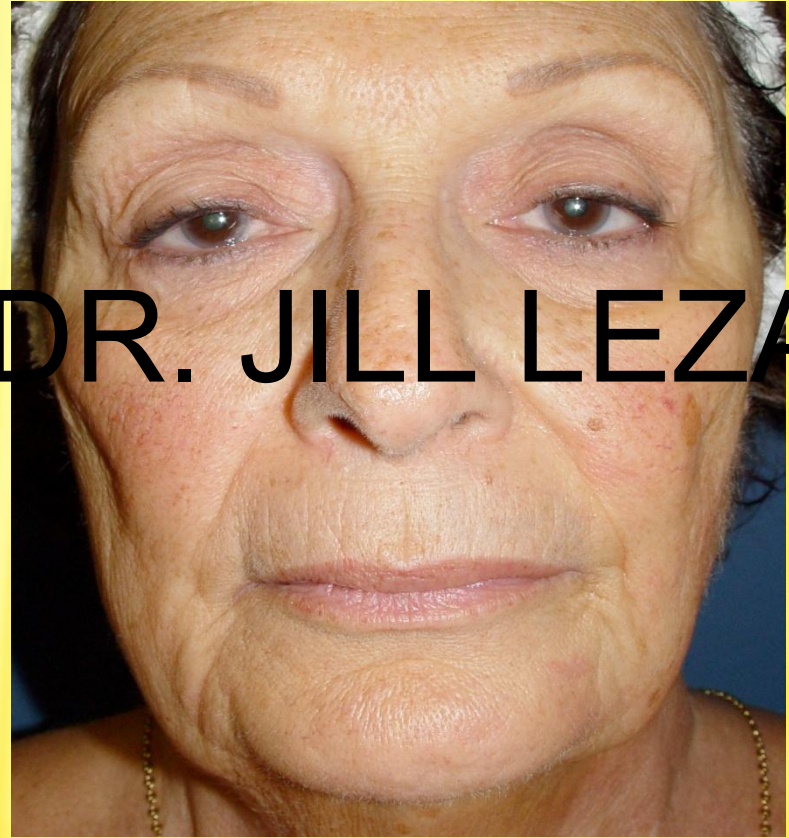
8 weeks after 2 treatment

PROPERTY OF DR. JILL LEZAIC

TREATMENT OF FACIAL LAXITY

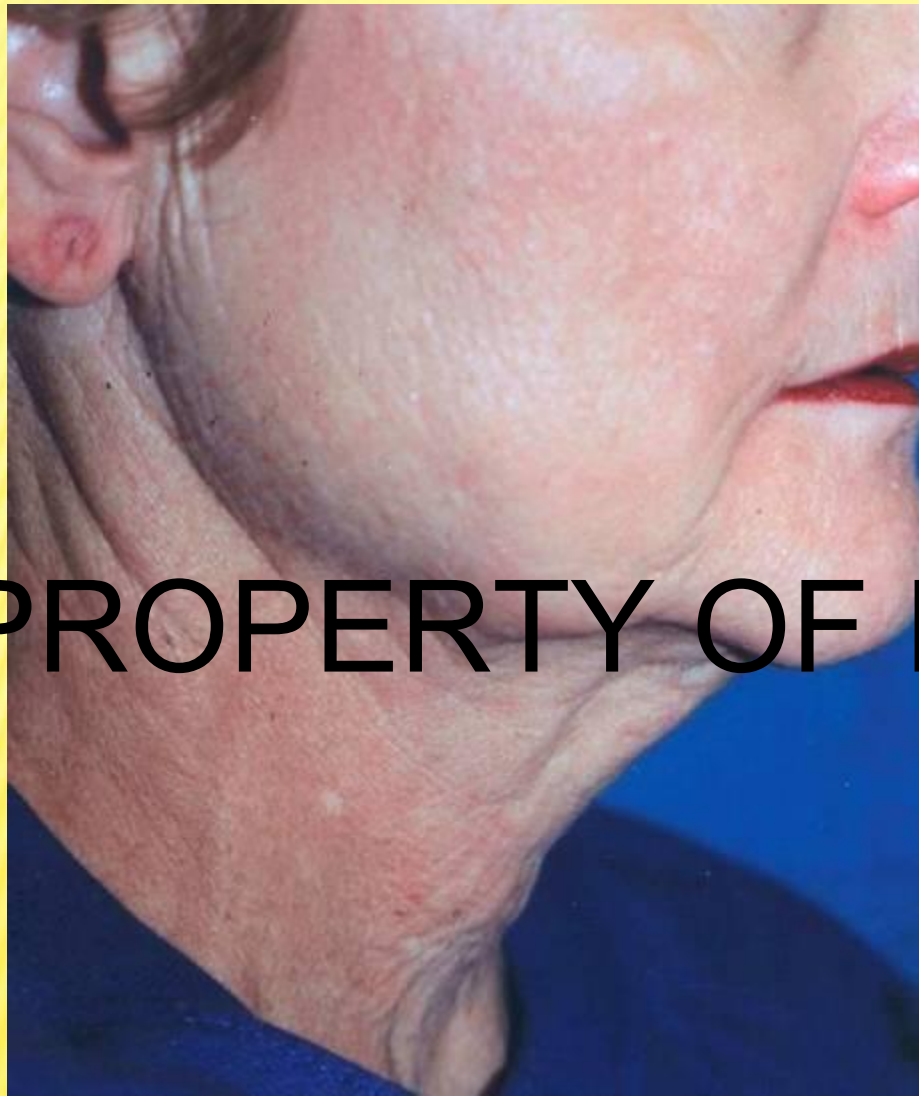

Before

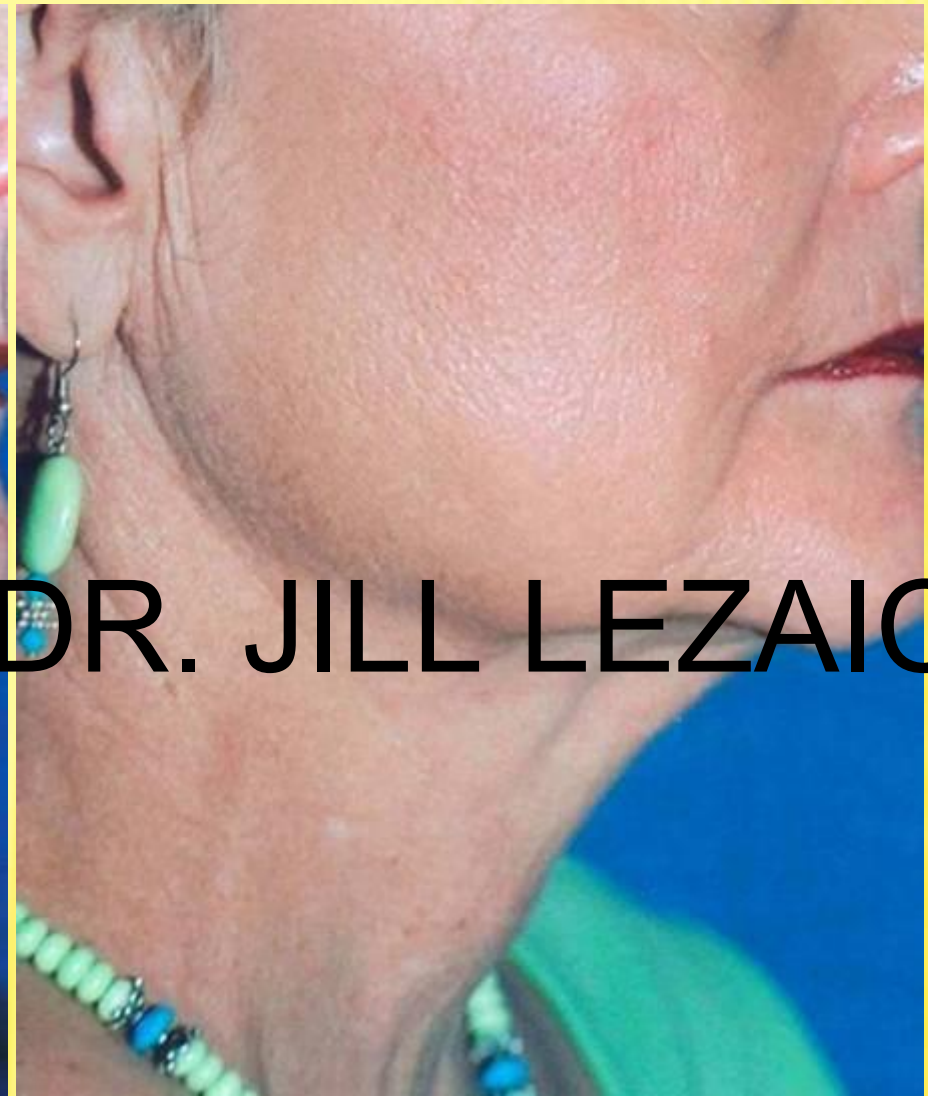

6 weeks after 1 treatment

PROPERTY OF DR. JILL LEZAIC



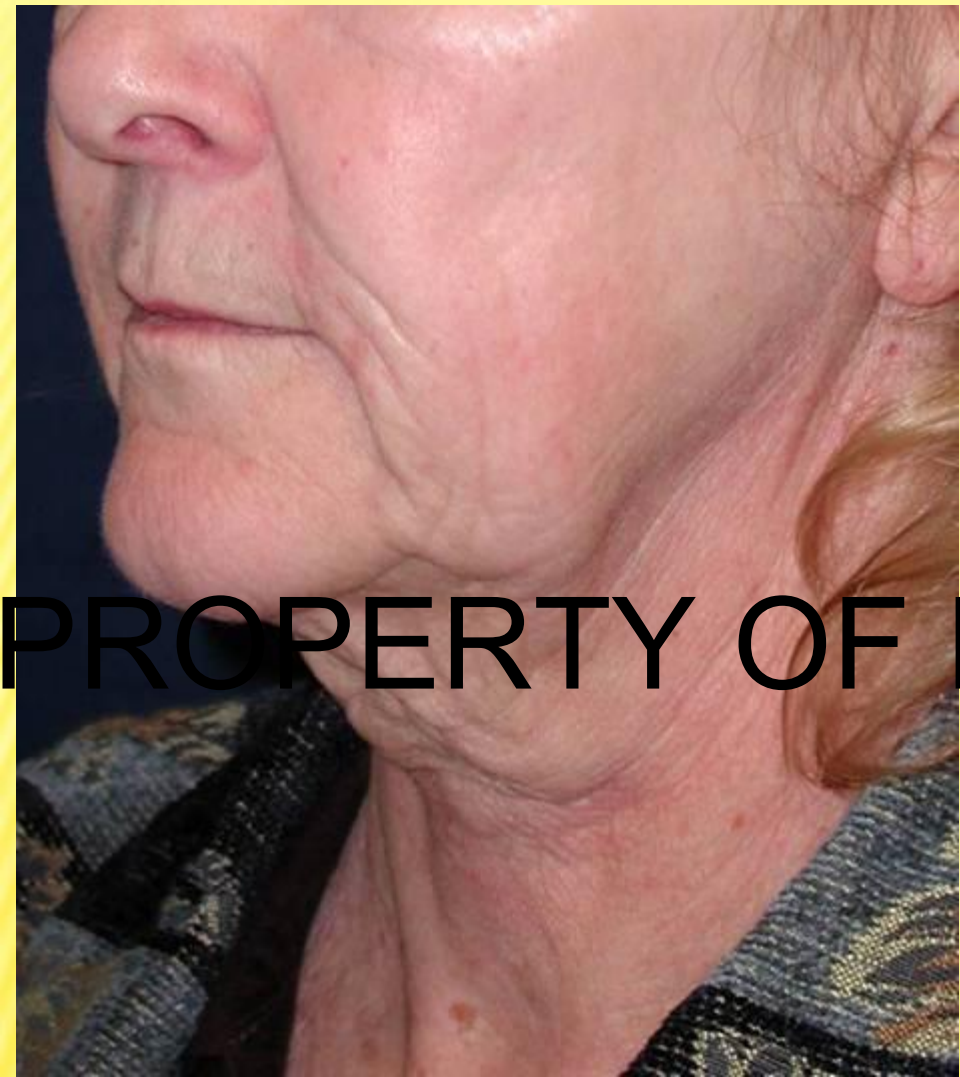Before



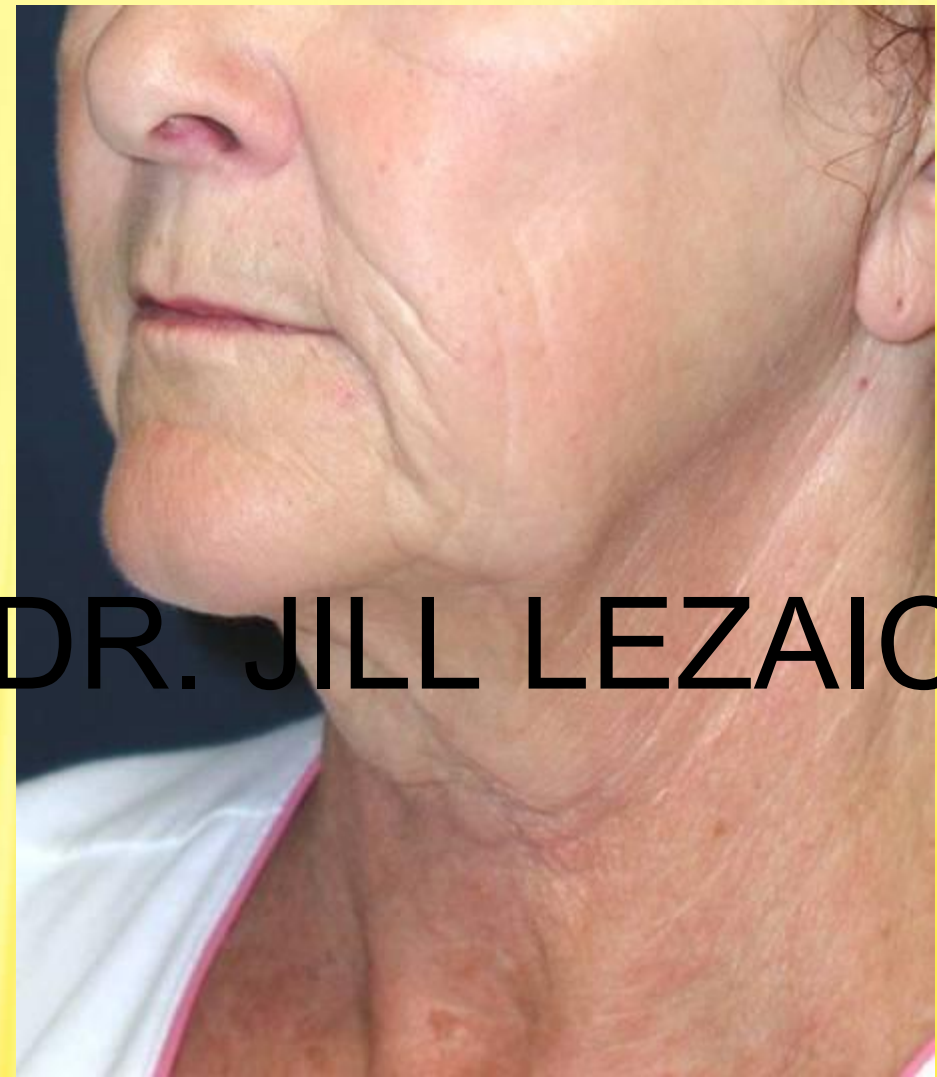2 months after 2nd treatment

PROPERTY OF DR. JILL LEZAIC

Photos Courtesy of Lisa Bunin, M.D.



Before

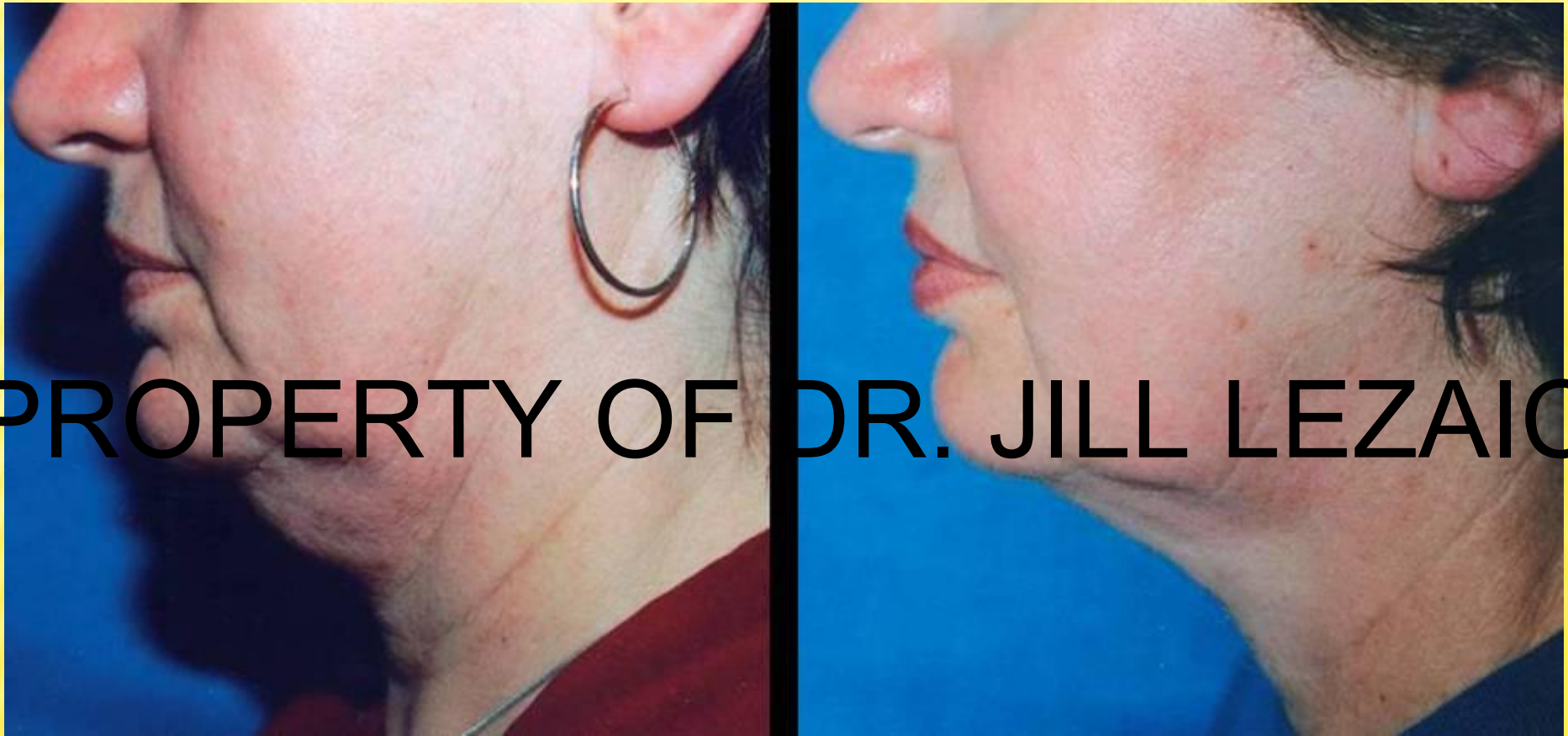


6 months after 1 treatment

PROPERTY OF DR. JILL LEZAIC

Photos Courtesy of Javier Ruiz-Esparza, M.D.

Treatment of Facial Laxity

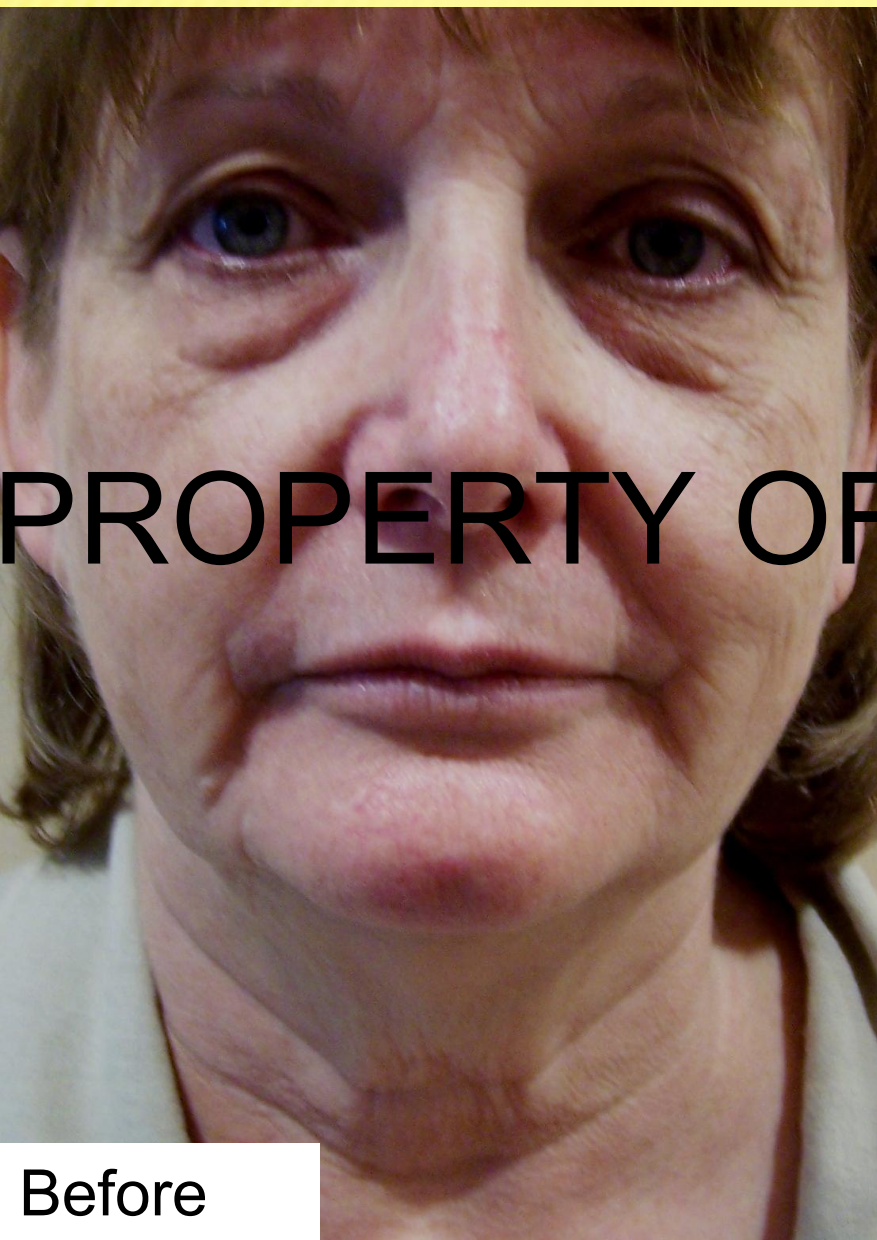

Before

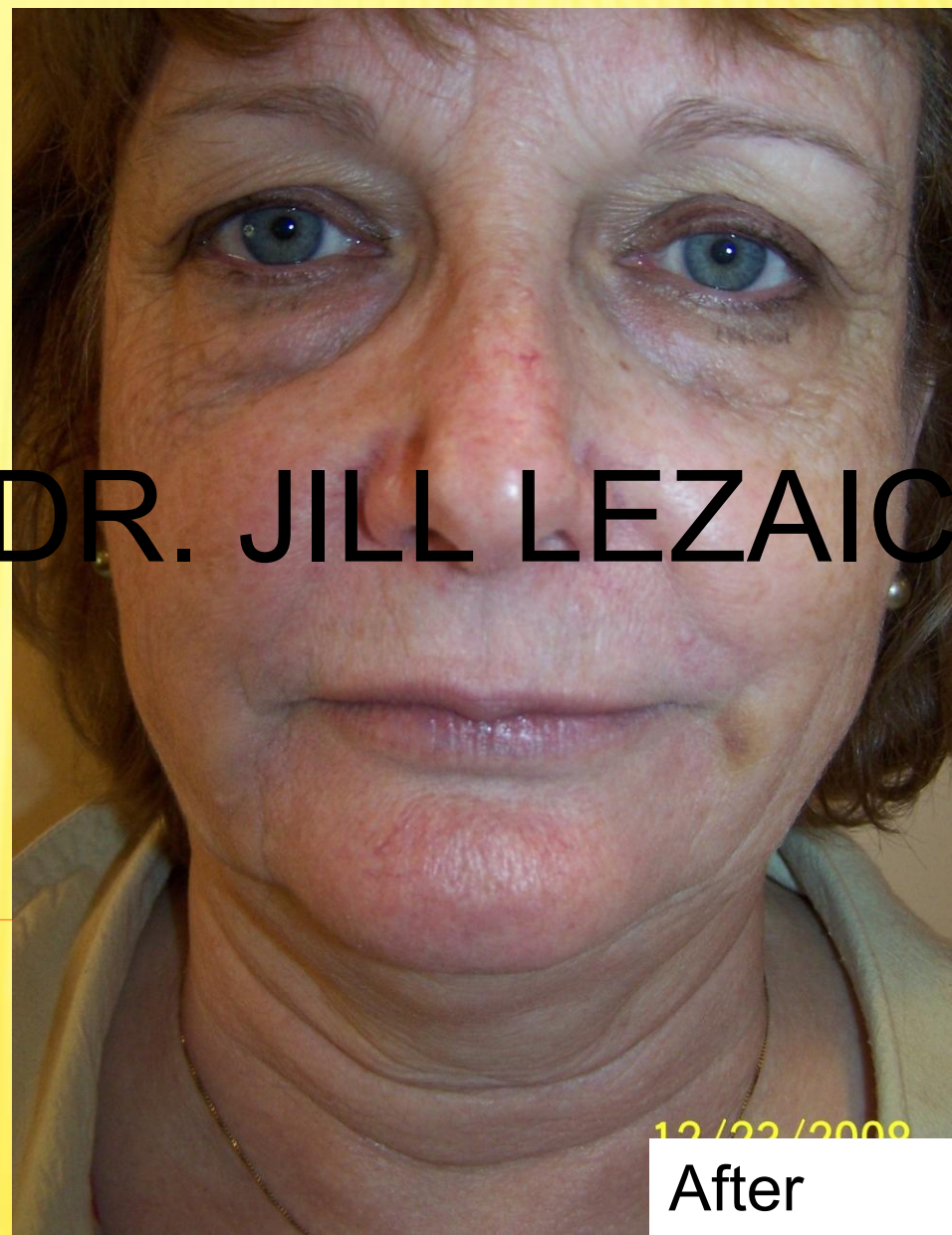12 weeks after 1 treatment

Photos Courtesy of Lisa Bunin, M.D.

4 WEEKS AFTER 2 TITAN NECK TREATMENTS
4 DAYS AFTER RADIESSE: 0.8CC SYRINGE IN EACH SIDE
NLFS & ORAL COMMISSURES



Before

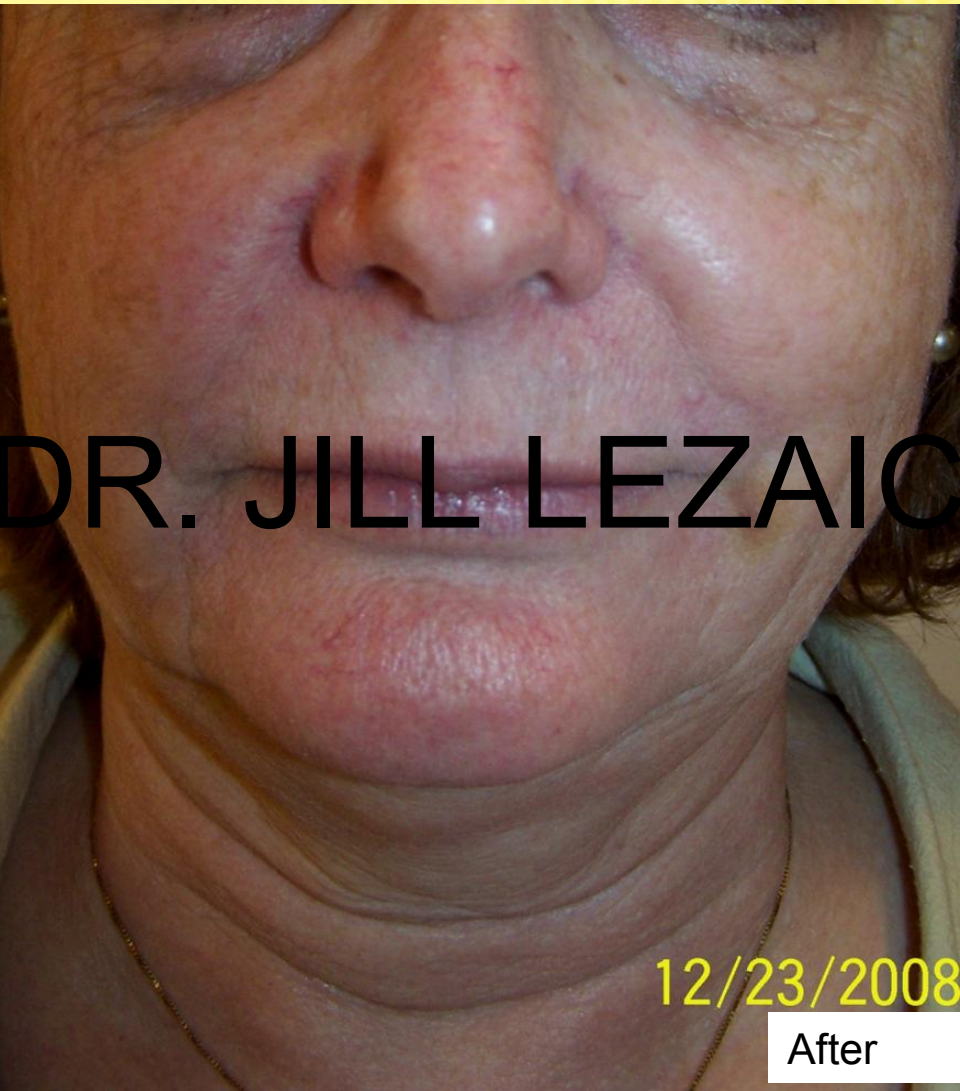
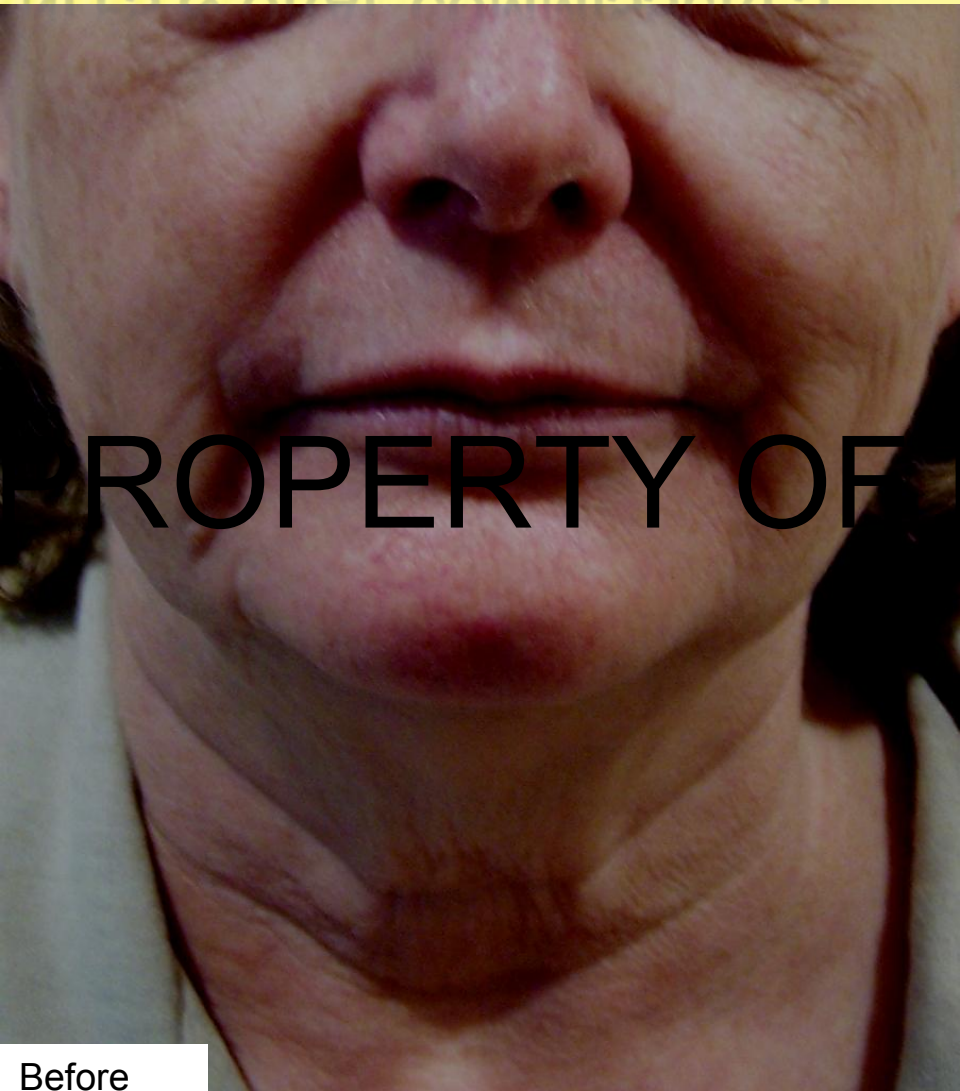
12/22/2009

After

PROPERTY OF DR. JILL LEZAIO

4 WEEKS AFTER 2 TITAN NECK TREATMENTS
4 DAYS AFTER RADIESSE: 0.8CC SYRINGE IN EACH SIDE
NLFS & ORAL COMMISSURES



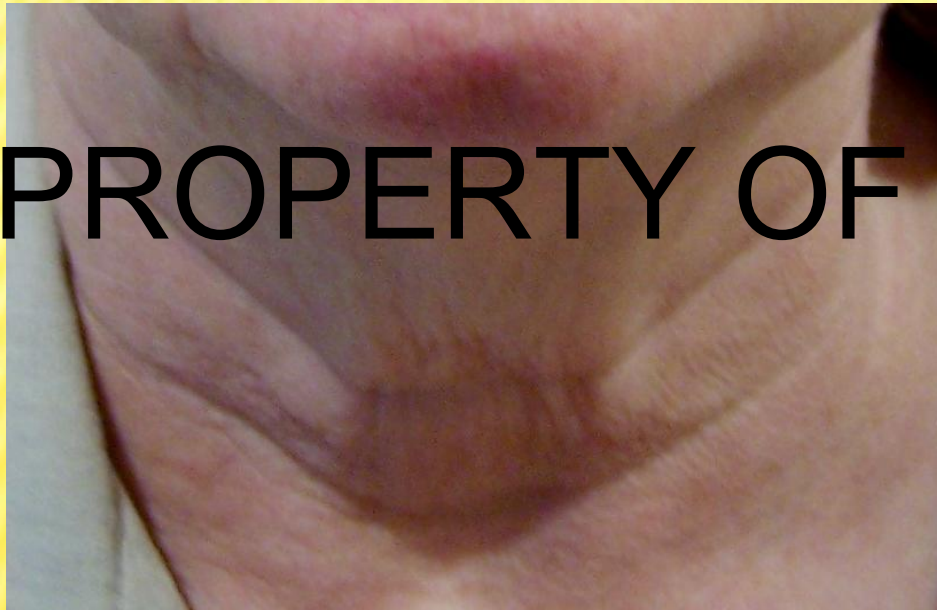
PROPERTY OF DR. JILL LEZAIC

12/23/2008

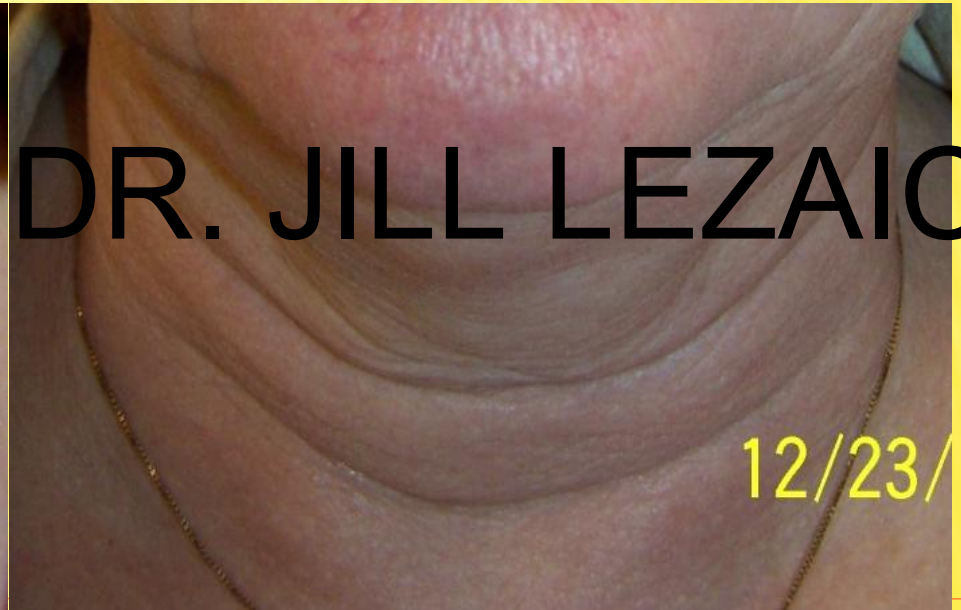
After

Before

4 WEEKS AFTER 2 TITAN NECK TREATMENTS

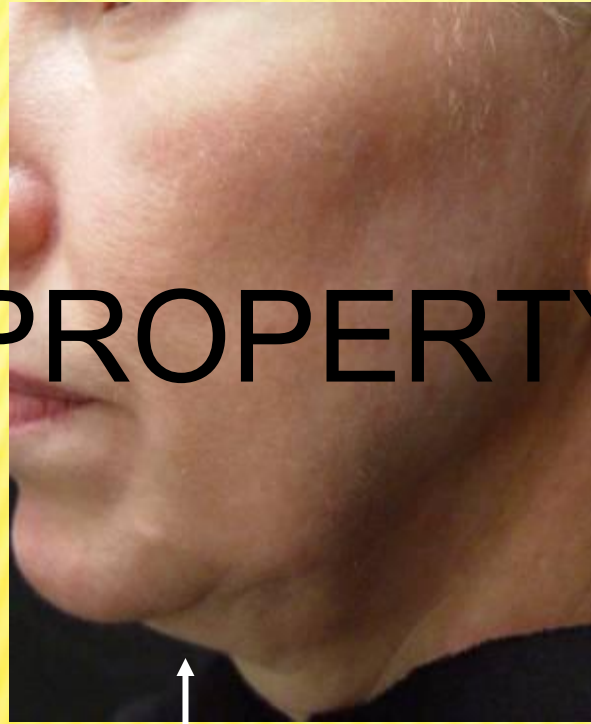

Before

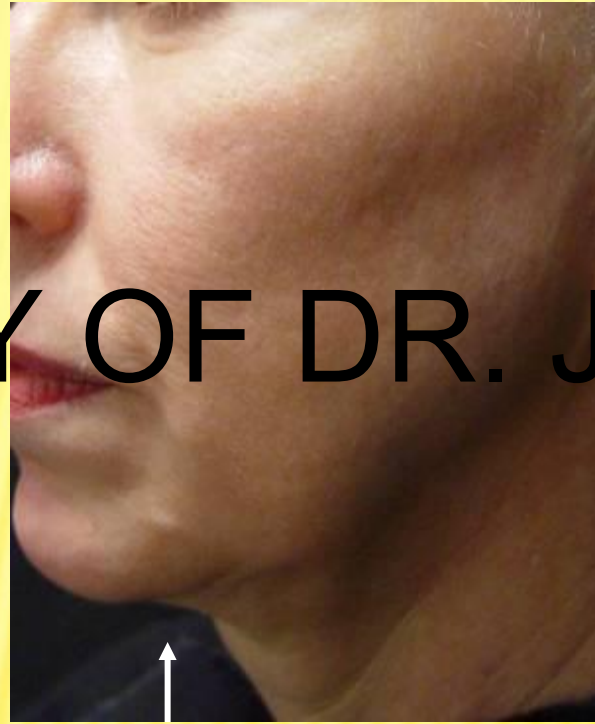

After

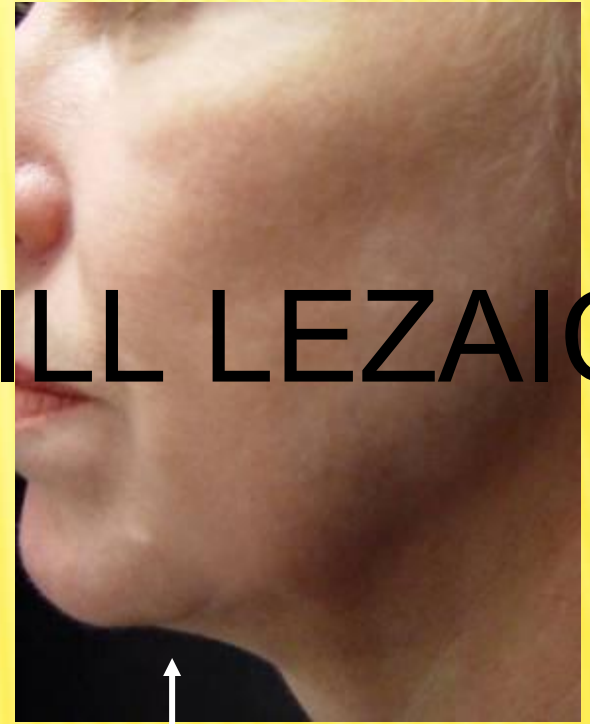TiTan on Cheeks & submental area



Before



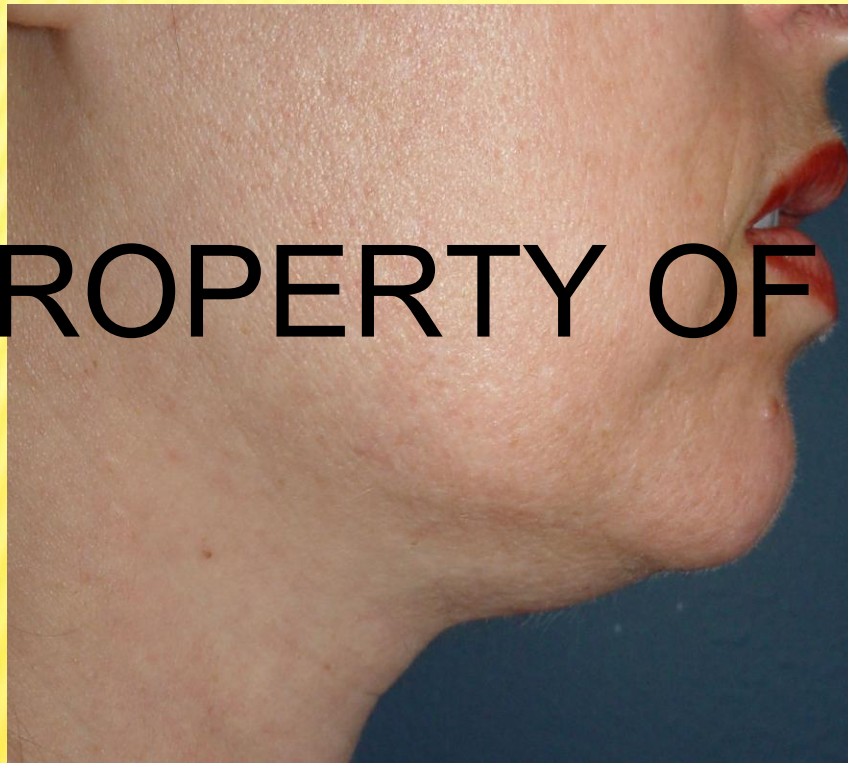**1 month after 2nd
treatment**



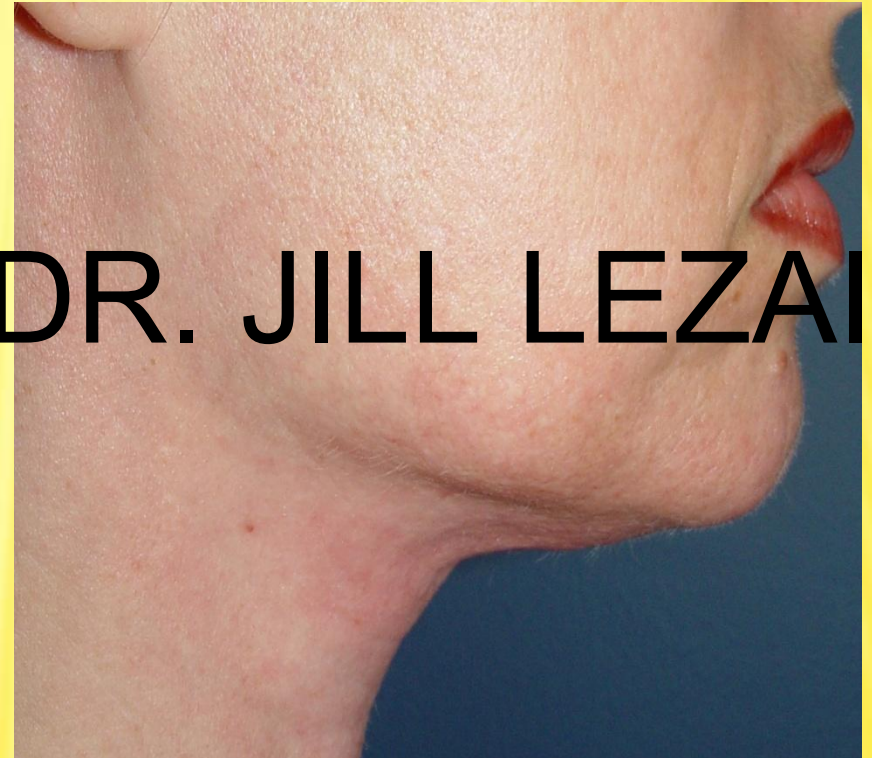**3 months after 2nd
treatment**

PROPERTY OF DR. JILL LEZAIC

TREATMENT OF SUBMENTAL LAXITY



Before



Immediately After 1st Treatment

PROPERTY OF DR. JILL LEZAIC

EYELIDS

Before

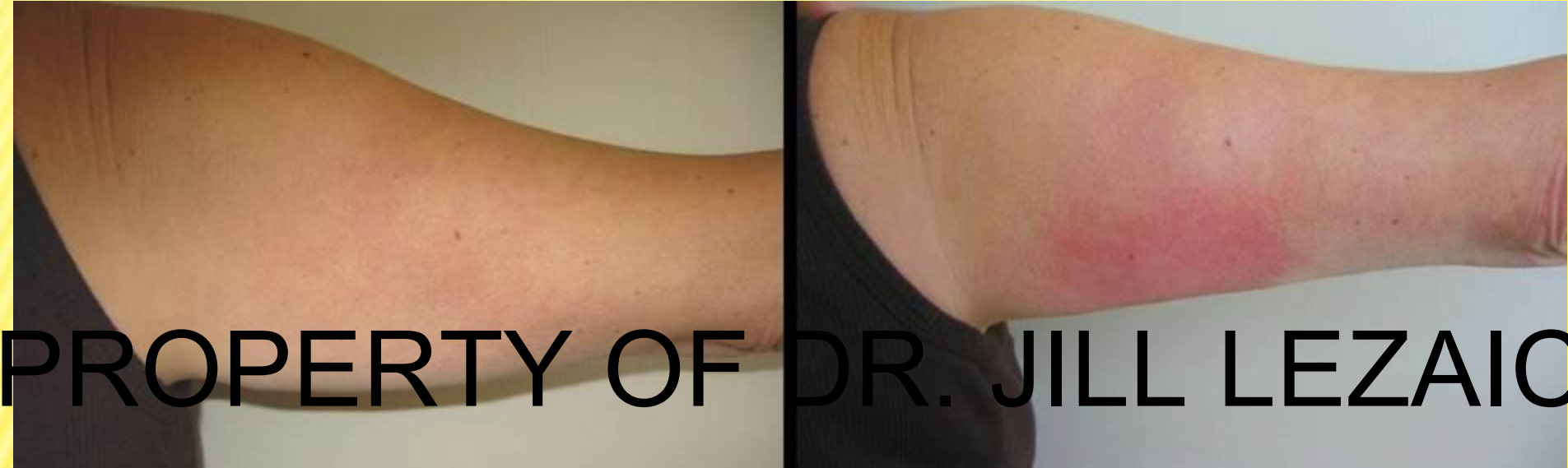

PROPERTY OF DR. JILL LEZAIC

2 weeks after 5th treatment

Photos Courtesy of John Hunts, M.D.

UPPER ARM



Before

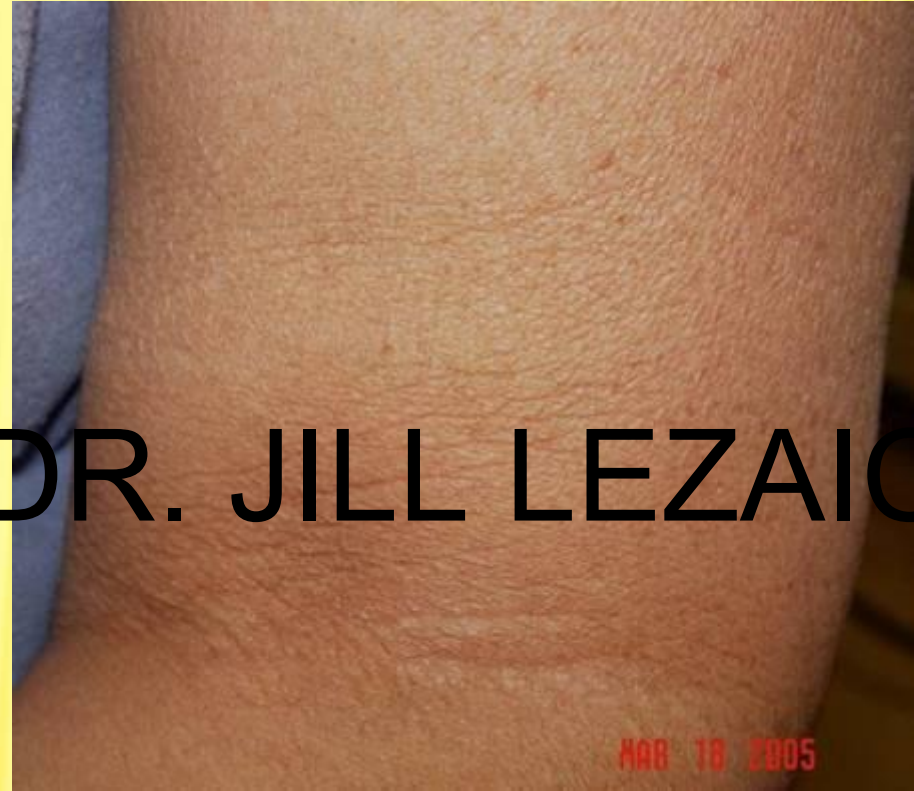Immediately after 1st treatment

Photos Courtesy of Edmond Zingaro, M.D.

ARM



Before



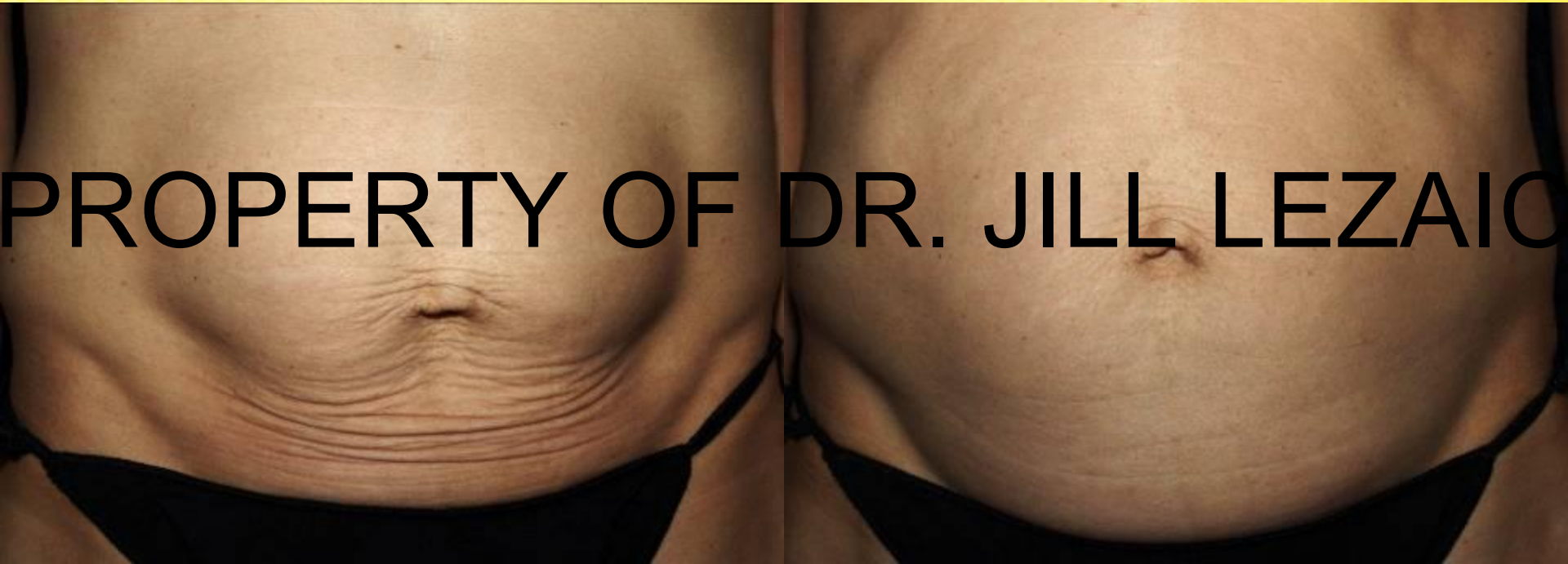Immediately after 1 treatment

PROPERTY OF DR. JILL LEZAIC

TITAN ABDOMEN

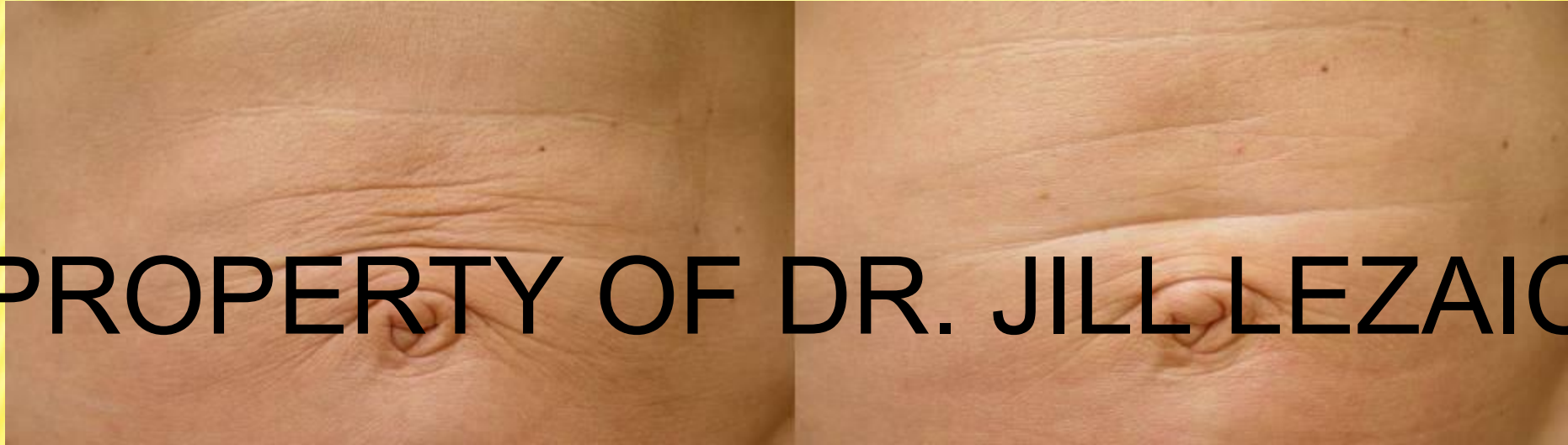Before

6 Months After 2nd Treatment



PROPERTY OF DR. JILL LEZAIO

TREATMENT OF ABDOMINAL LAXITY



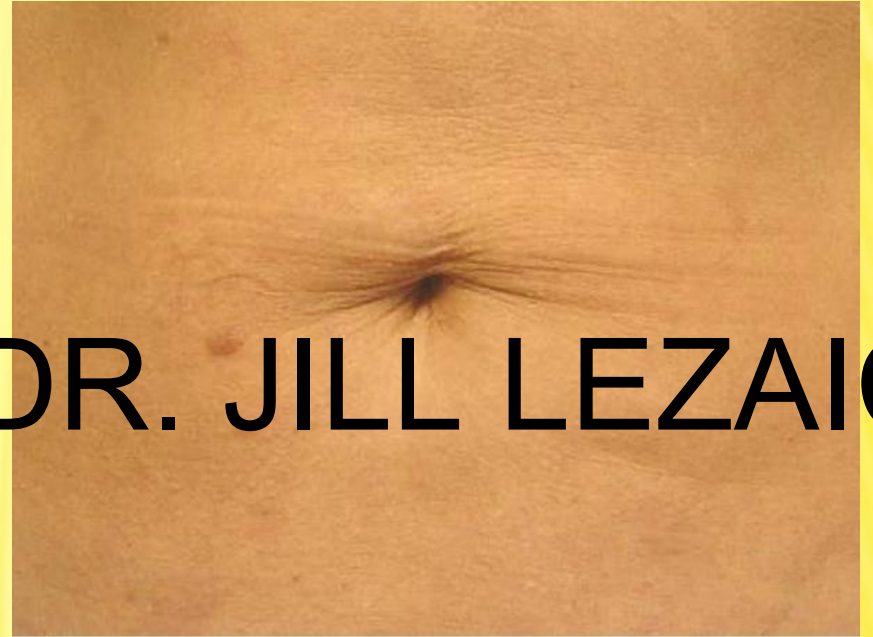
Before

4 weeks after 2
treatments

Treatment of Abdominals



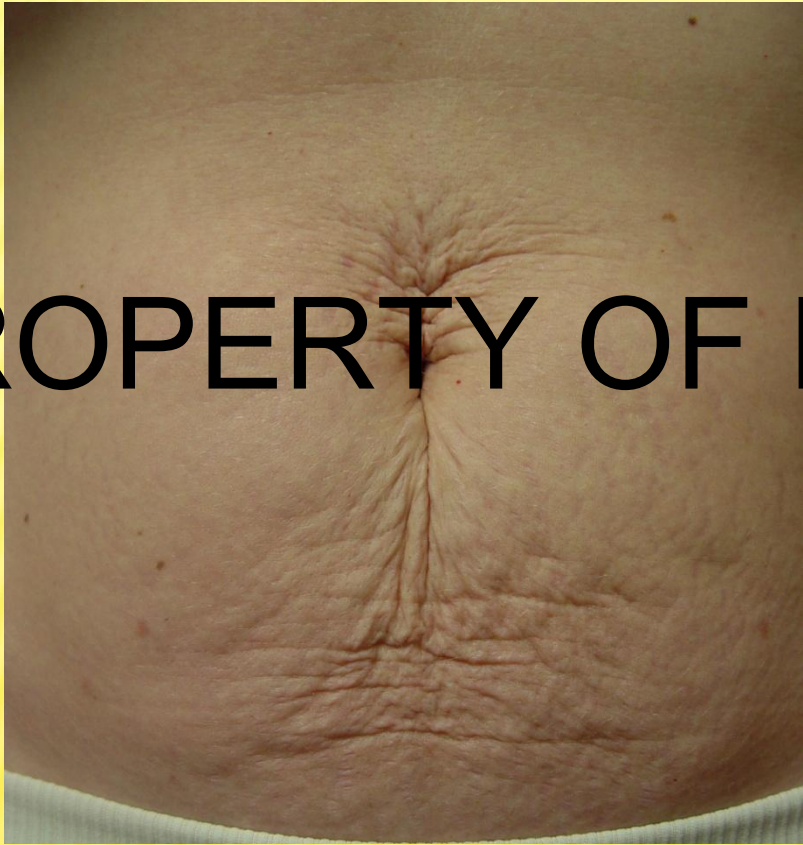
Before



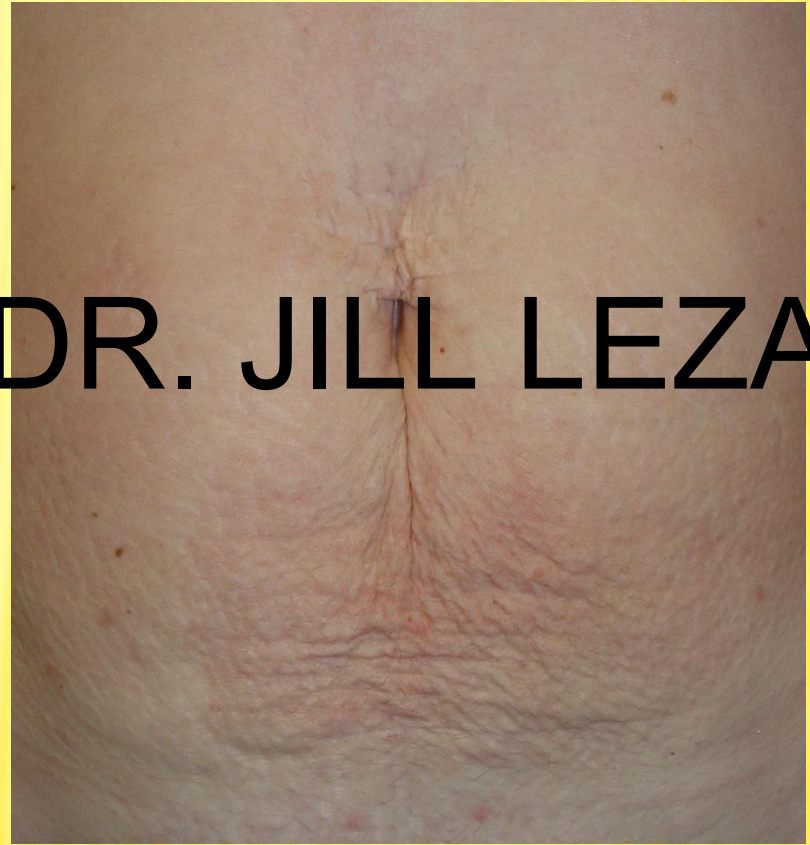After

PROPERTY OF DR. JILL LEZAIC

TREATMENT OF ABDOMINAL LAXITY



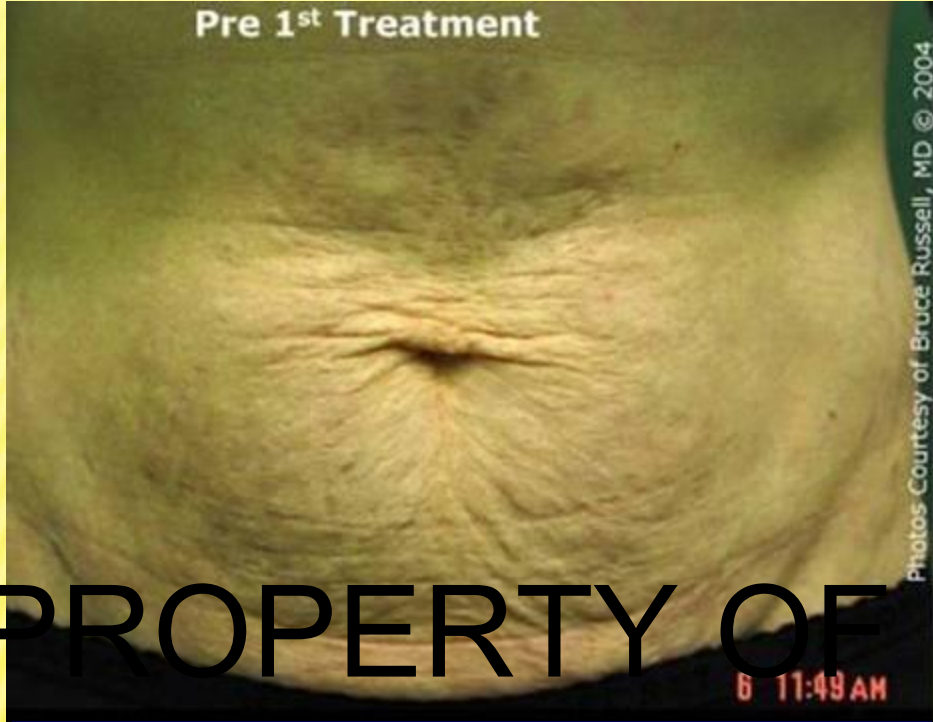Before



6 weeks after 1 Treatment

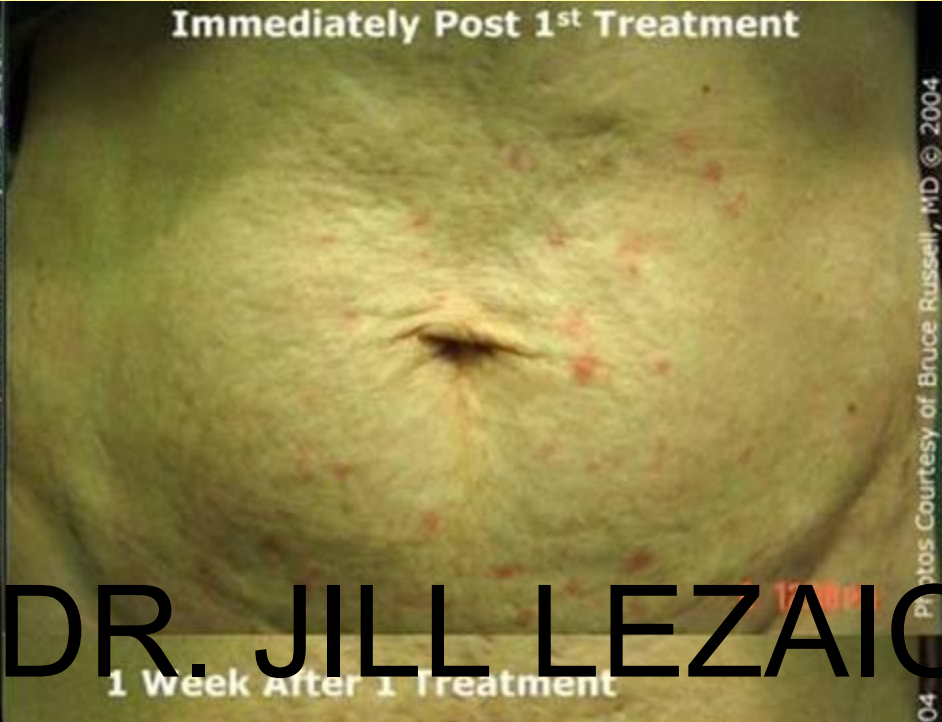PROPERTY OF DR. JILL LEZAIC

Pre 1st Treatment



Photos Courtesy of Bruce Russell, MD © 2004

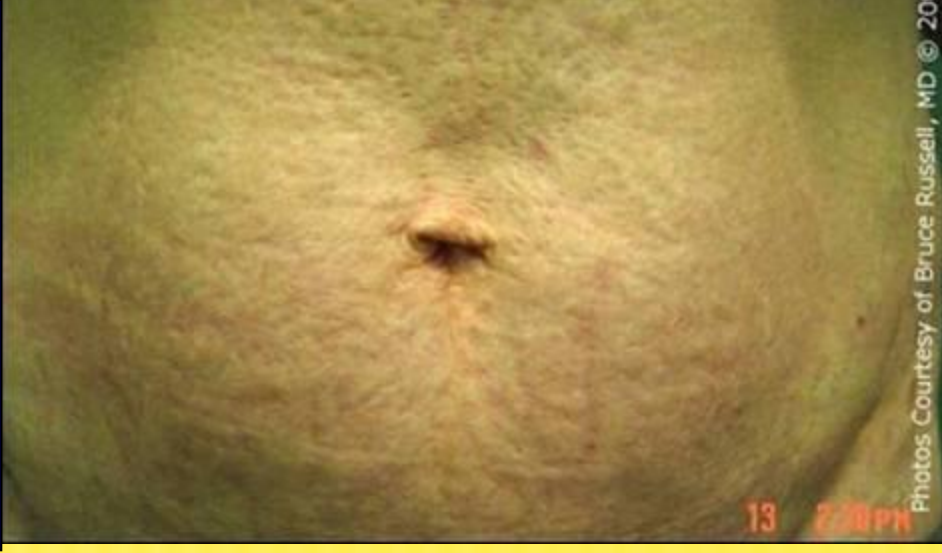
Immediately Post 1st Treatment



Photos Courtesy of Bruce Russell, MD © 2004

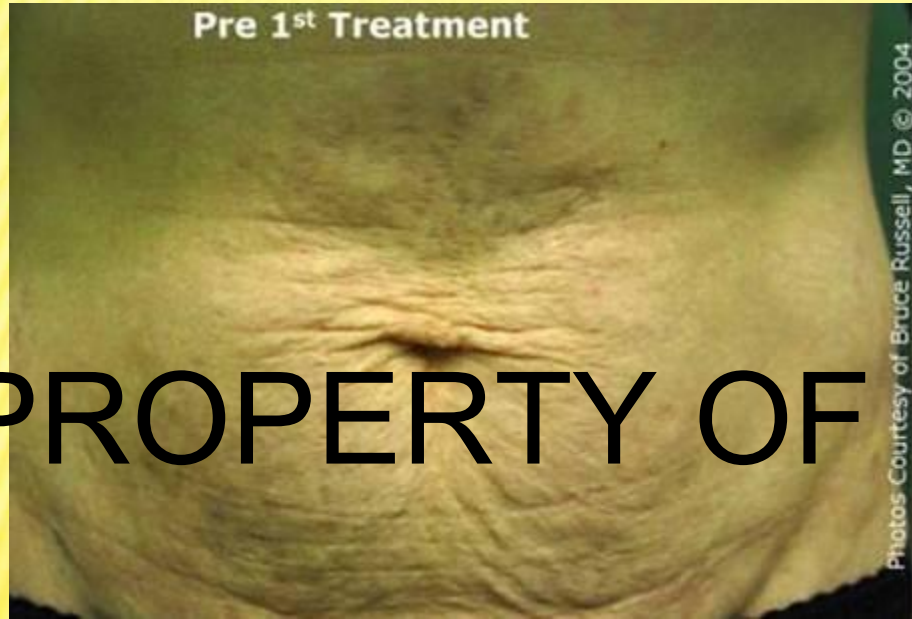PROPERTY OF DR. JILL LEZAIC

1 Week After 1 Treatment

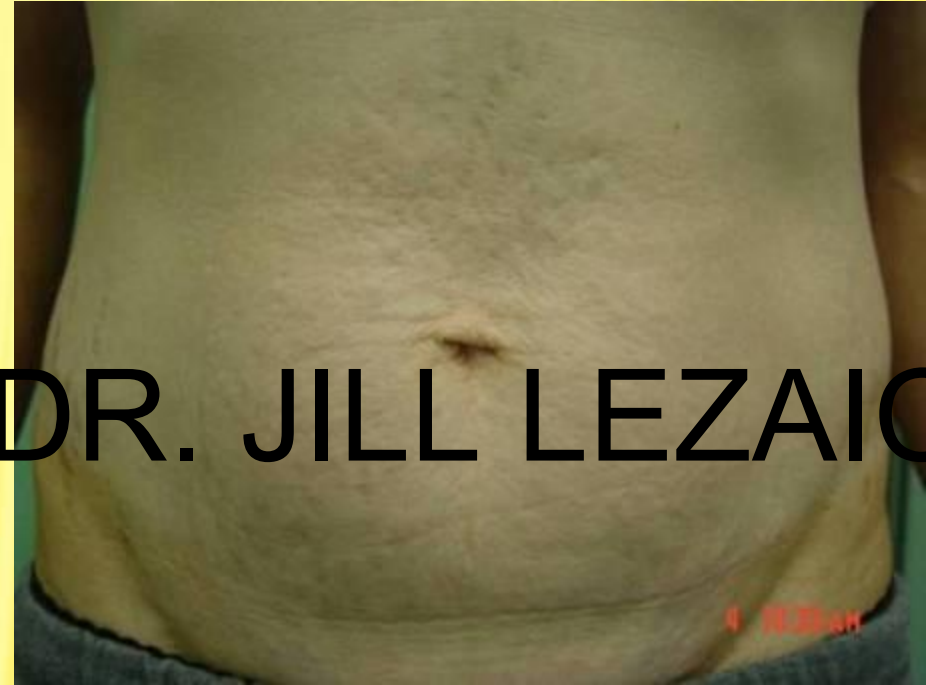

Photos Courtesy of Bruce Russell, MD © 2004

TREATMENT OF ABDOMINAL LAXITY



Before

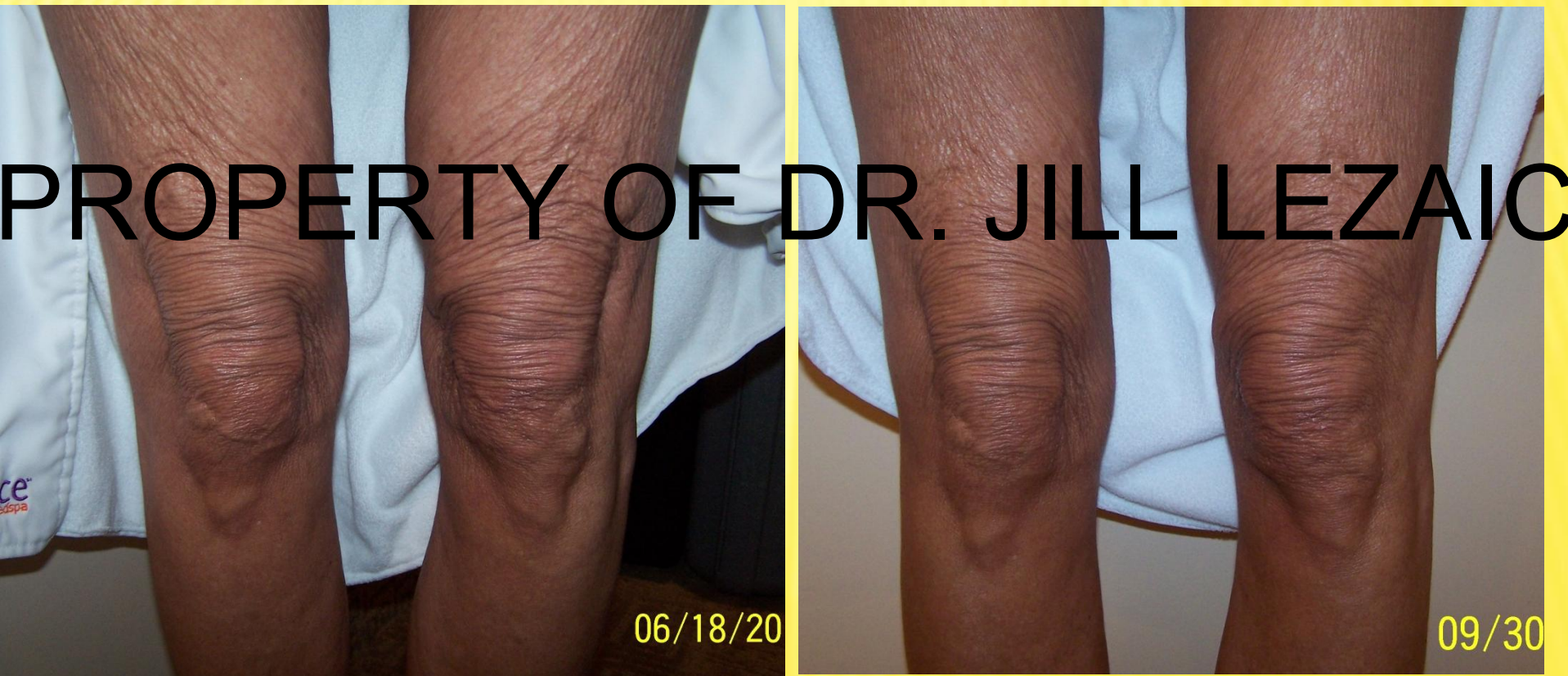

1 year after 3 treatments

PROPERTY OF DR. JILL LEZAIC

TITAN

BEFORE & AFTER 3 TREATMENTS



PROPERTY OF DR. JILL LEZAIC

PEARL LASER

PEARL LASER

✘ Before



✘ 4 weeks after 1 treatment

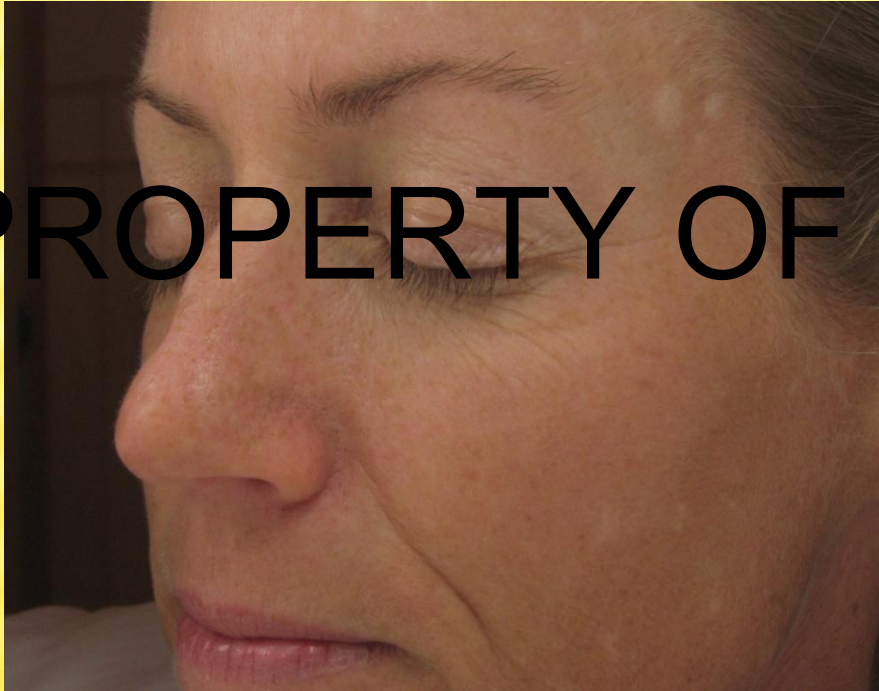

PROPERTY OF DR. JILL LEZAIC

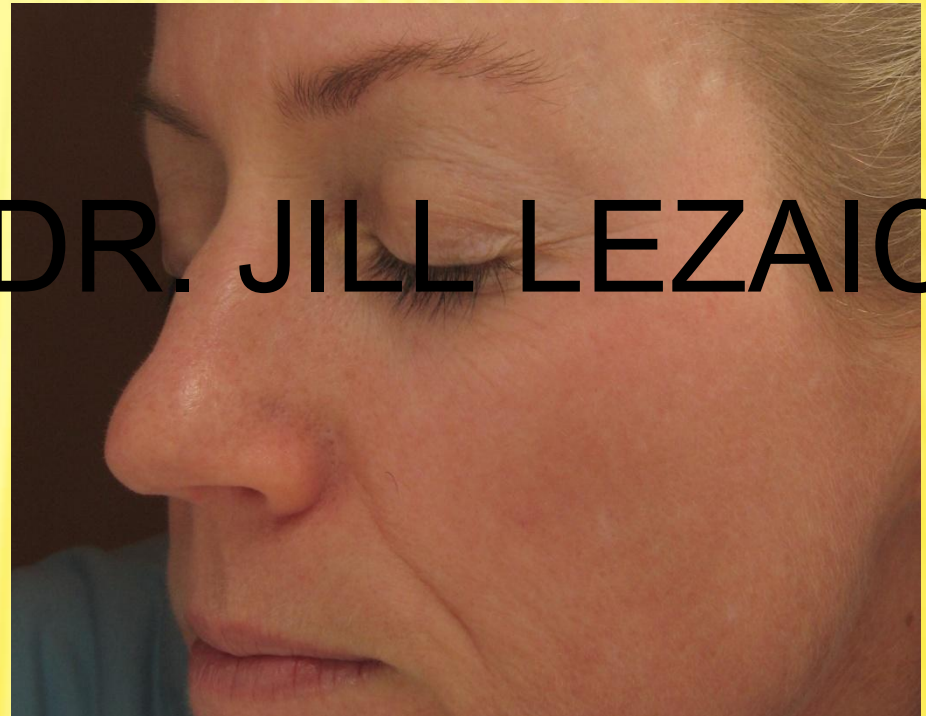PEARL LASER

PEARL LASER

✘ Before

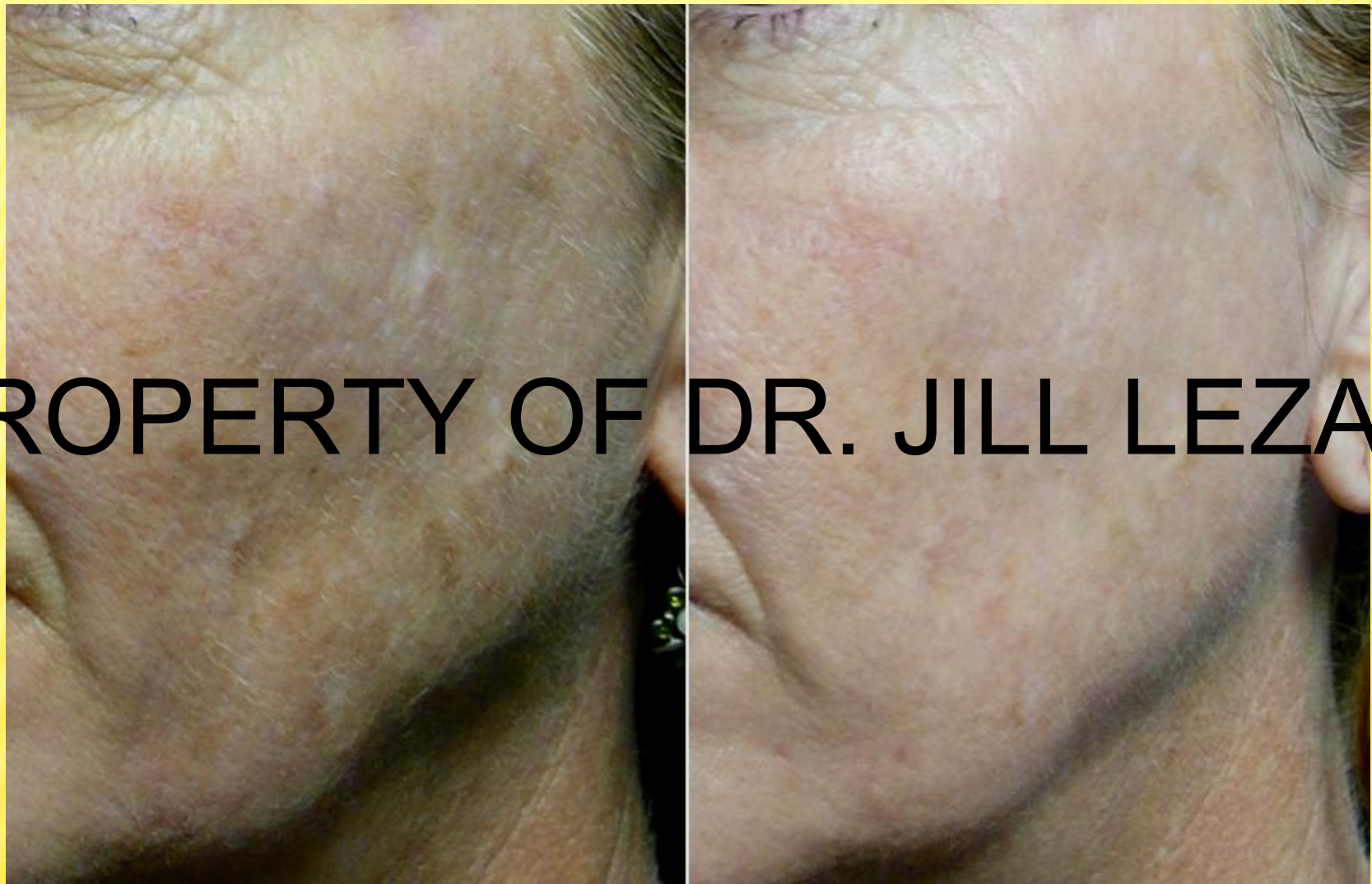

✘ After



PROPERTY OF DR. JILL LEZAIC

48 YEAR OLD FEMALE, SKIN TYPE II

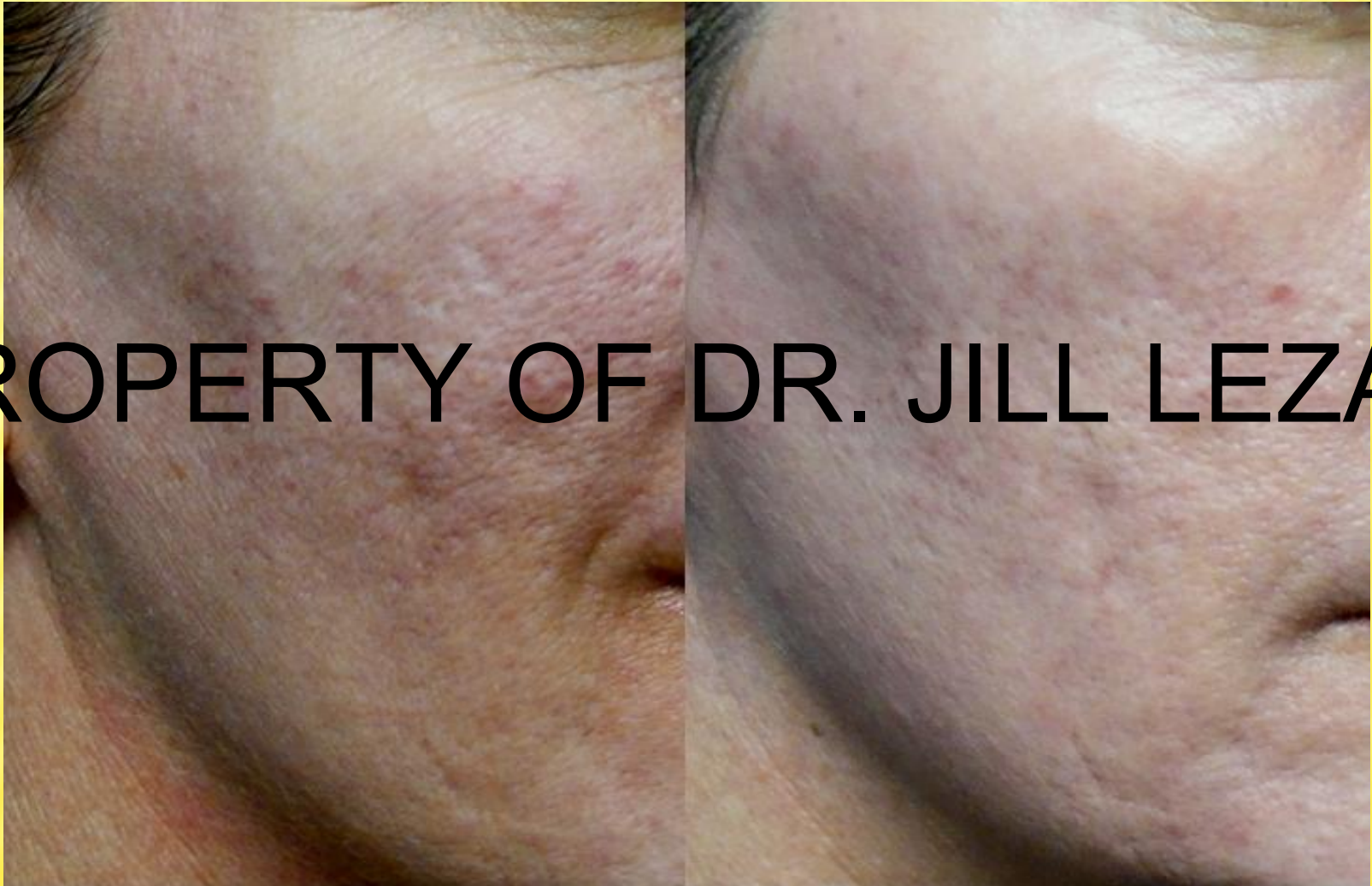

Before

14 days after 2nd treatment

Photos Courtesy of Jill Lezaic, DO

47 YEAR OLD FEMALE, SKIN TYPE II



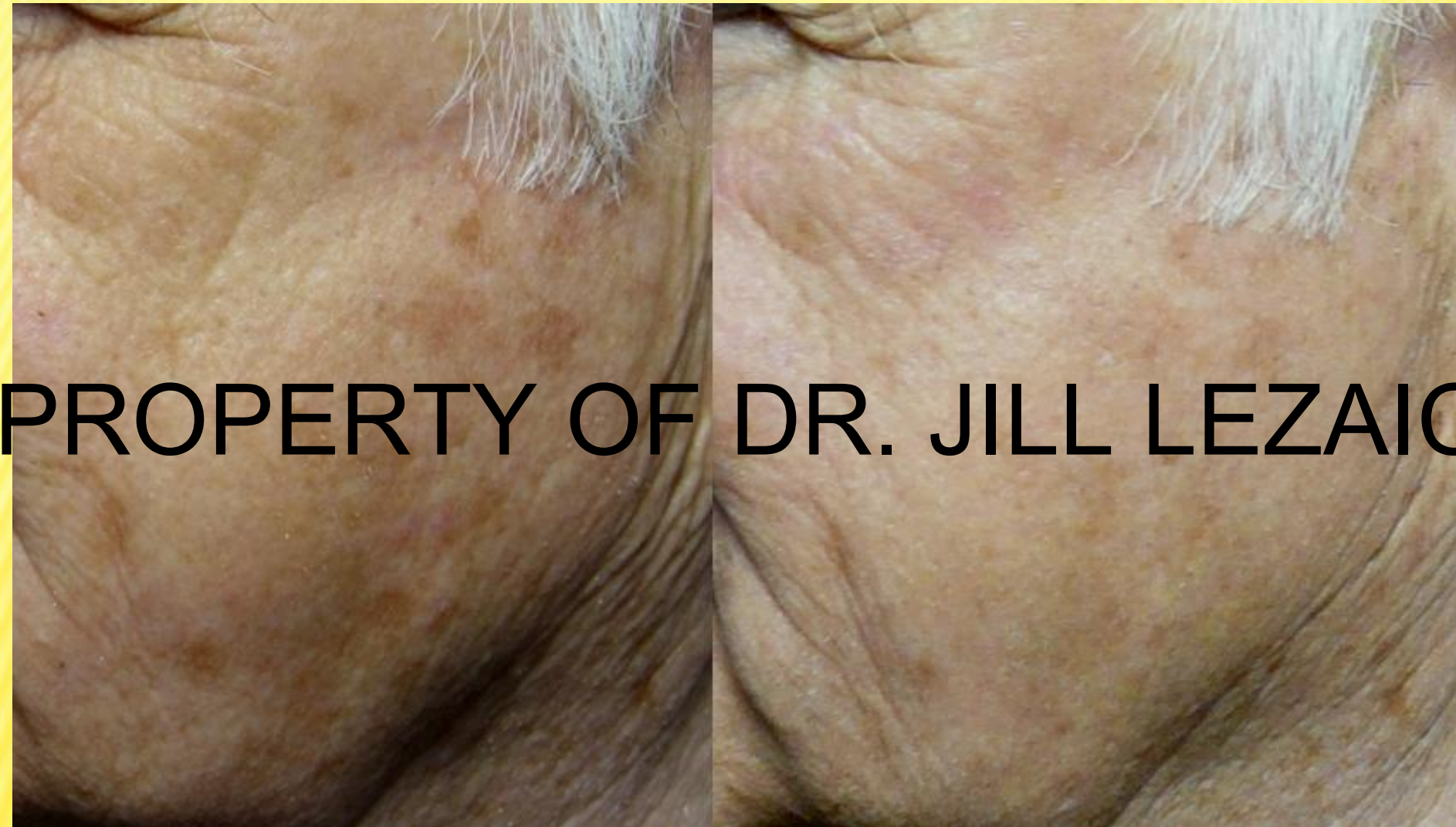PROPERTY OF DR. JILL LEZAIC

Before

4 weeks after 2nd treatment

Photos Courtesy of Jill Lezaic, DO

76 YEAR OLD, SKIN TYPE III



PROPERTY OF DR. JILL LEZAIC

Before

4 weeks after 2nd treatment

Photos Courtesy of Jill Lezaic, DO

Before

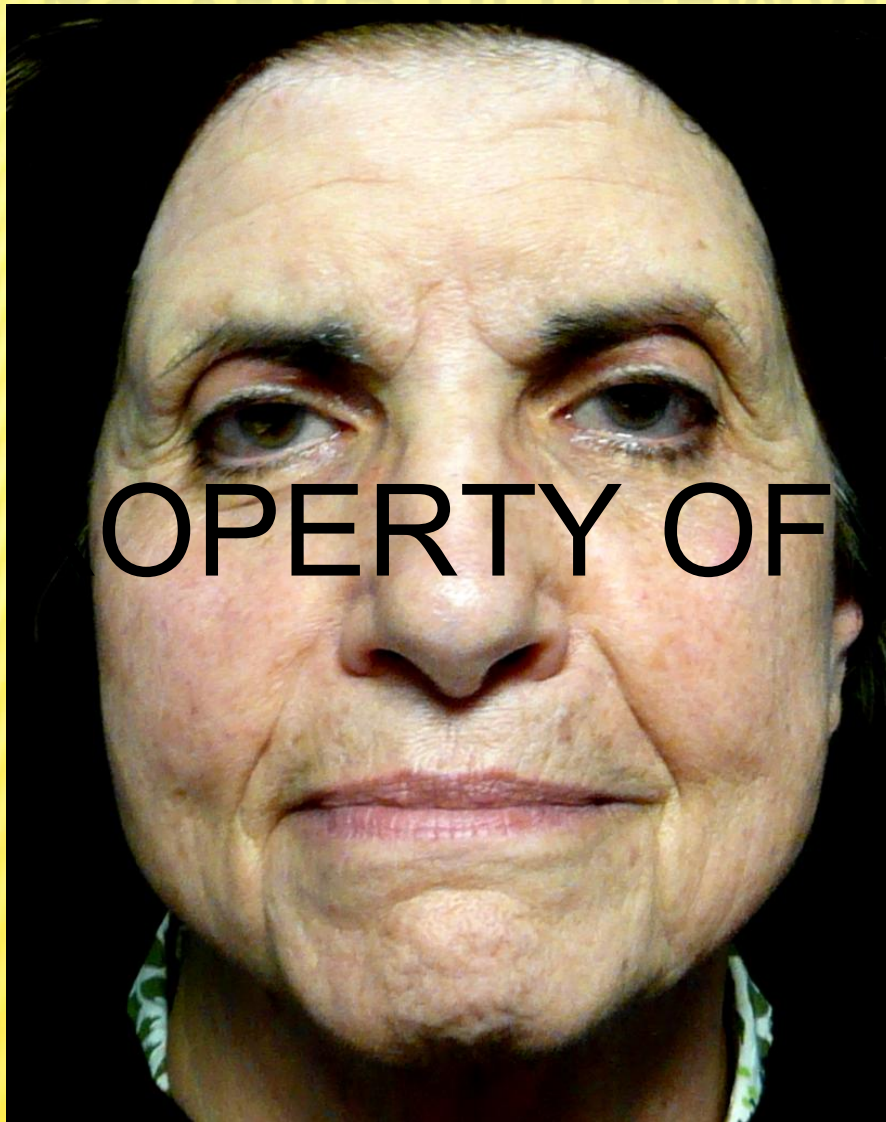
4 weeks after 1 treatment

PROPERTY OF DR. JILL LEZA

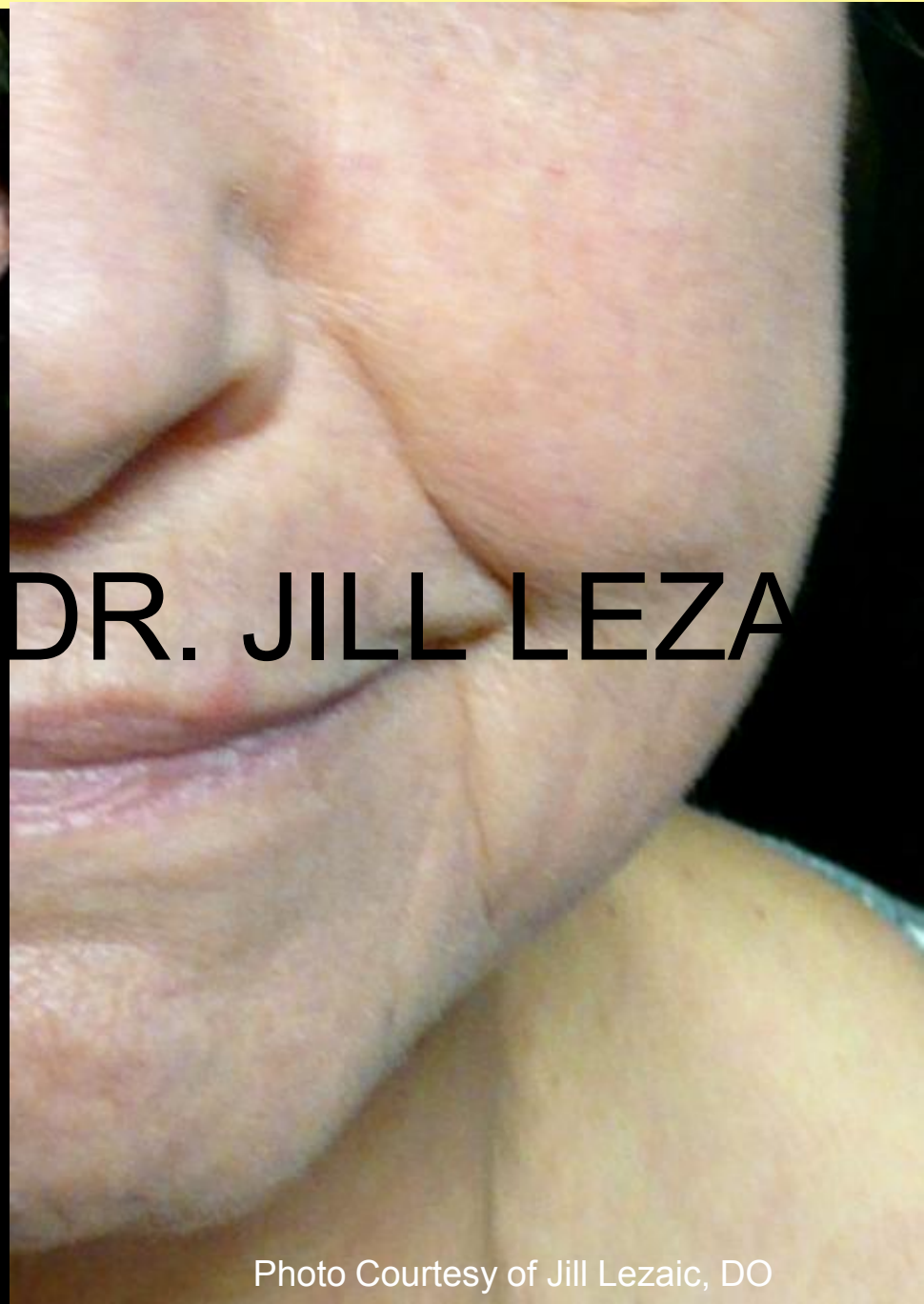
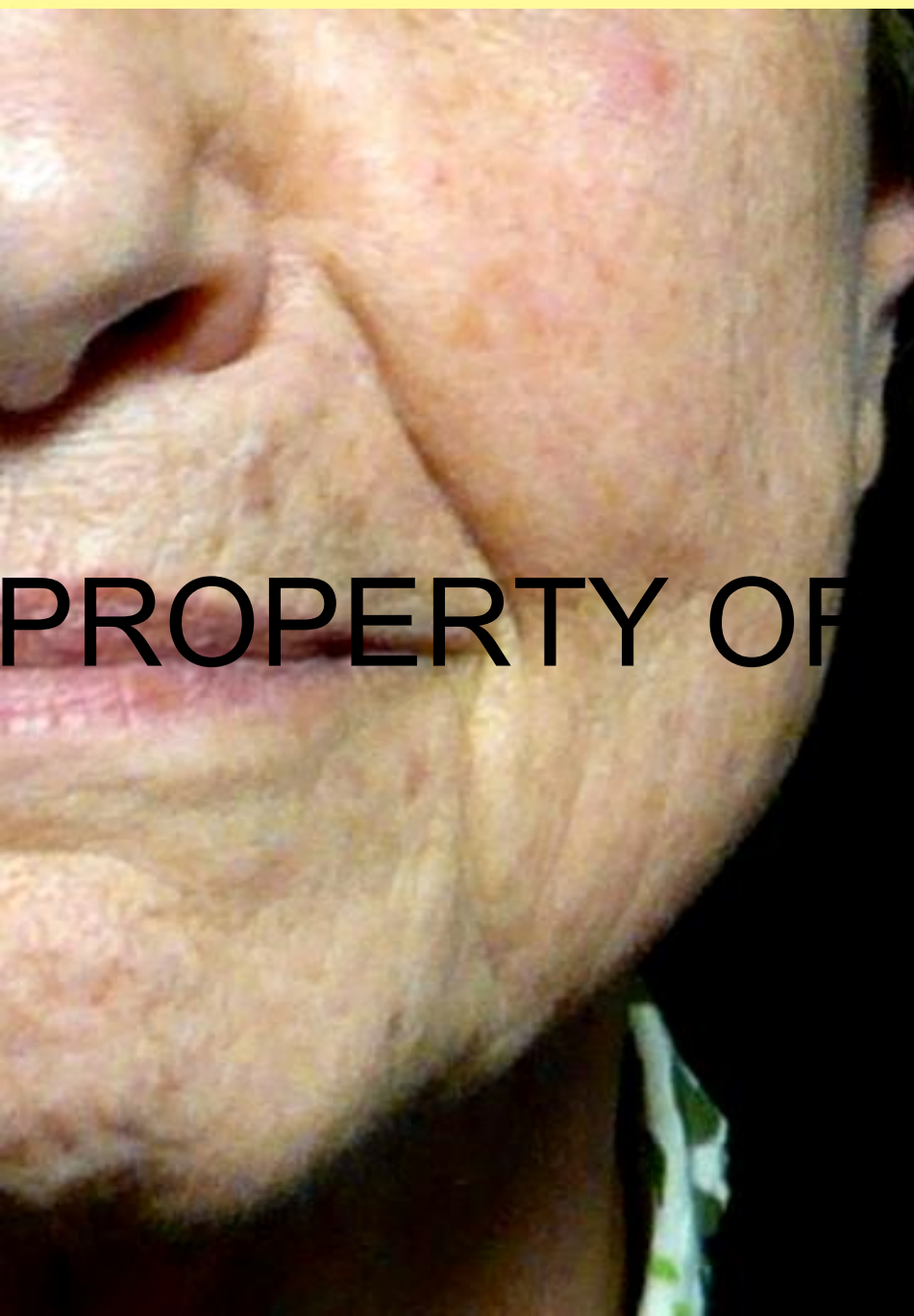
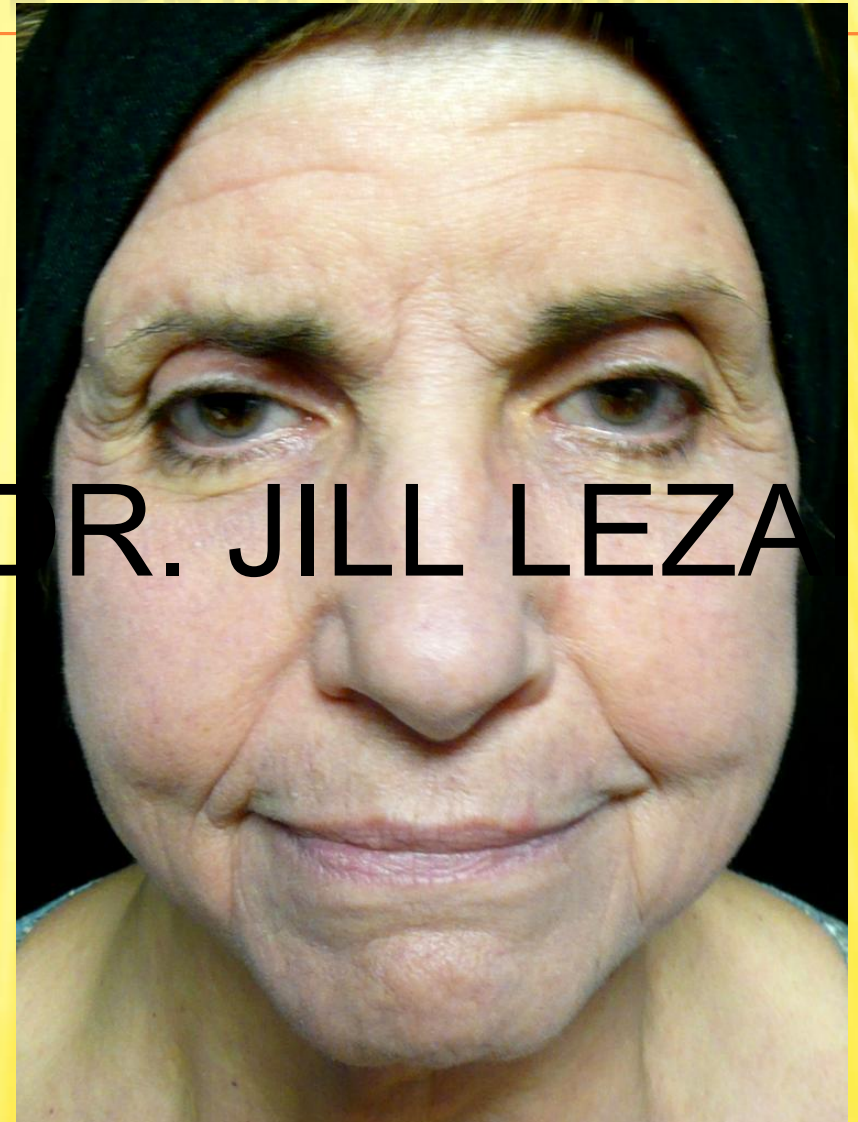Photo Courtesy of Jill Lezaic, DO

68 YEAR OLD FEMALE, SKIN TYPE III



Before



4 weeks after 1st treatment

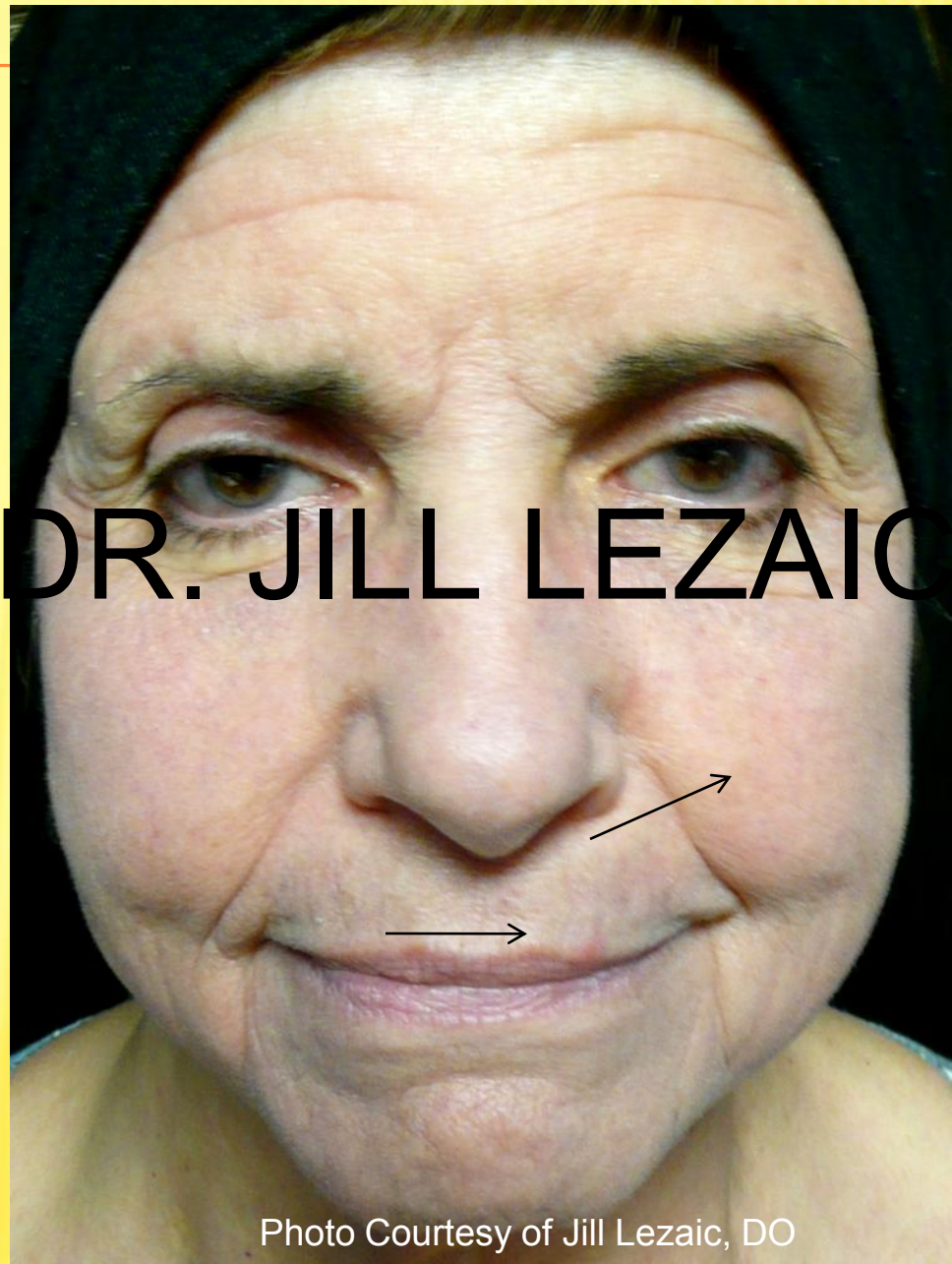
Photo Courtesy of Jill Lezaic, DO

PROPERTY OF DR. JILL LEZAIC

PEARL LASER FULL FACE

Before

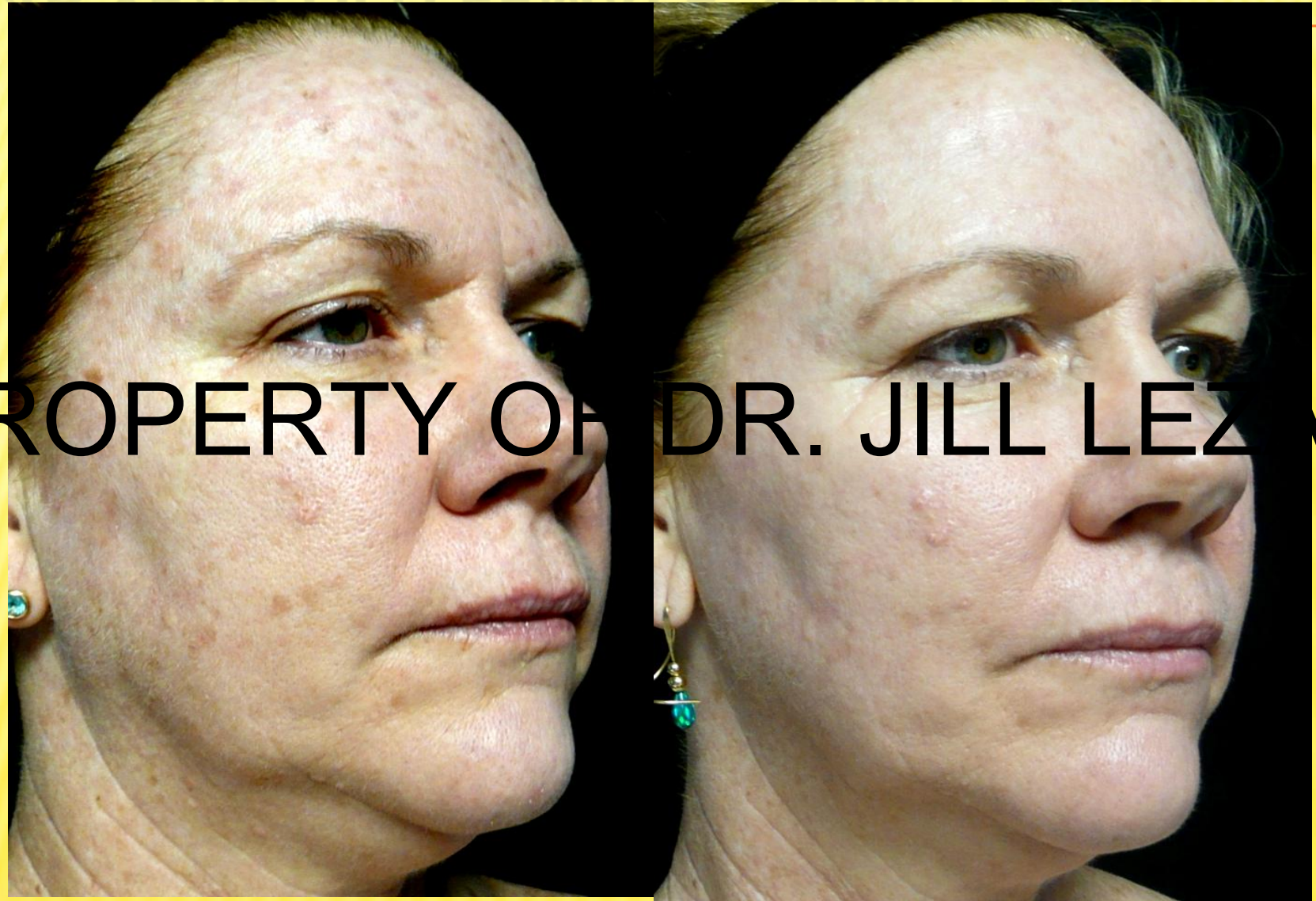4 weeks after 1 treatment



PROPERTY OF DR. JILL LEZAIC

Photo Courtesy of Jill Lezaic, DO

45 YEAR OLD FEMALE, SKIN TYPE II



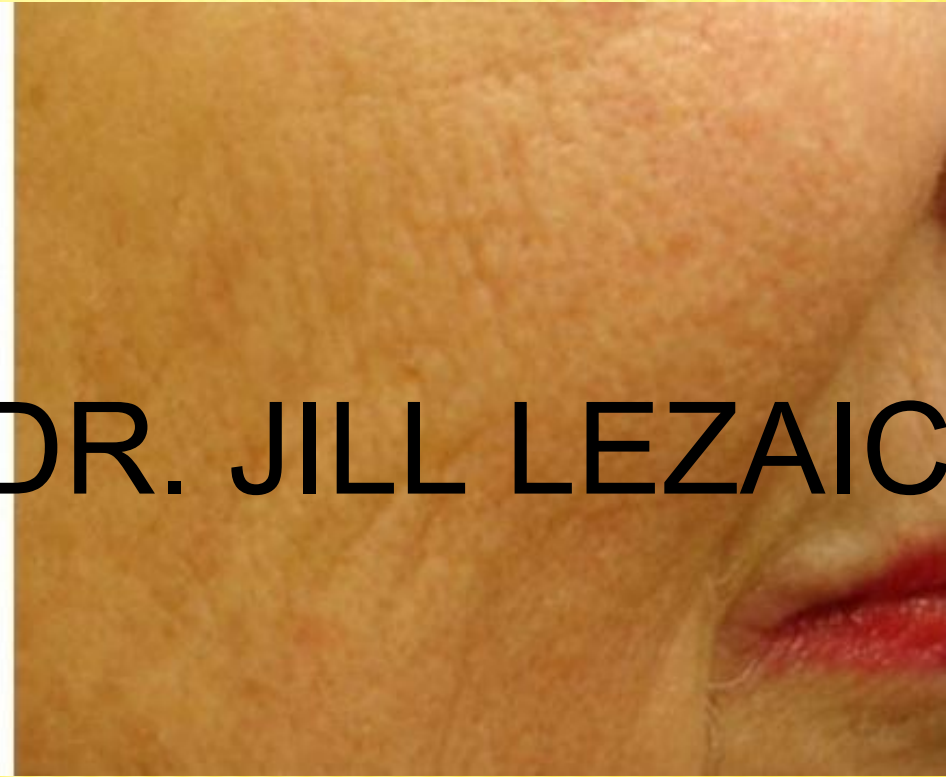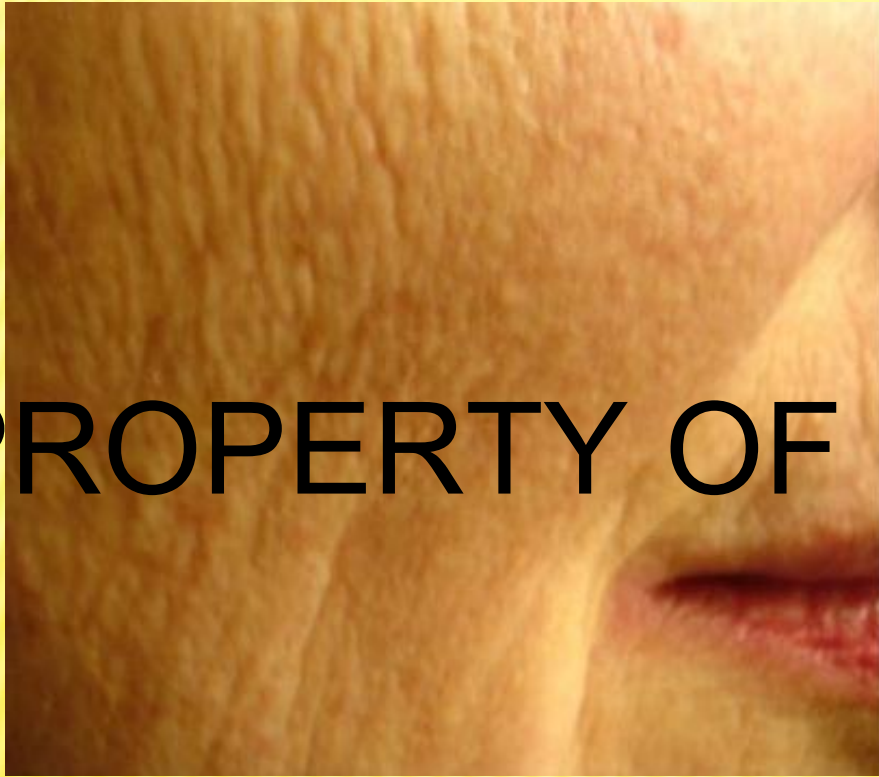PROPERTY OF DR. JILL LEZAIC

Before

4 weeks after 1st treatment

Photo Courtesy of Jill Lezaic, DO

FEMALE, SKIN TYPE III



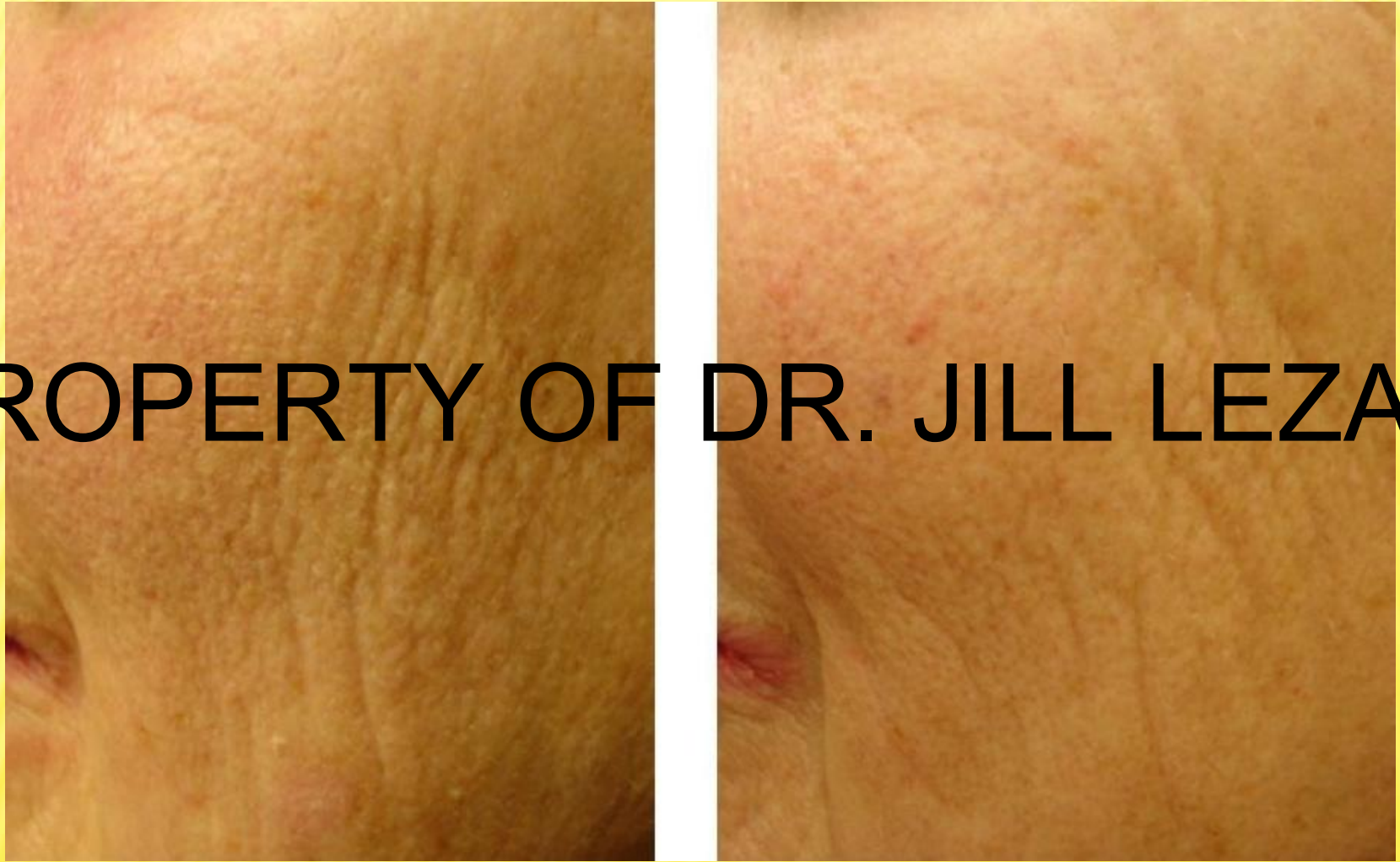PROPERTY OF DR. JILL LEZAIC

Before

2 Weeks After 1st Treatment

Photos Courtesy of Dr. Maritza Perez

SKIN TYPE III



Before

2 Weeks After 1st Treatment

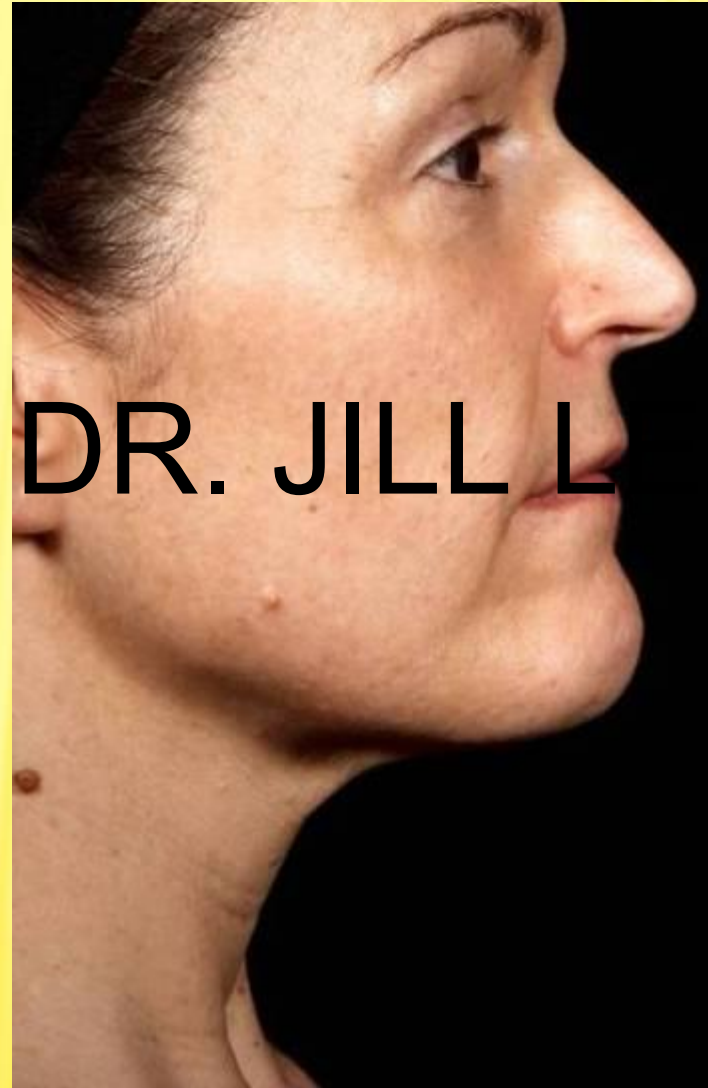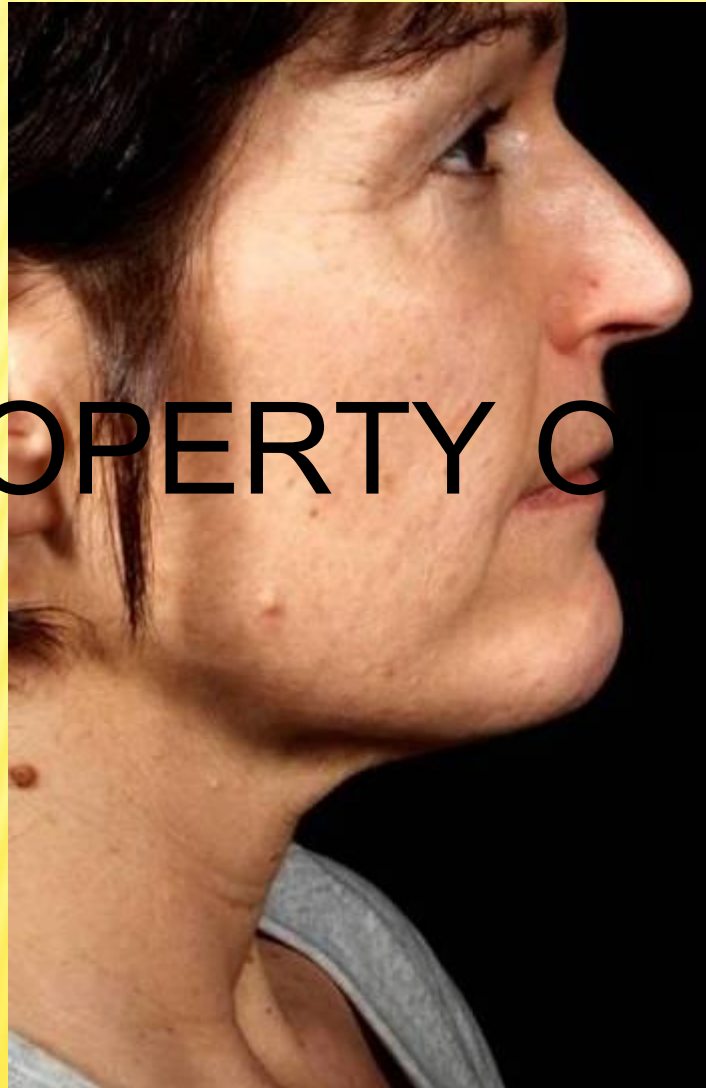Photos Courtesy of Dr. Maritza Perez

PROPERTY OF DR. JILL LEZAIC

PEARL

Before

5 Weeks After 2nd Treatment



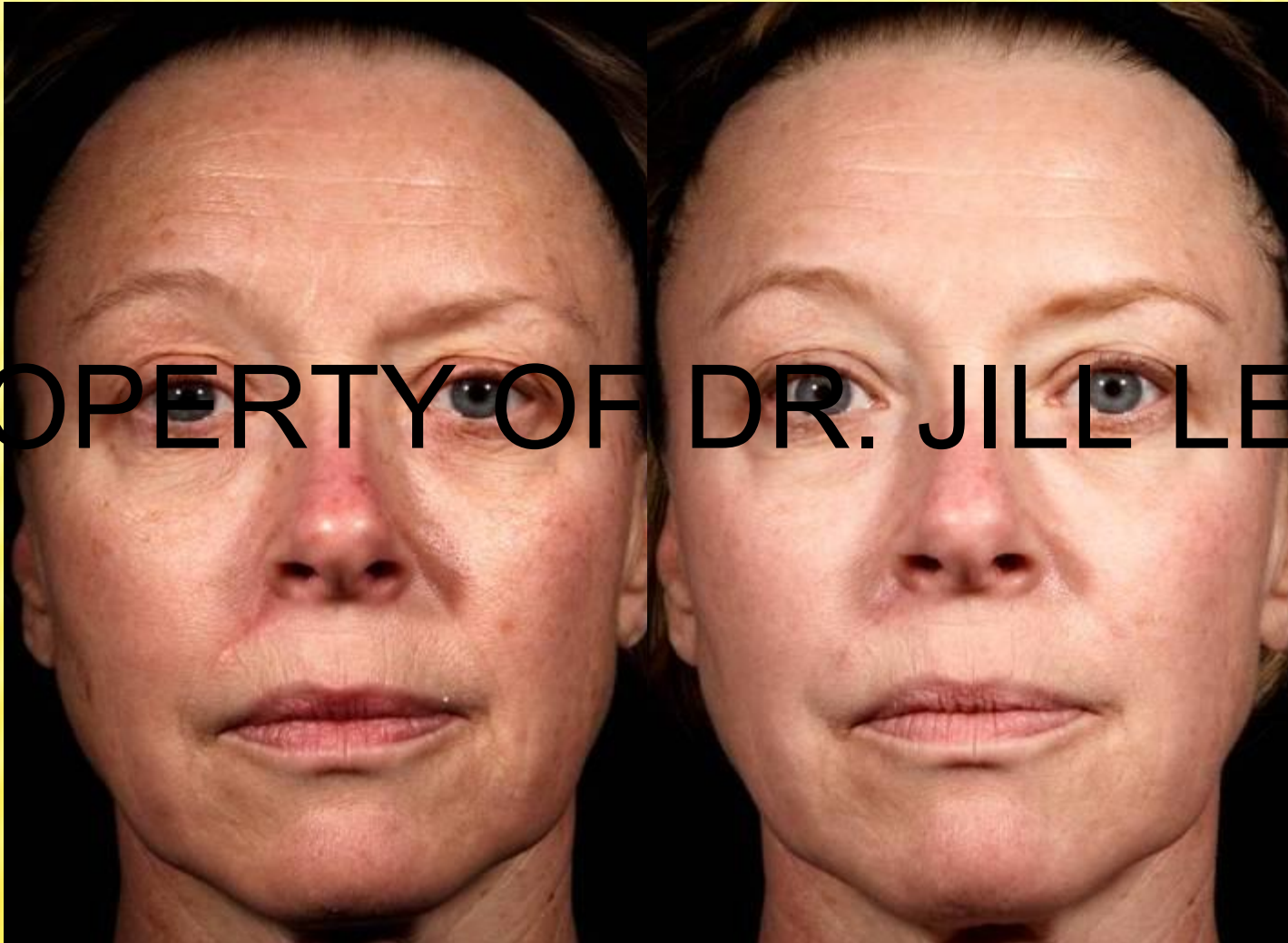PROPERTY OF DR. JILL L. ZAIC

3.5 J/cm², 0.4ms, 20% overlap, 2 passes over periorbital and perioral areas. Photos courtesy of Debra Jaliman, MD.

PEARL

Before

5 Weeks After 2nd Treatment



PROPERTY OF DR. JILL LEZAIC

Patient had basal cell cancer surgery prior to treatment on right upper nasolabial fold.

3.5 J/cm², 0.4ms, 20% overlap, 2 passes over perioral and periorbital areas. Right nasolabial fold not treated.

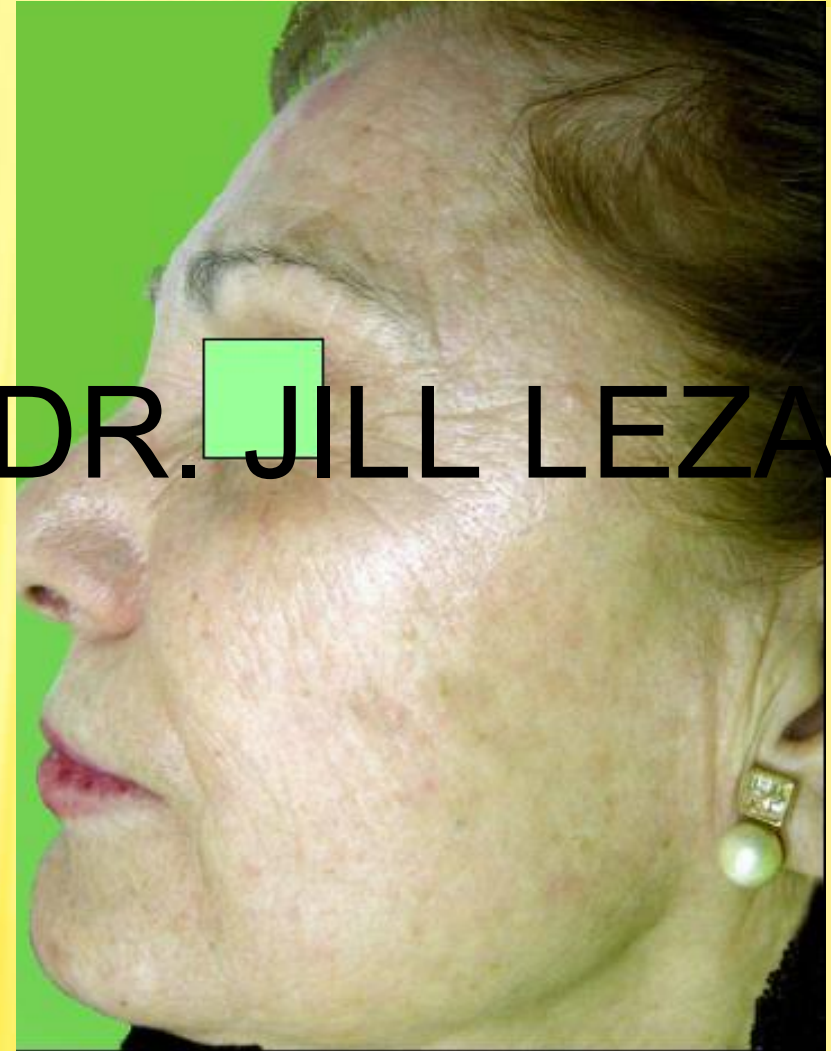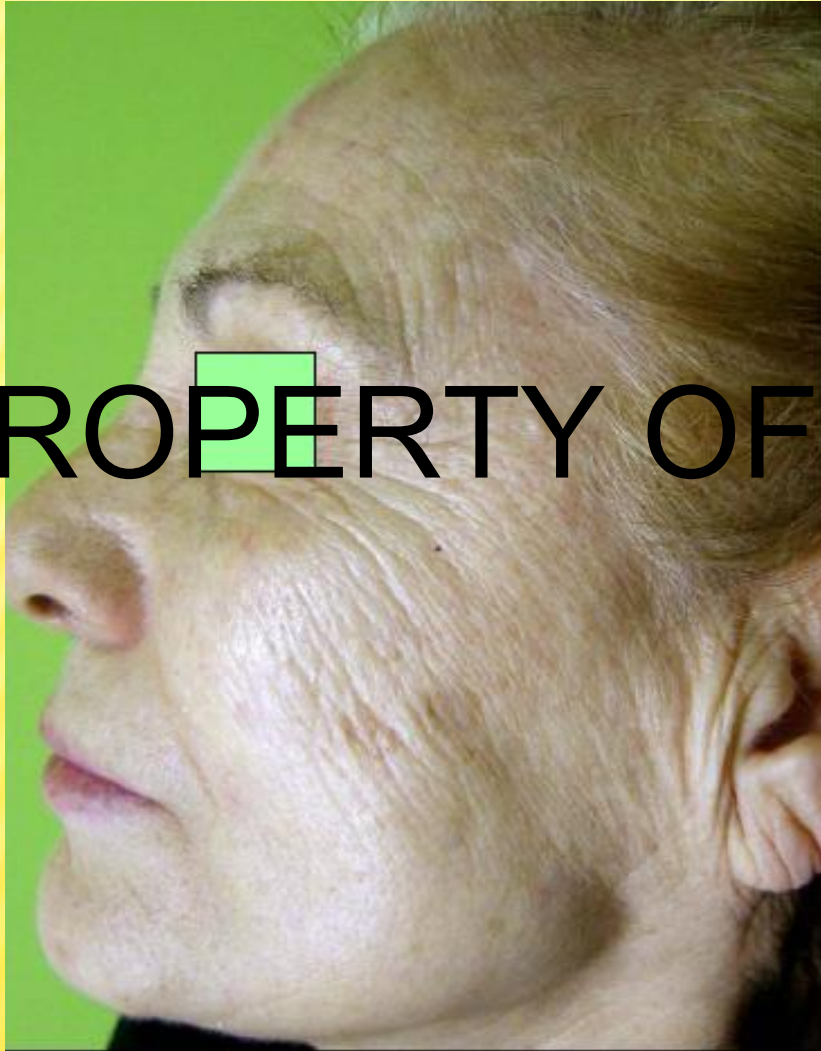A Cutera Aesthetic Seminar

Photos courtesy of Debra Jaliman, MD

Pearl

Before

15 days After 1 Treatment

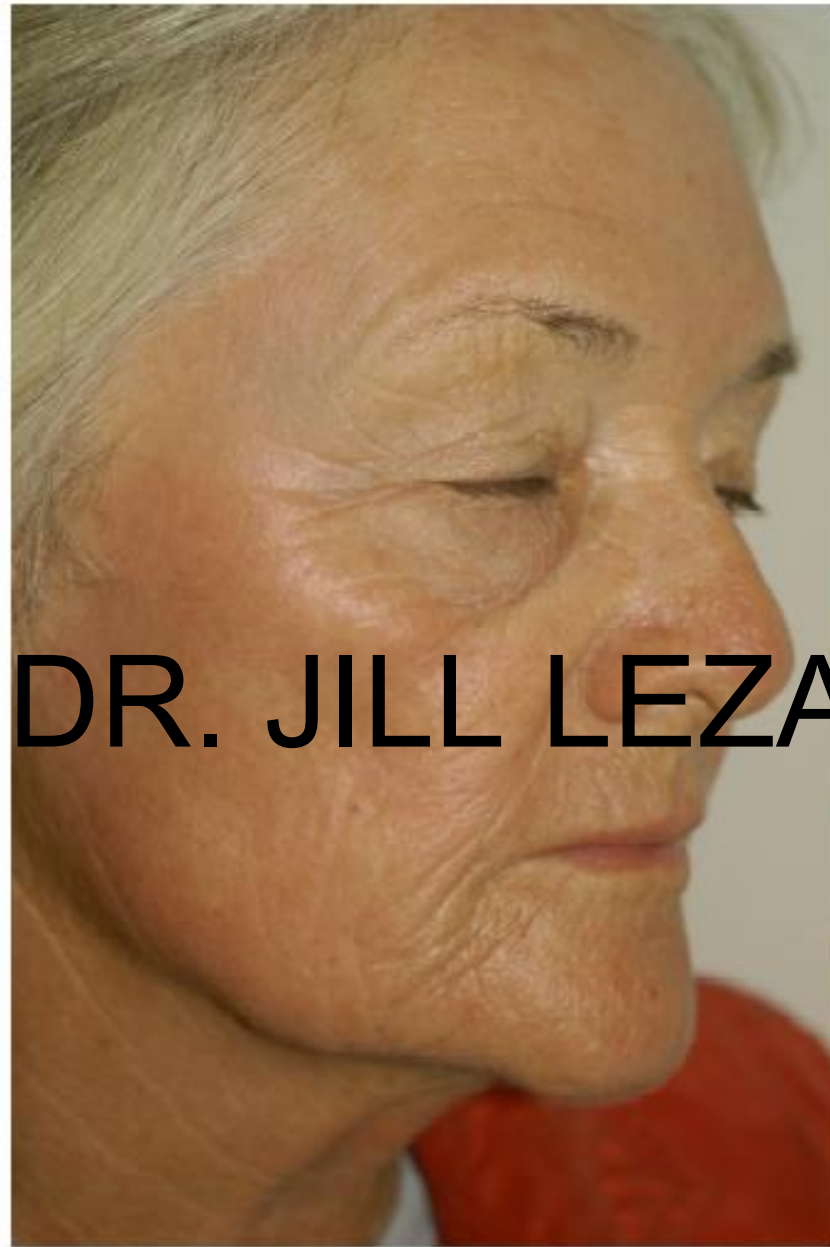

PROPERTY OF DR. JILL LEZAIC

A Cutera Aesthetic Geminal

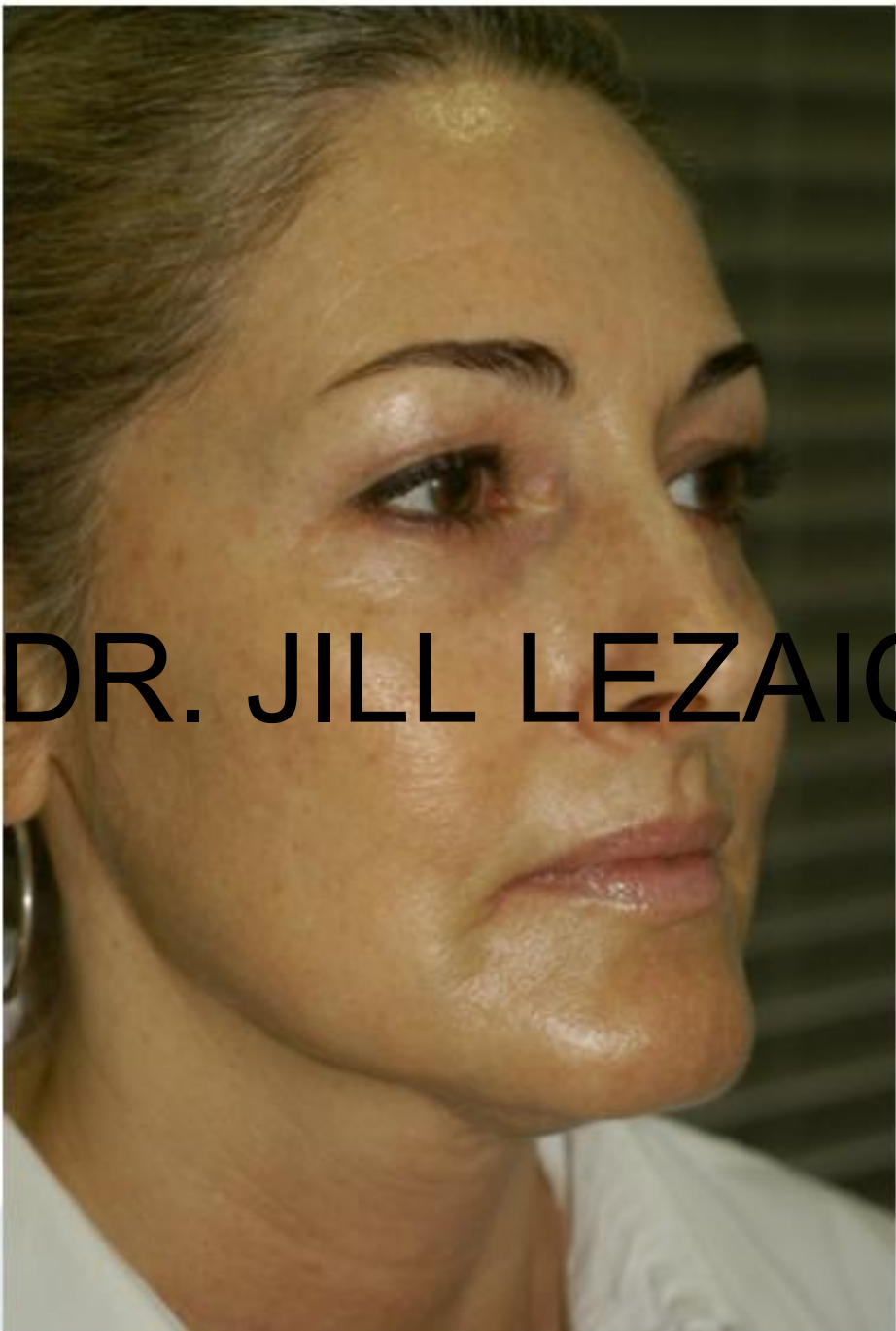3.5 J/cm², 0.4 ms, 20% overlap, 2 passes.
Photos courtesy of César Arroyo Romo, MD

PROPERTY OF DR. JILL LEZAIC



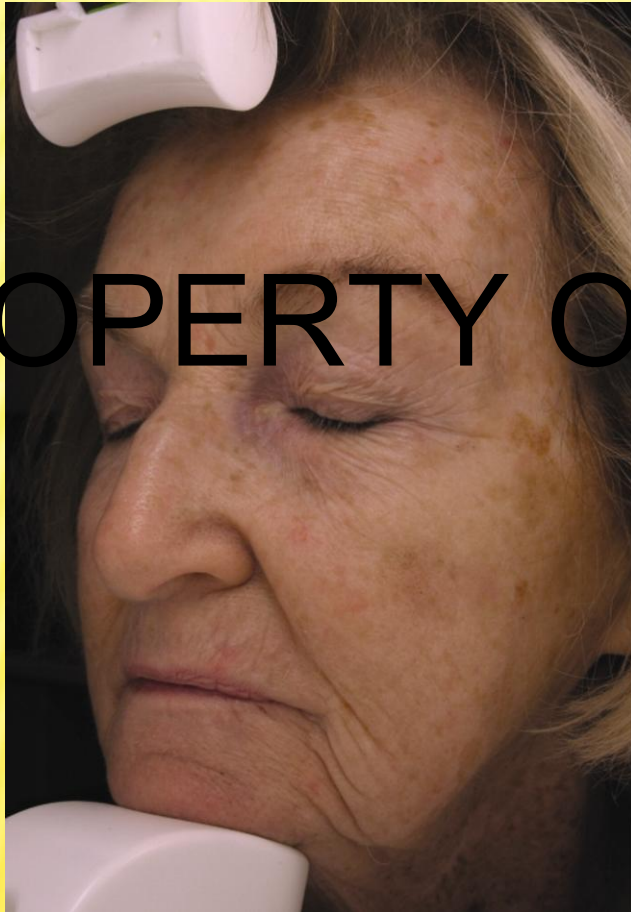1 Month after 2 treatments:
Limelight C $19\text{J}/\text{cm}^2$, Pearl $2.5\text{J}/\text{cm}^2$, 1-3 passes

PROPERTY OF DR. JILL LEZAIC

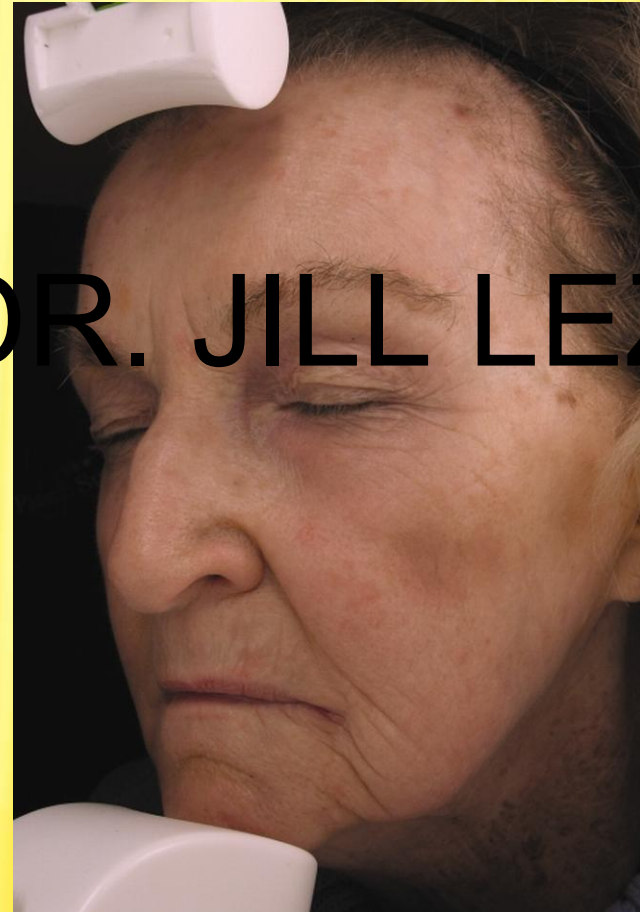

Pearl

Before



28 days After 2nd Treatment



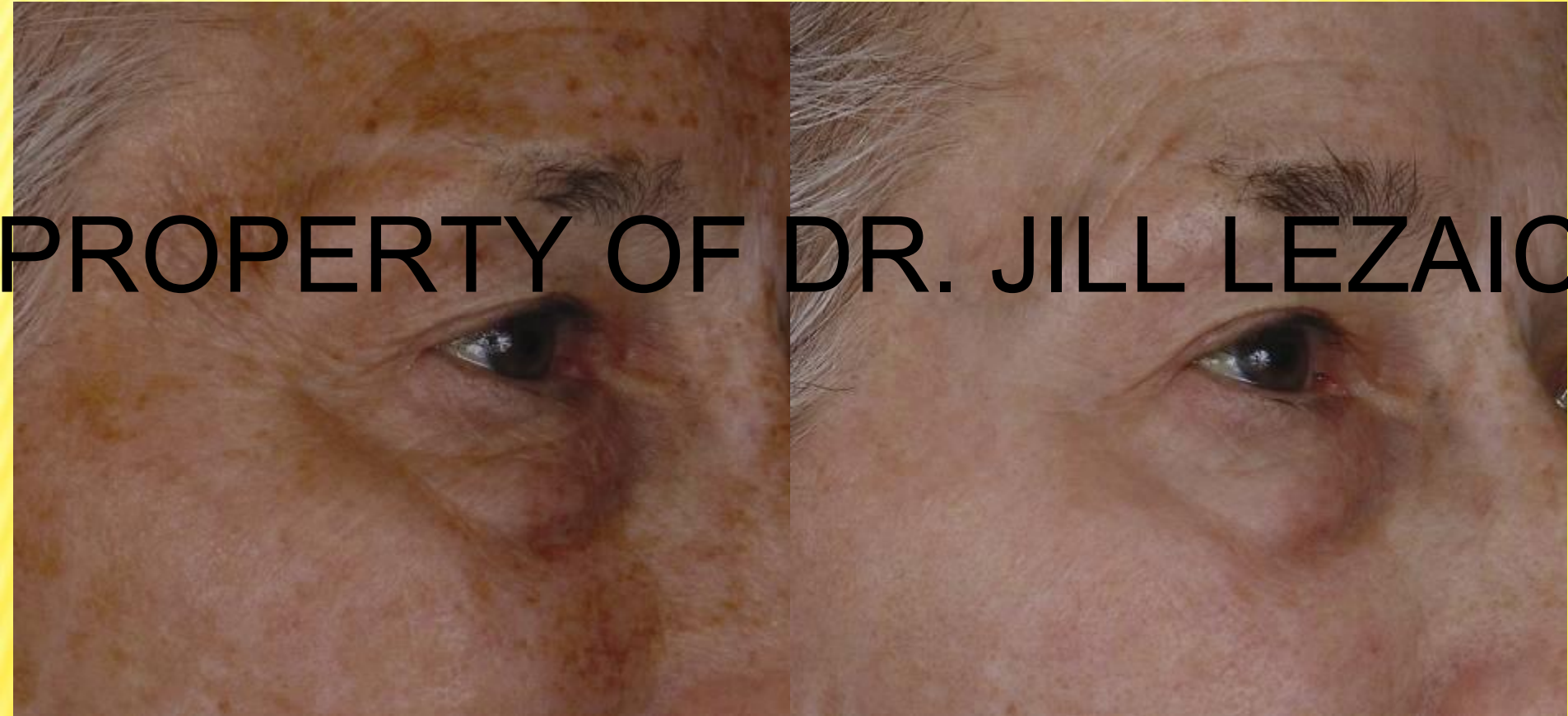PROPERTY OF DR. JILL LEZAIC

A Cutera 3.5 J/cm², 0.5 ms, 20% overlap
Photos courtesy of Barry DiBernardo, MD

Pearl

Before

5 Weeks After 2nd Treatment

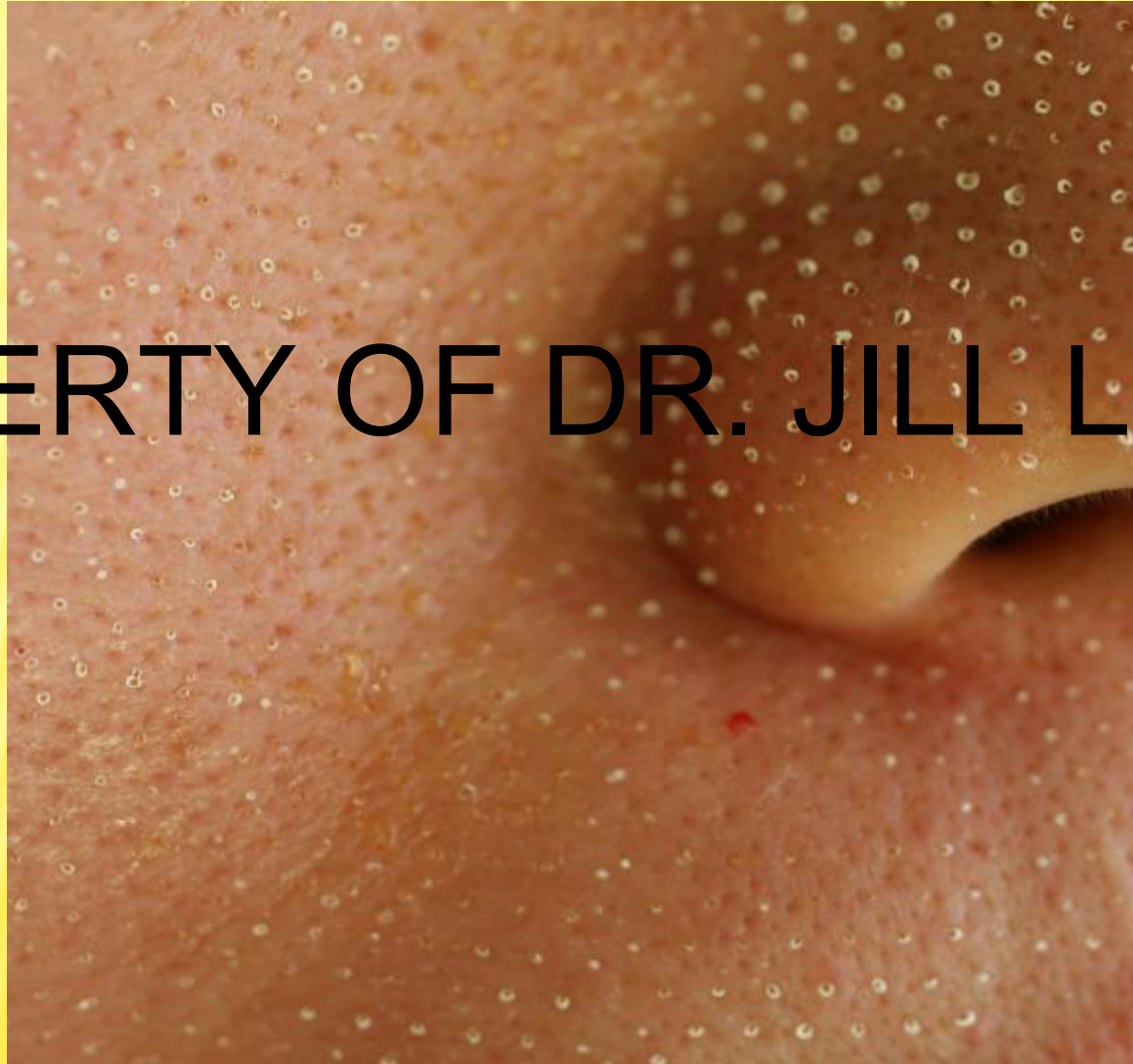

PROPERTY OF DR. JILL LEZAIC

PEARL FRACTIONAL LASER

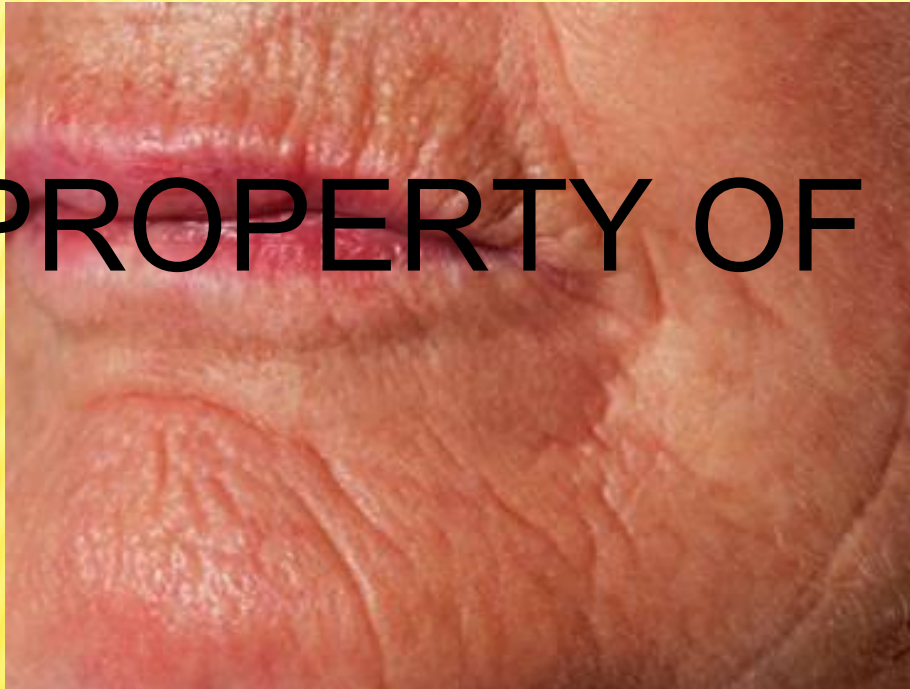CLOSE UP IMMEDIATE POST

PROPERTY OF DR. JILL LEZAIC

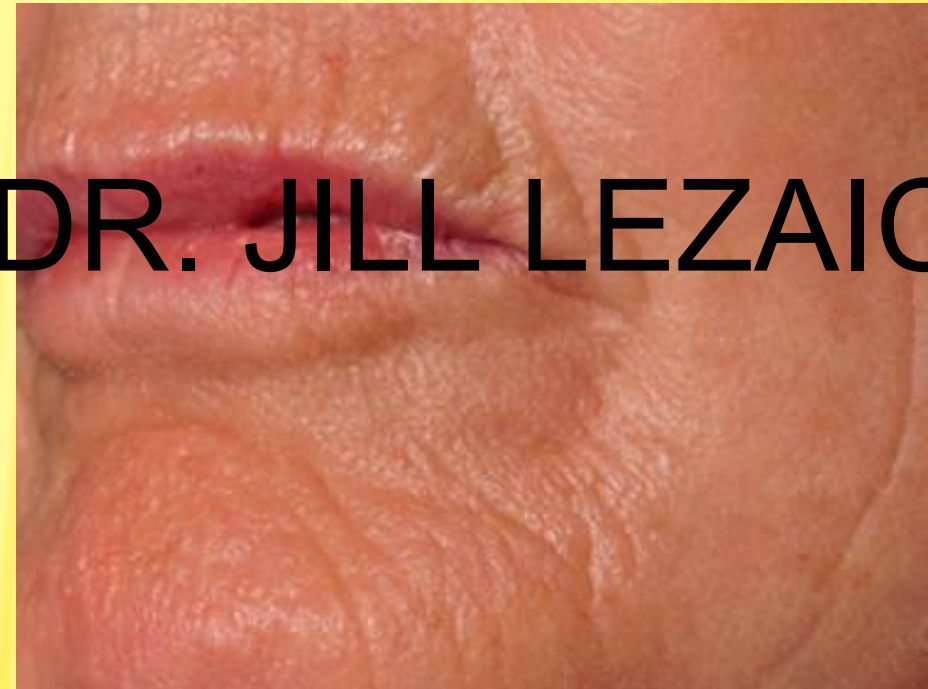

Pearl Fractional Single Treatment Results

Pre Tx



6 Weeks Post

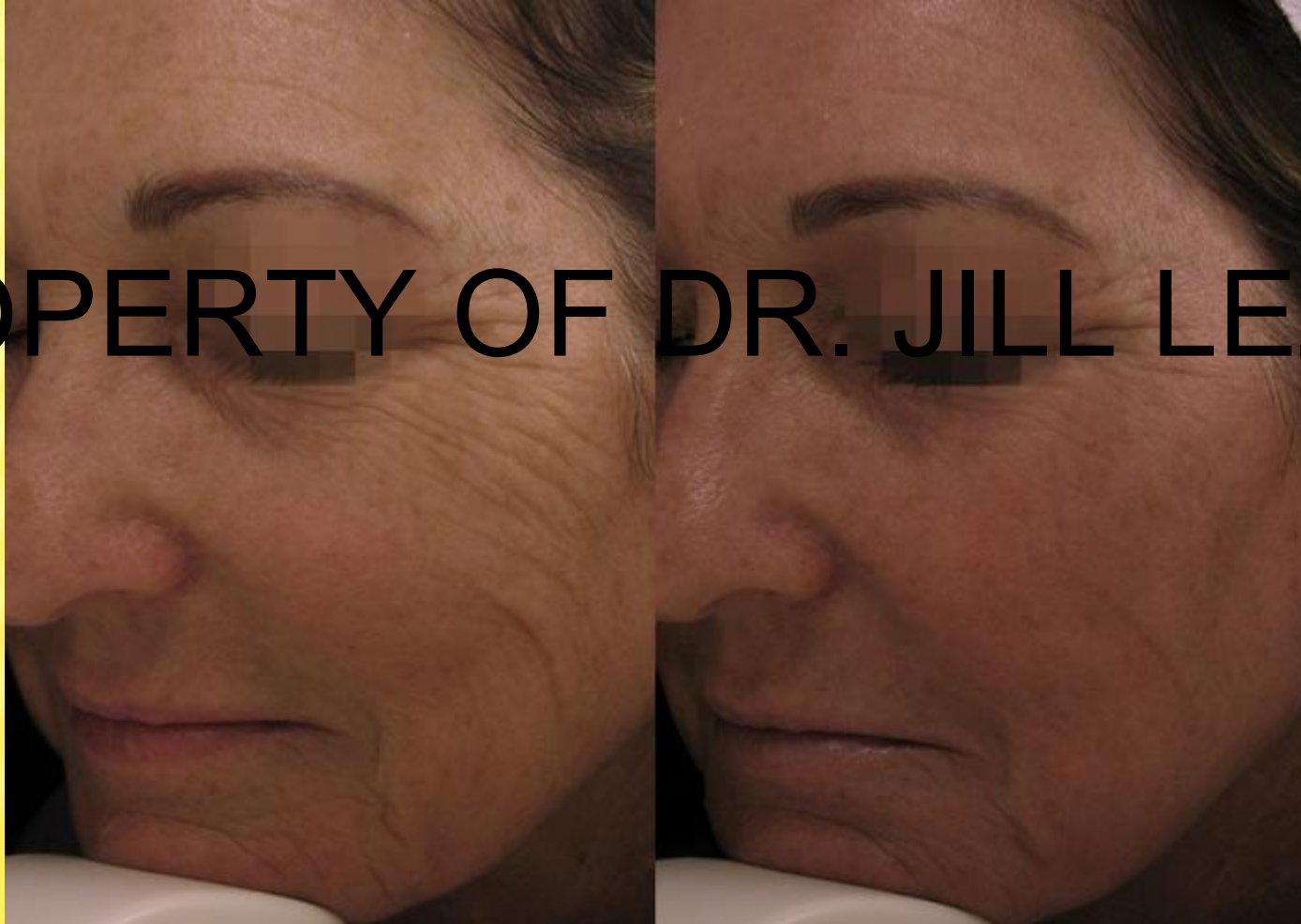

PROPERTY OF DR. JILL LEZAIC

PEARL FRACTIONAL SINGLE TREATMENT RESULTS

Before

1 Month Post



PROPERTY OF DR. JILL LEZAIC

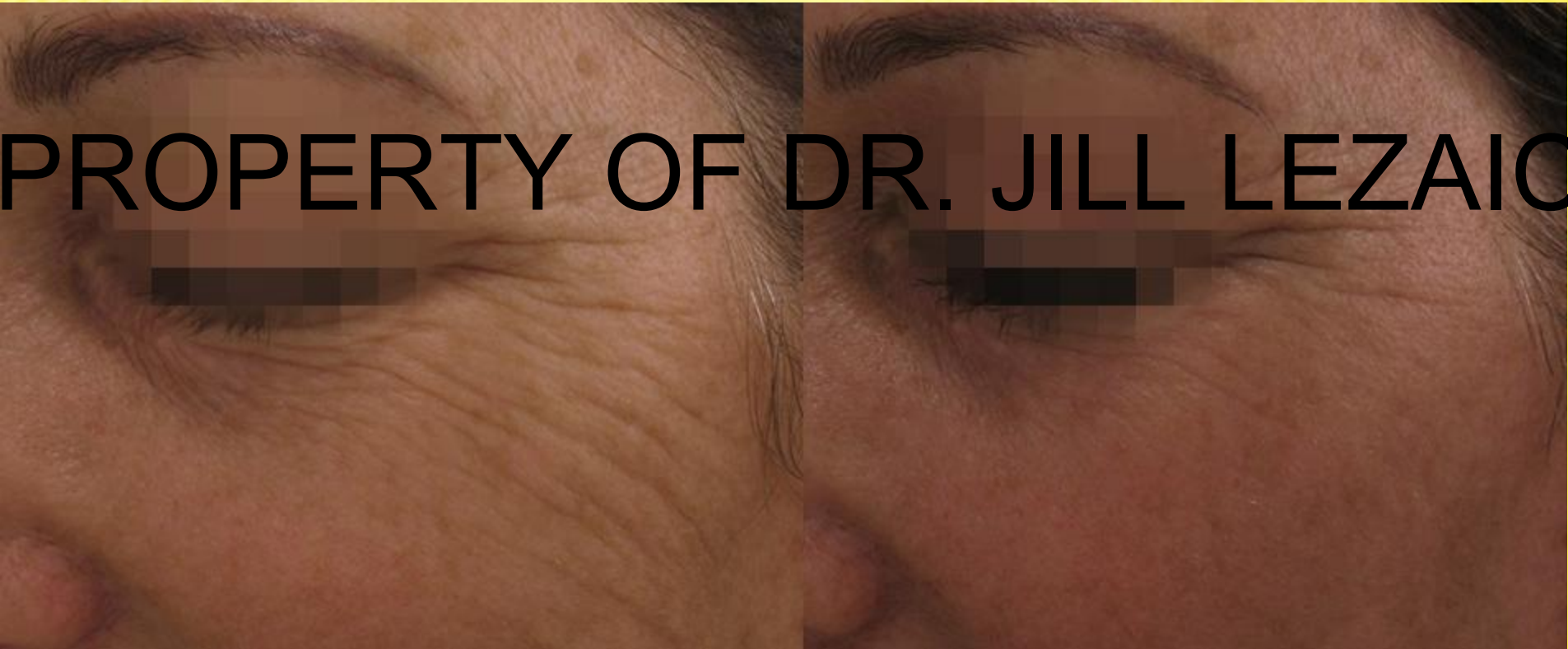Full face treated 160mJ, density 2, 2 passes (third perioral pass 240mJ density 2)

Photos courtesy of Leonardo Rasi, MD

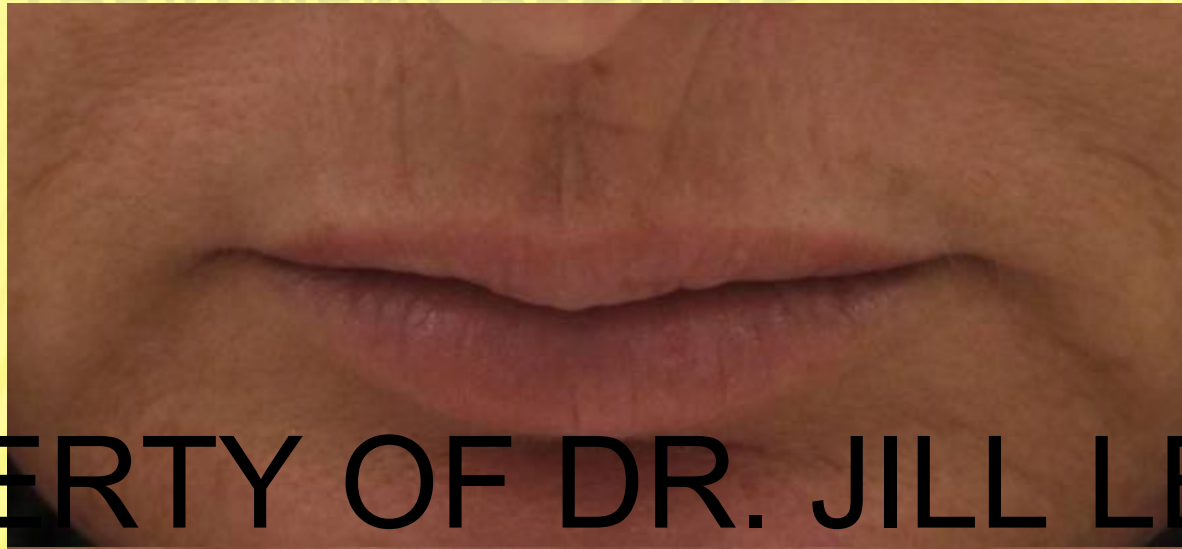PEARL FRACTIONAL SINGLE TREATMENT RESULTS

Before

1 Month Post

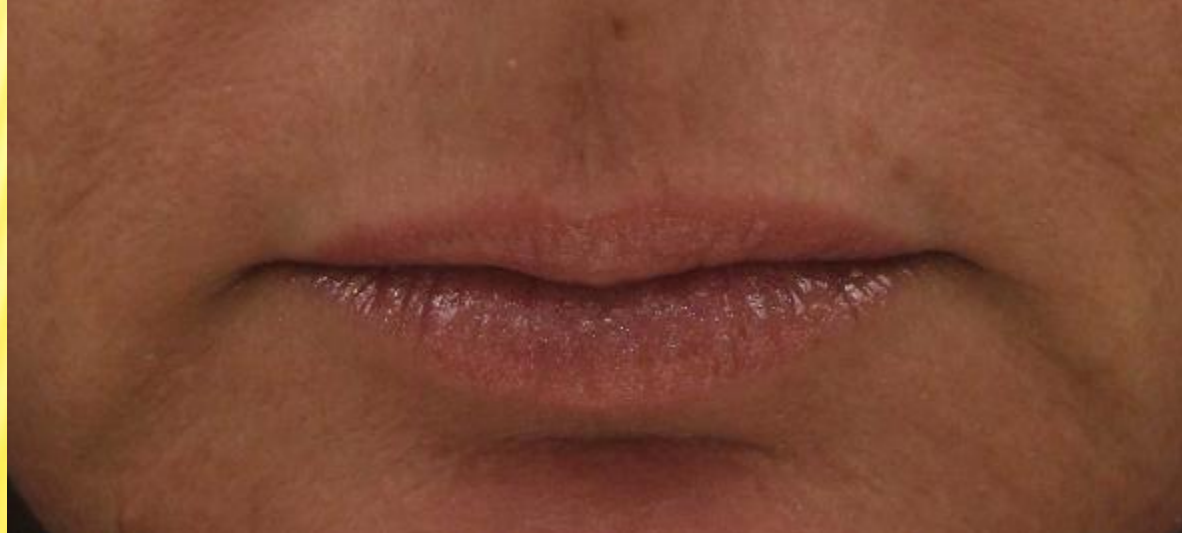

PEARL FRACTIONAL SINGLE TREATMENT RESULTS



Before

PROPERTY OF DR. JILL LEZAIC

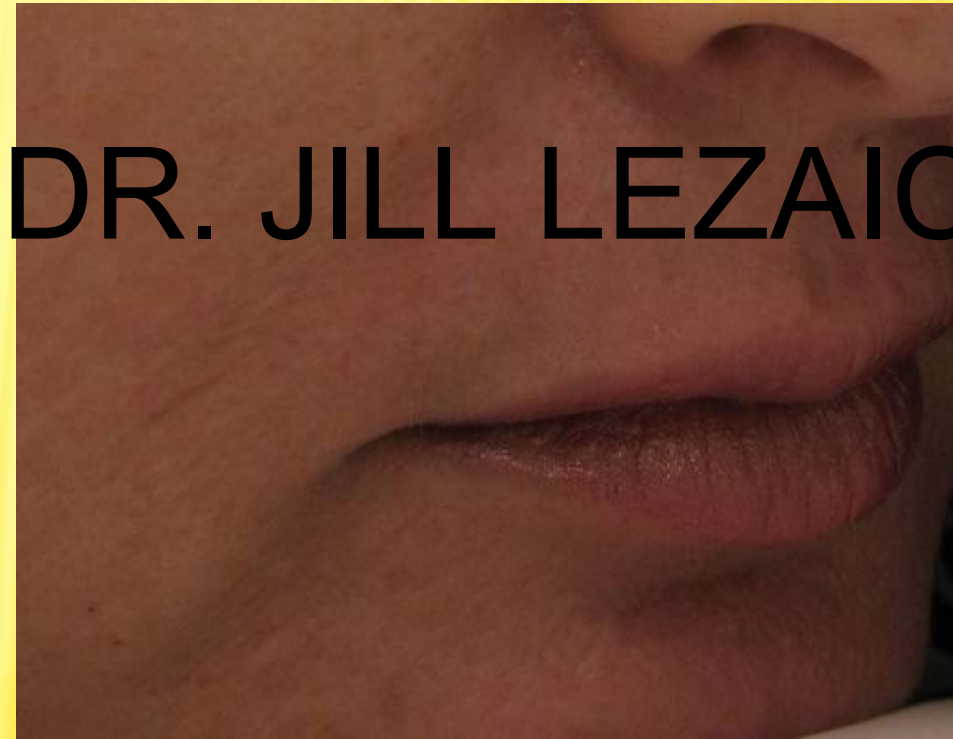
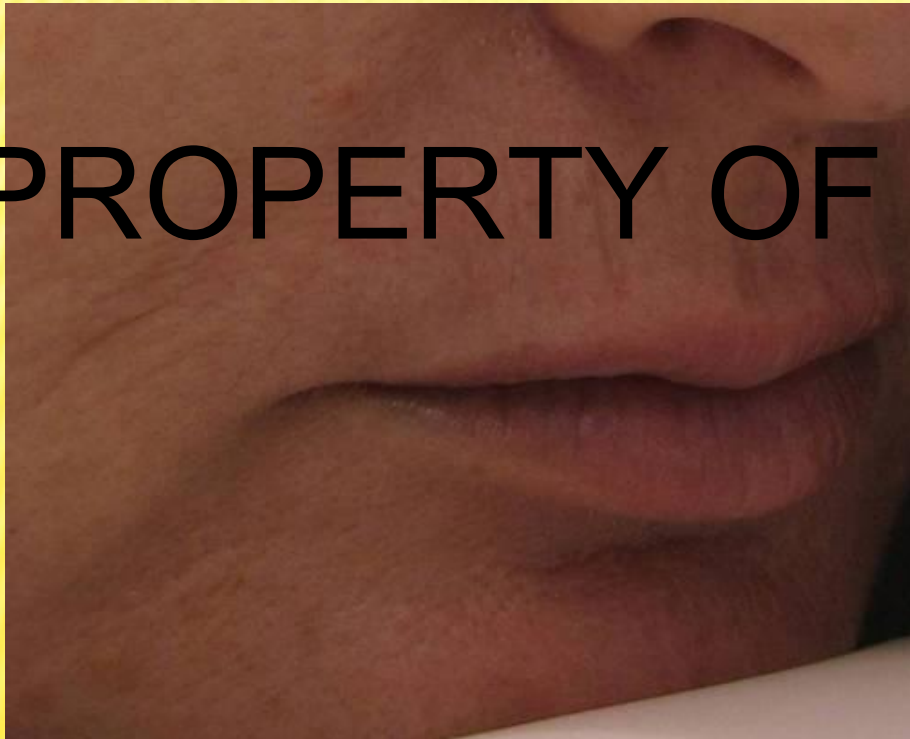
6 Weeks After

PEARL FRACTIONAL

Before

28 Days After

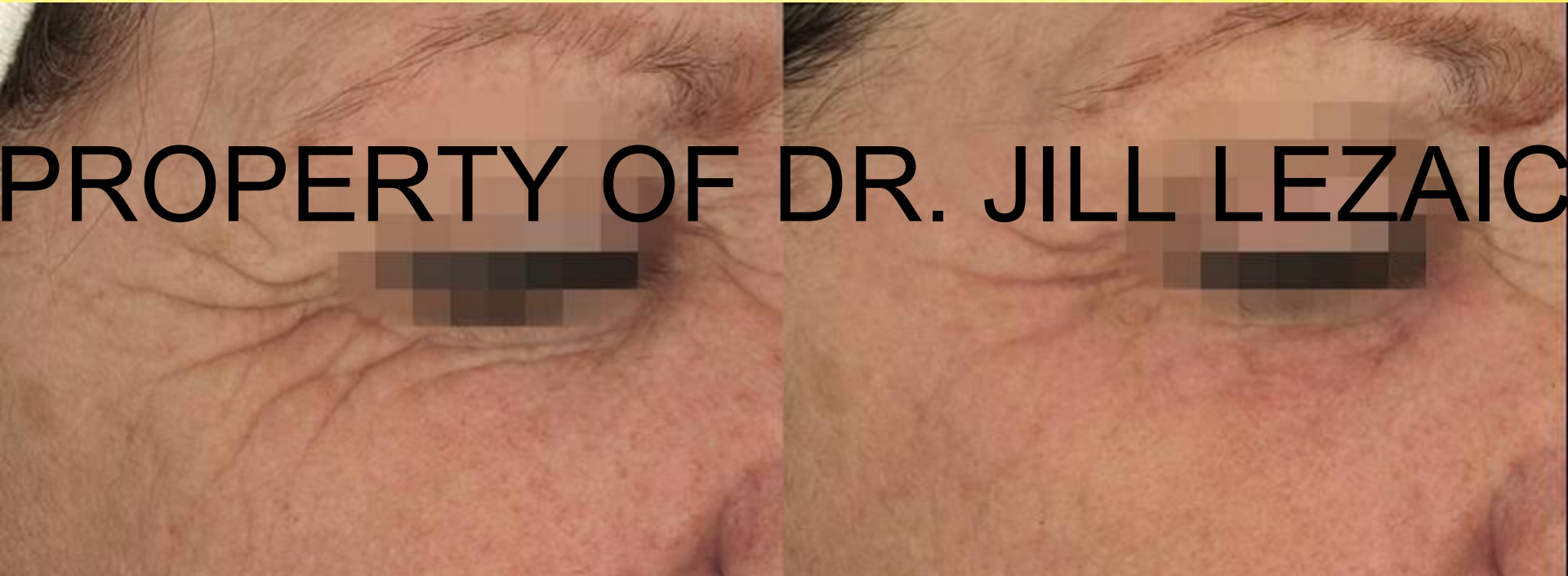

PROPERTY OF DR. JILL LEZAIC

PEARL FRACTIONAL SINGLE TREATMENT RESULTS

Before

1 Month Post

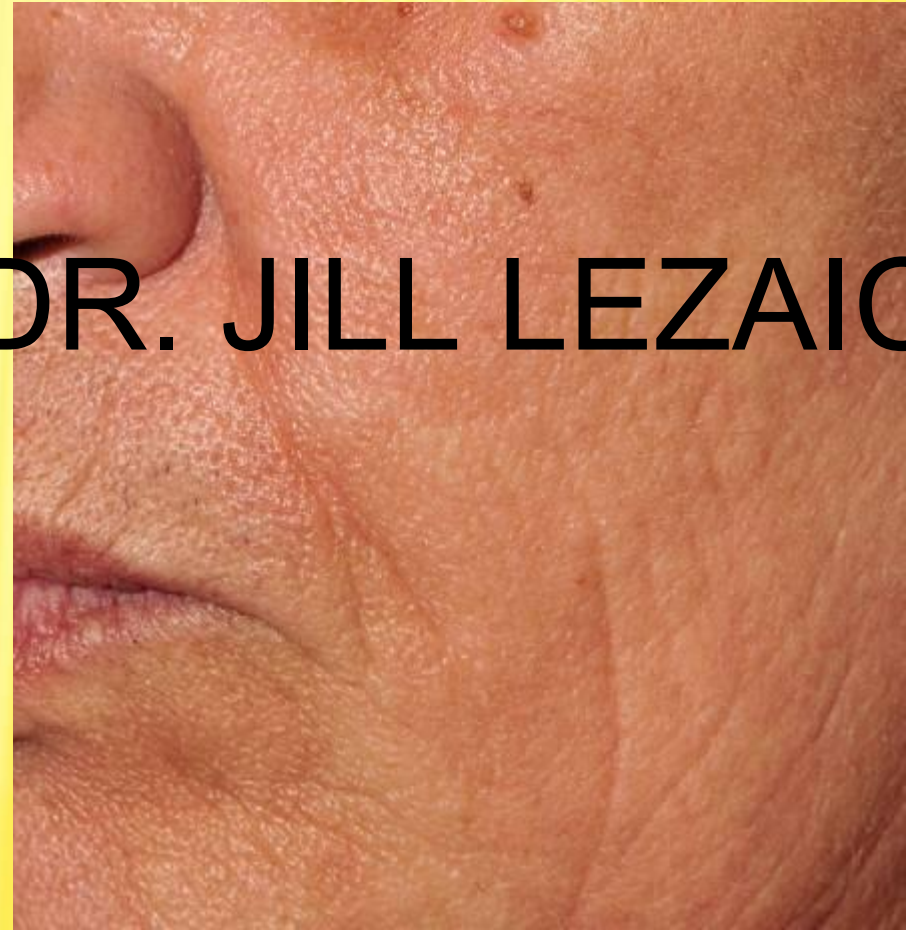
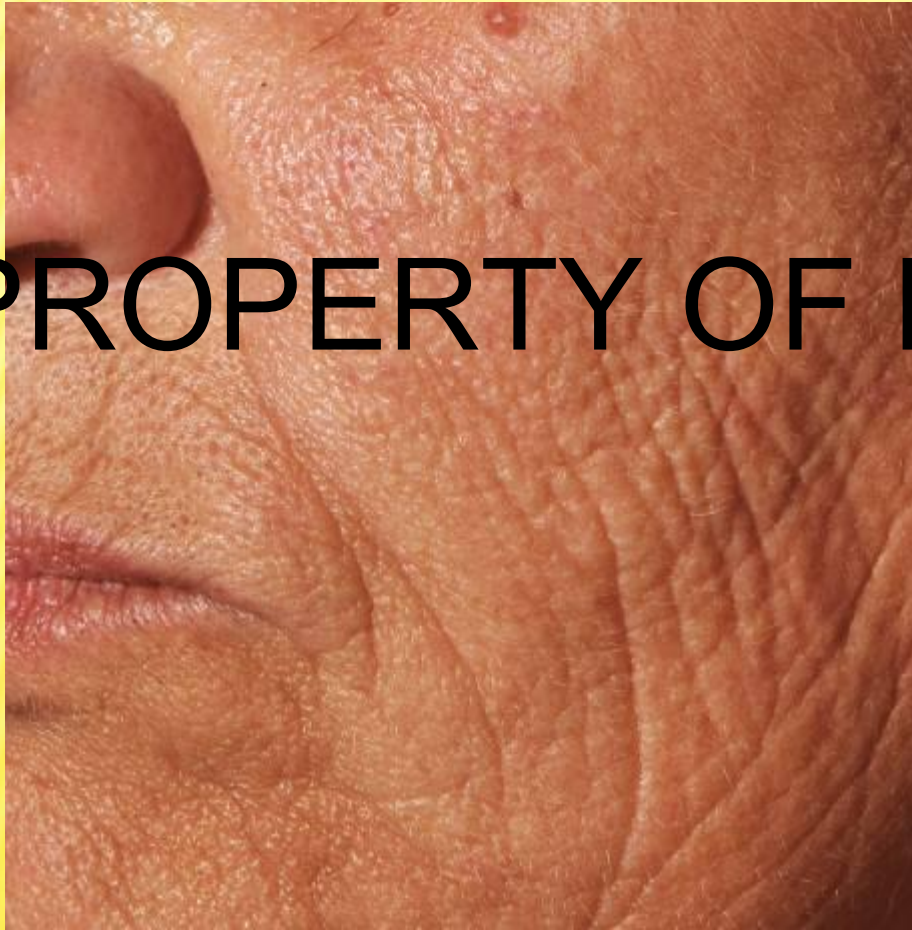
Full face save periocular area treated at 240 mJ, density 2, 1 pass. Periocular area treated at 160 mJ, density 3, 1 pass.
Photos courtesy of Leonardo Rasi, MD

Pearl Fractional Single Treatment Results

Pre Tx

6 Weeks Post

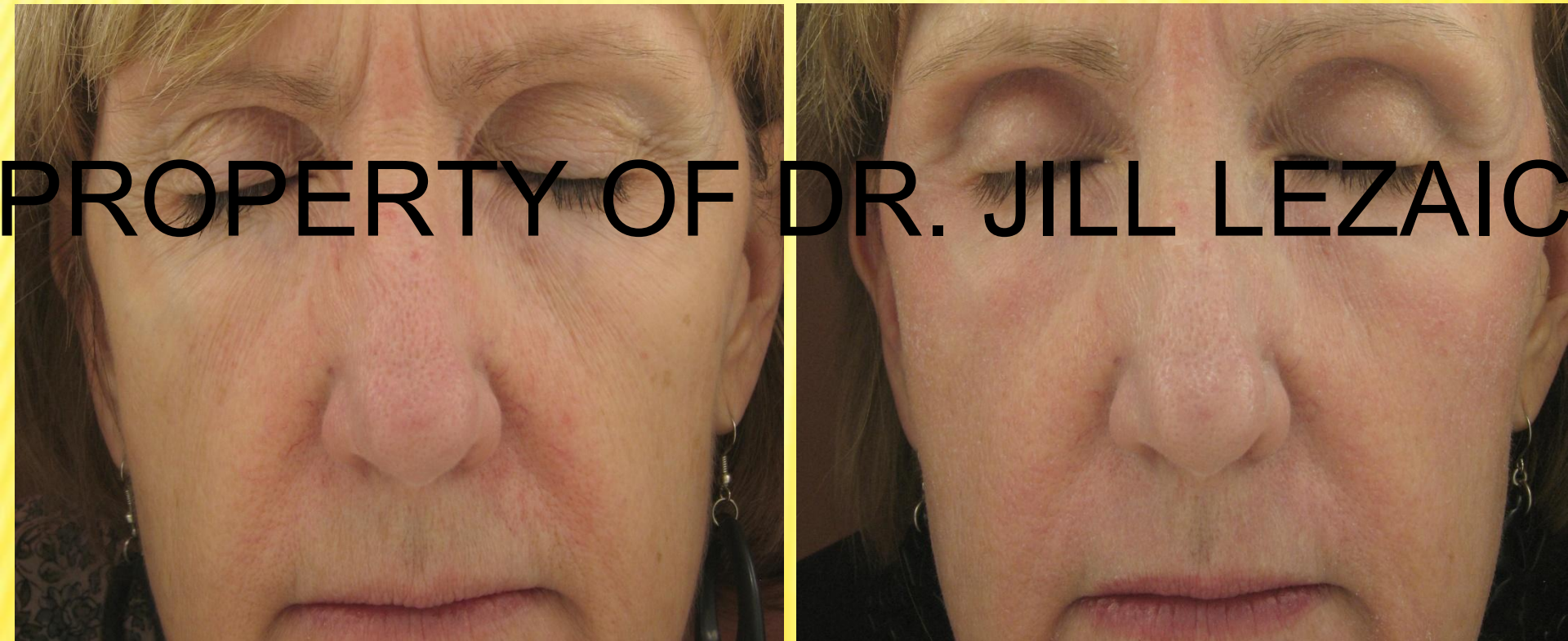

PROPERTY OF DR. JILL LEZAIC

PEARL FULL FACE & PEARL FRACTIONAL AROUND THE EYES & MOUTH

BEFORE

4 WEEKS AFTER 1 TREATMENT



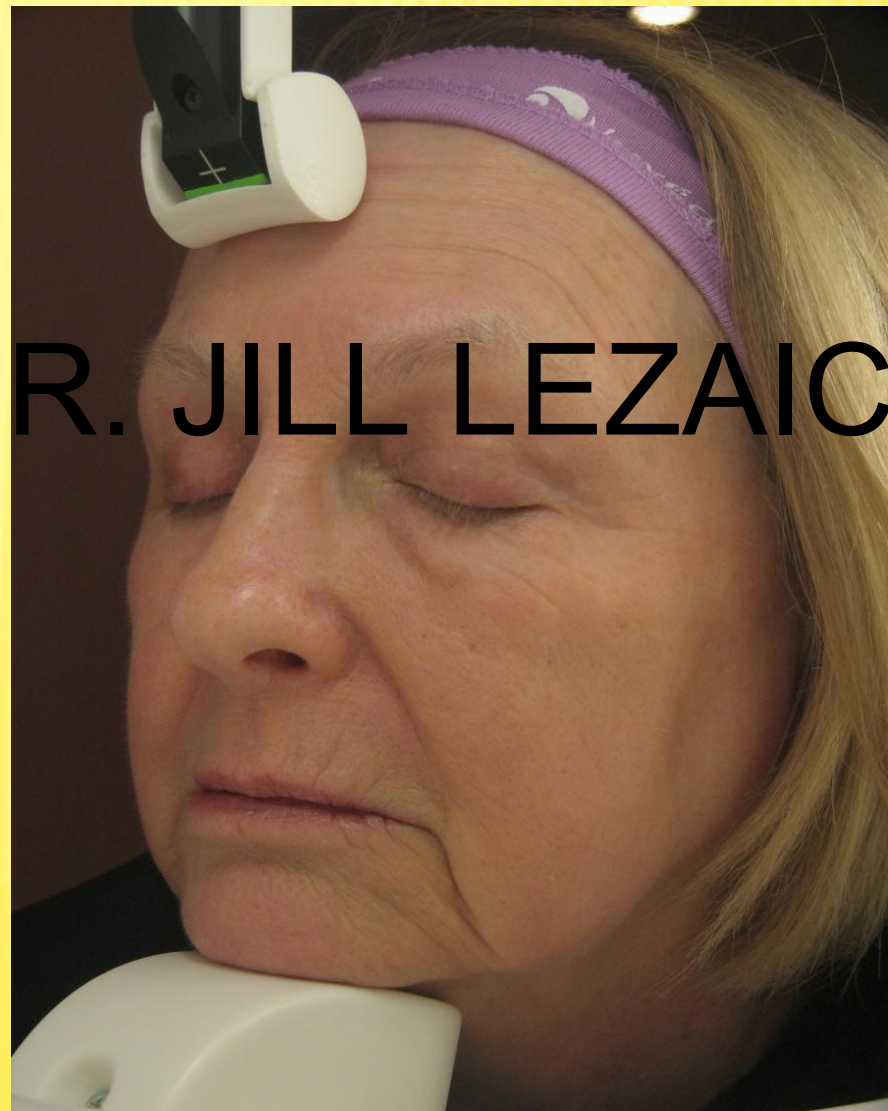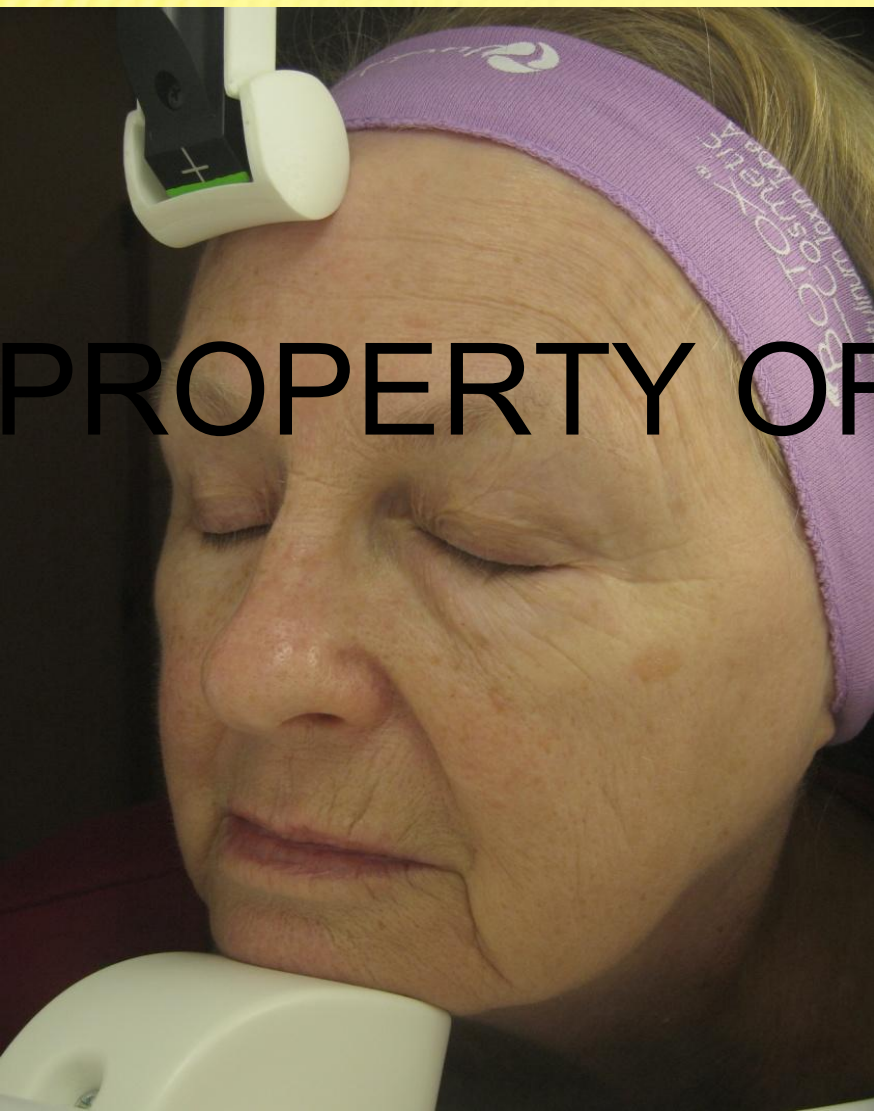PROPERTY OF DR. JILL LEZAIC

Corneal Shields were used & upper eyelids were treated

PEARL FRACTIONAL

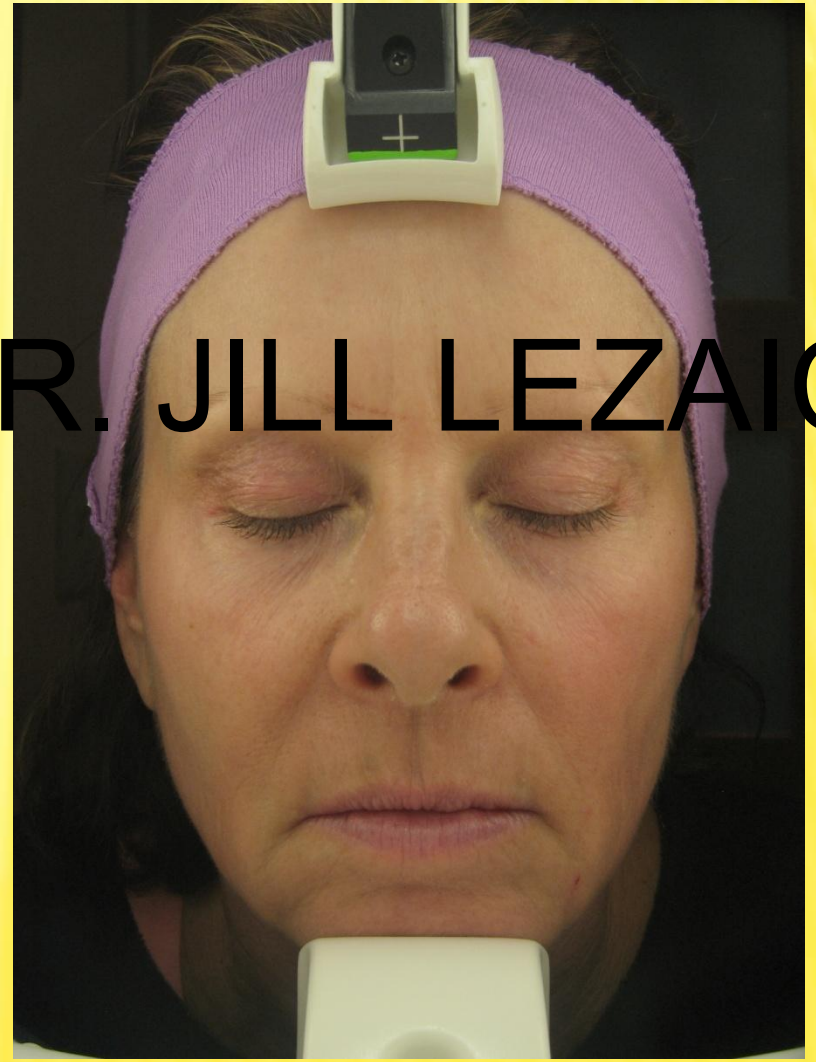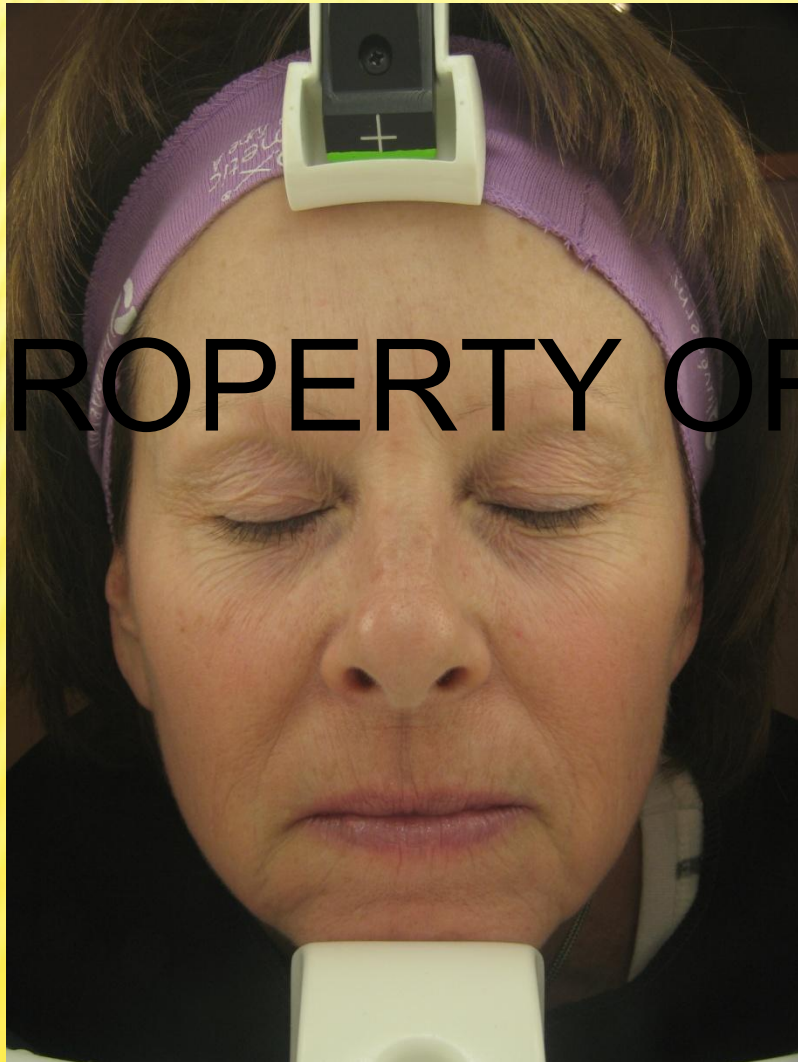✘ Before

✘ 4 weeks after 1 treatment



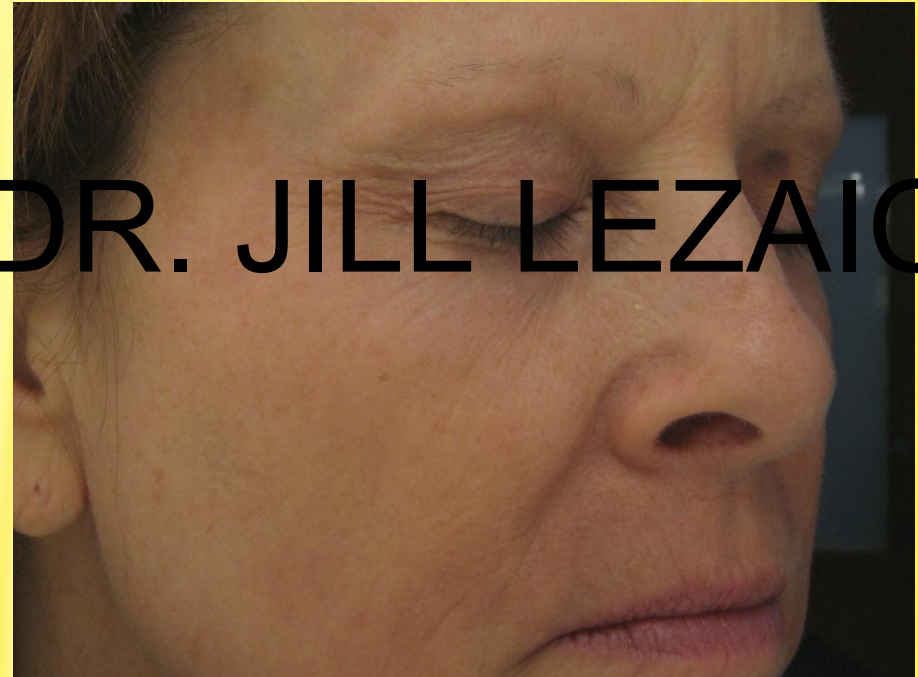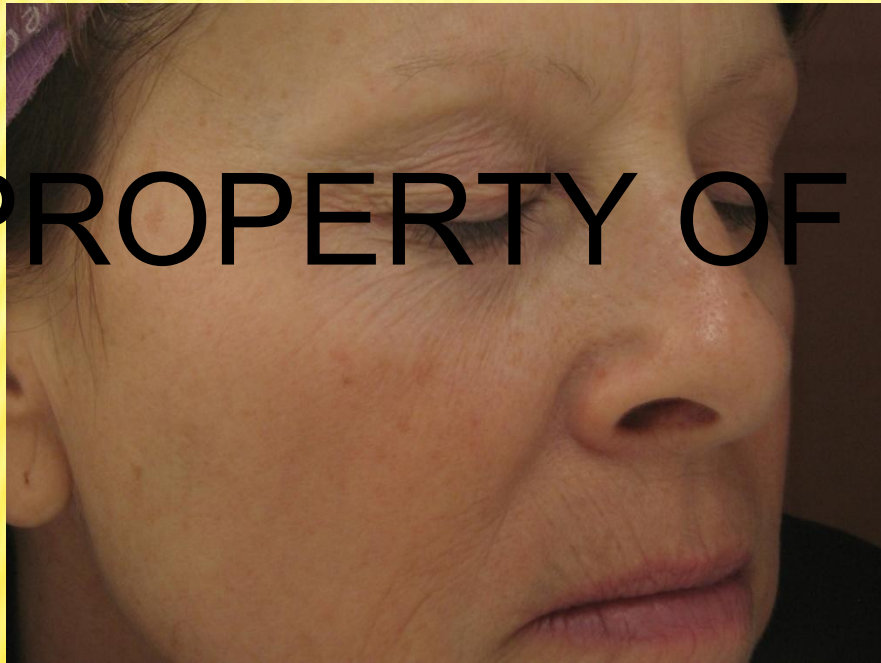PROPERTY OF DR. JILL LEZAIC

PEARL FRACTIONAL



PROPERTY OF DR. JILL LEZAIC

PEARL FRACTIONAL

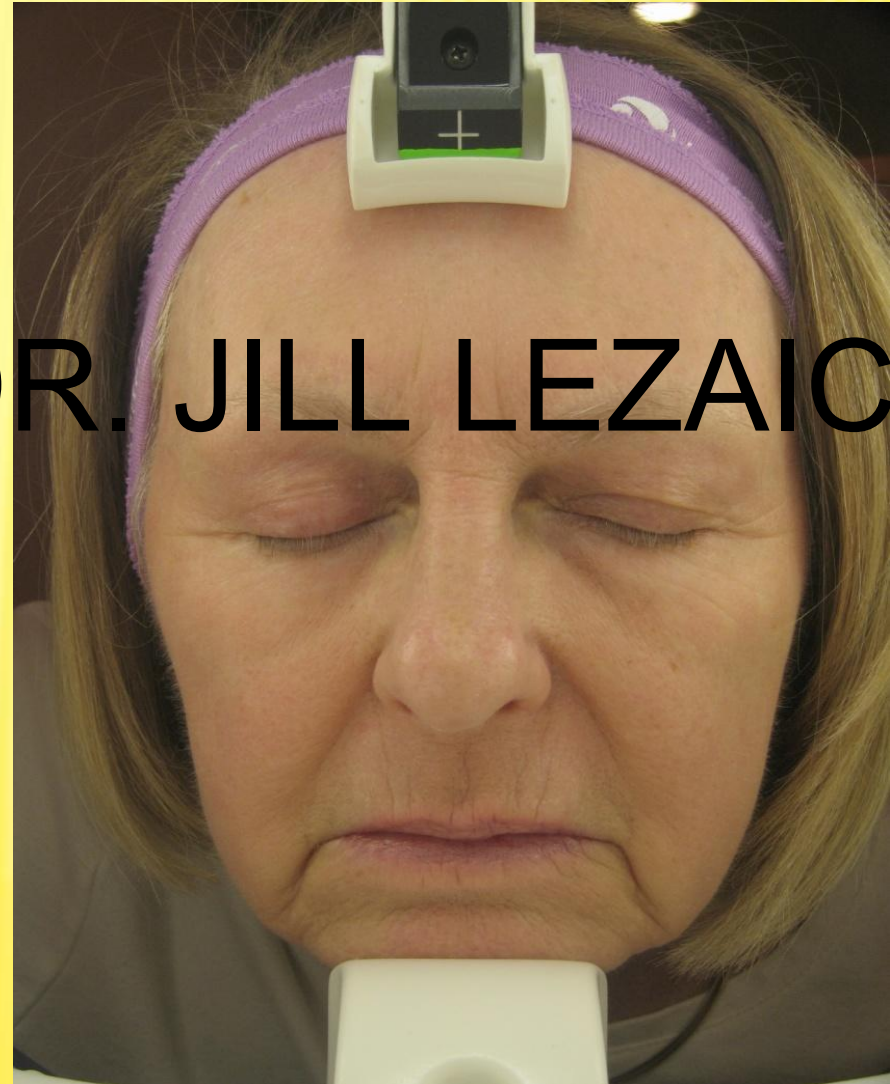

PROPERTY OF DR. JILL LEZAIC

PEARL FRACTIONAL

✘ Before

✘ 4 weeks after 1 treatment

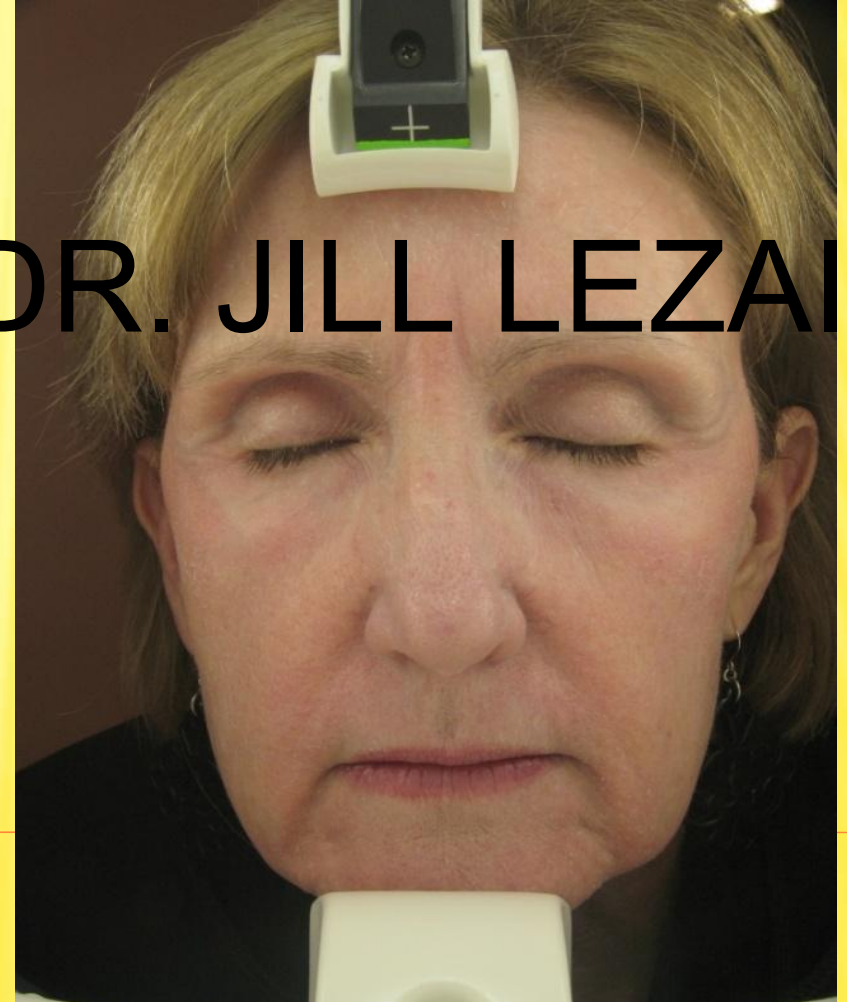
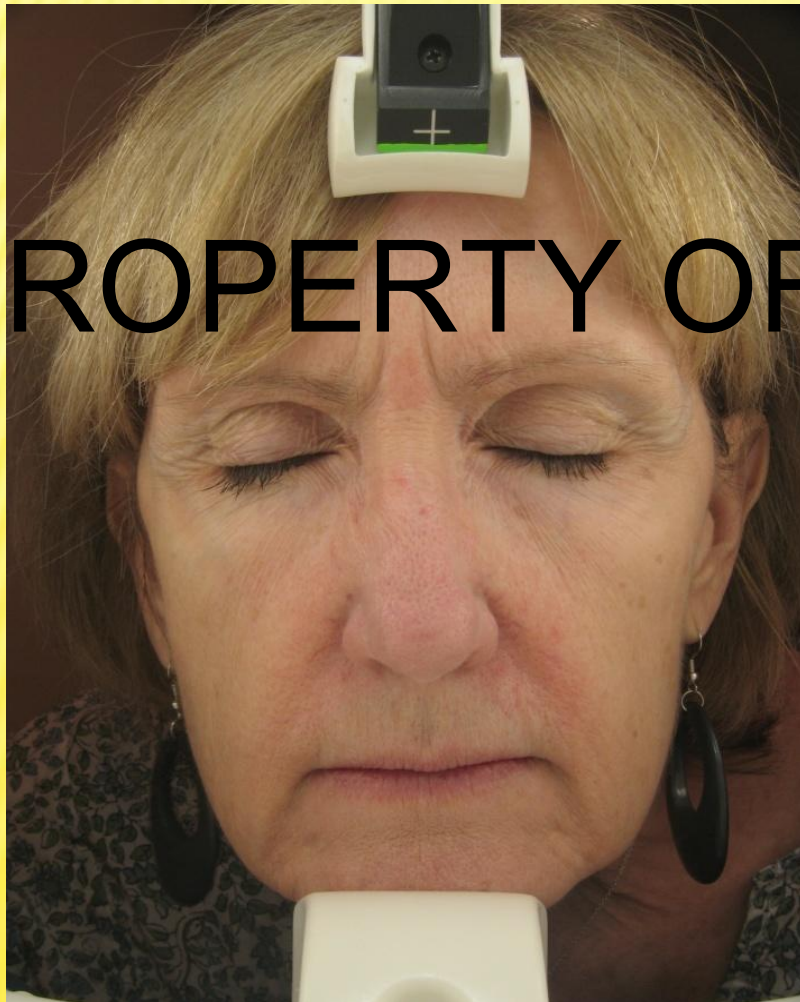
PROPERTY OF DR. JILL LEZAIC

PEARL FULL FACE & PEARL FRACTIONAL AROUND THE EYES & MOUTH

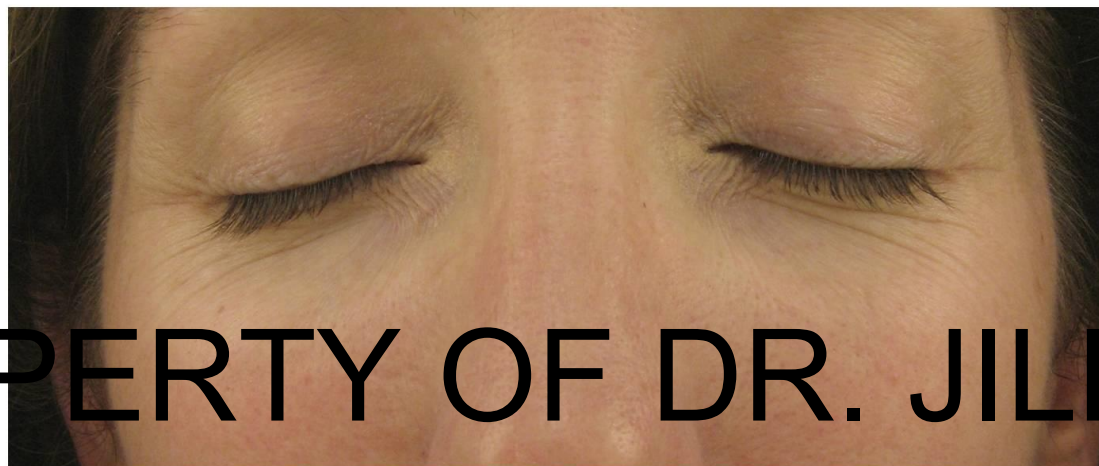BEFORE

4 WEEKS AFTER 1 TREATMENT

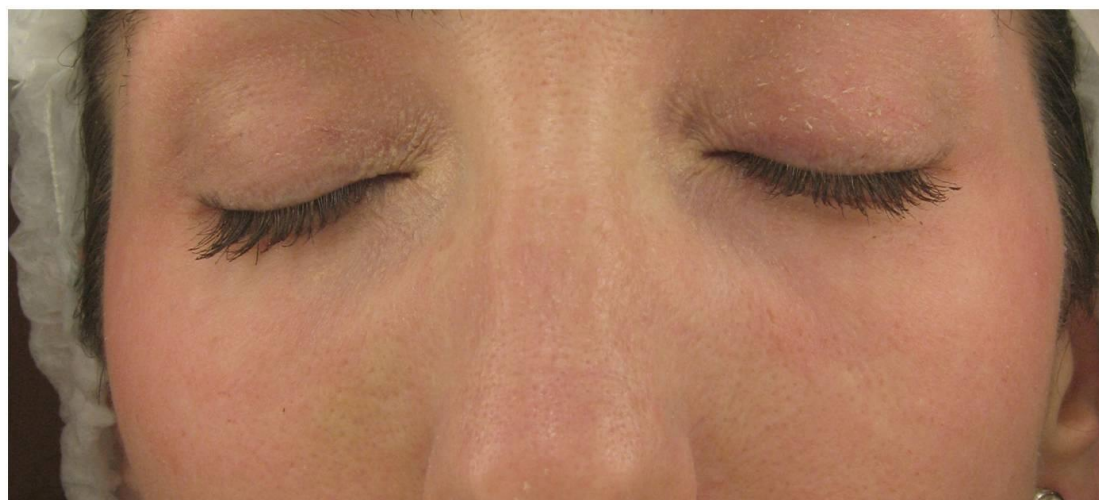

PROPERTY OF DR. JILL LEZAIC

PEARL FRACTIONAL



PROPERTY OF DR. JILL LEZAIC



PEARL FUSION – THE IDEAL SOLUTION

A Cutera Aesthetic Seminar

✘ Pearl

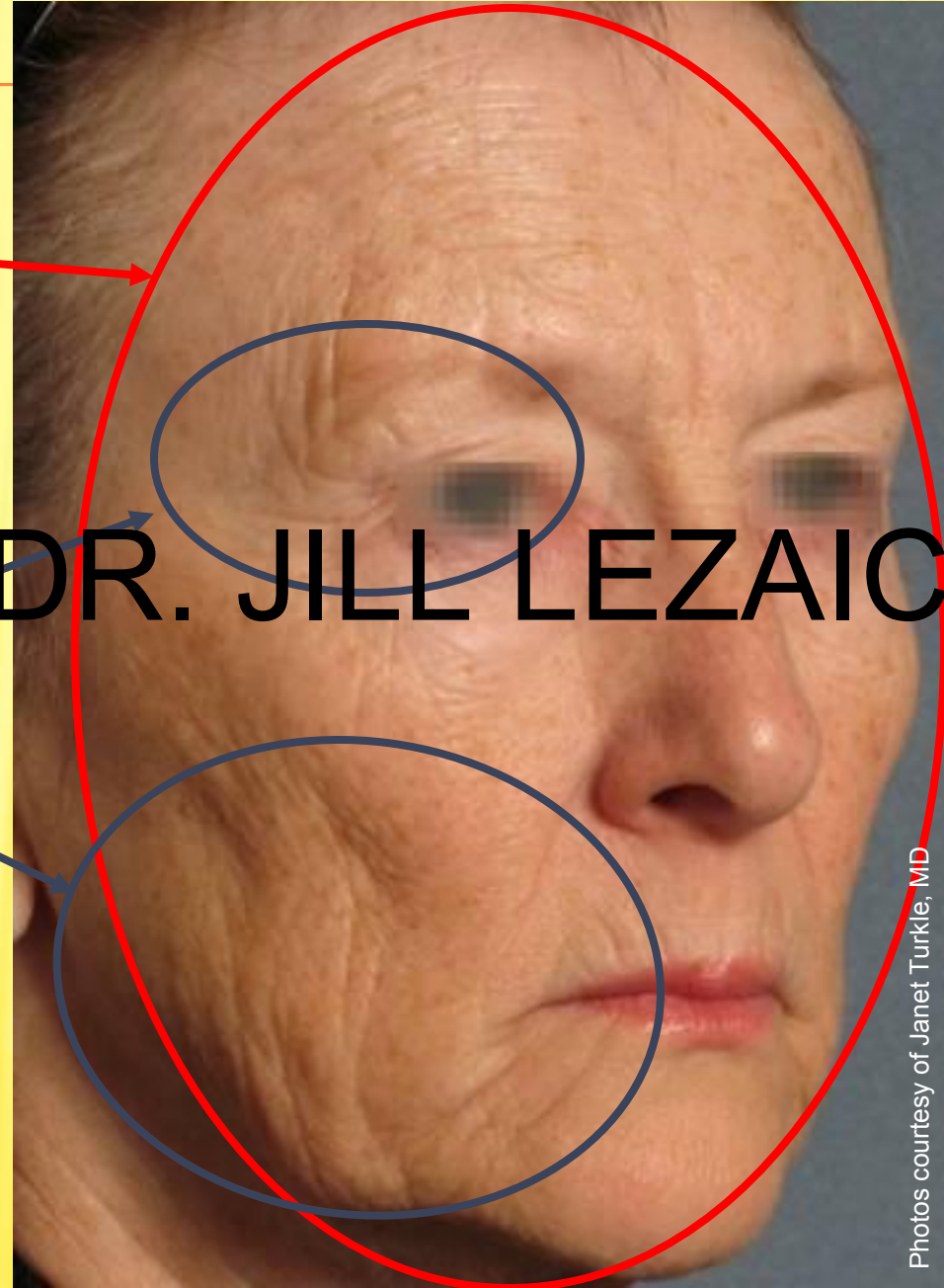- + Full coverage
- + Skin quality & texture
- + Pore size
- + Pigment

✘ Pearl Fractional

- + Focal areas of significant photo-damage

✘ Single Treatment

PROPERTY OF DR. JILL LEZAIO

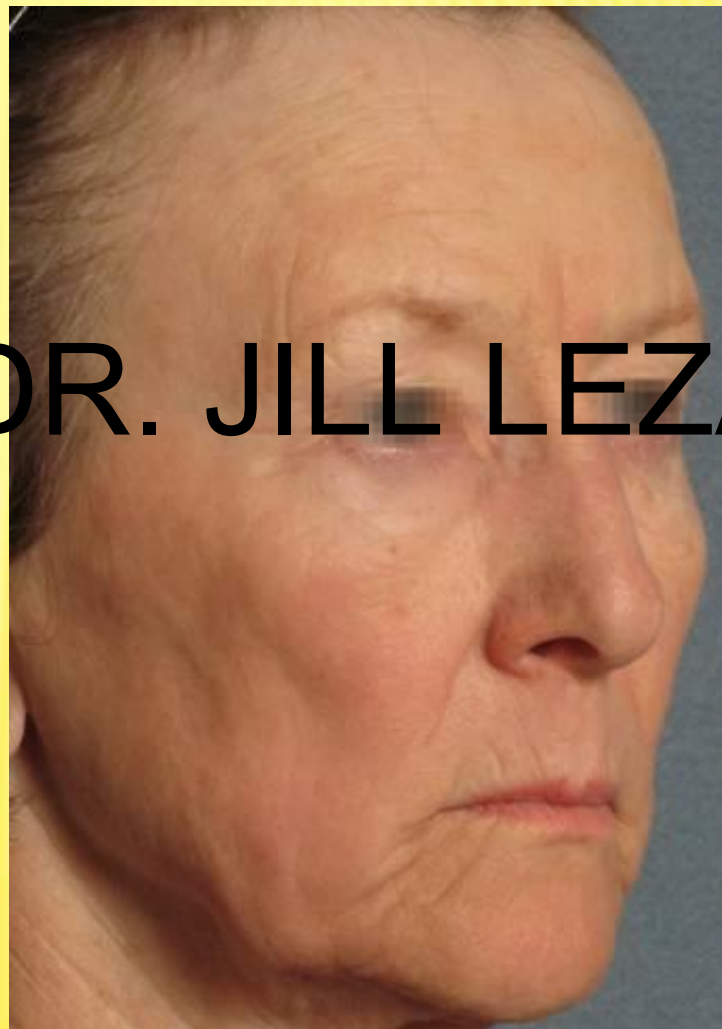

Pearl Fusion

Combination Pearl and Pearl Fractional

Pre Tx

6 Weeks Post, 1 Tx



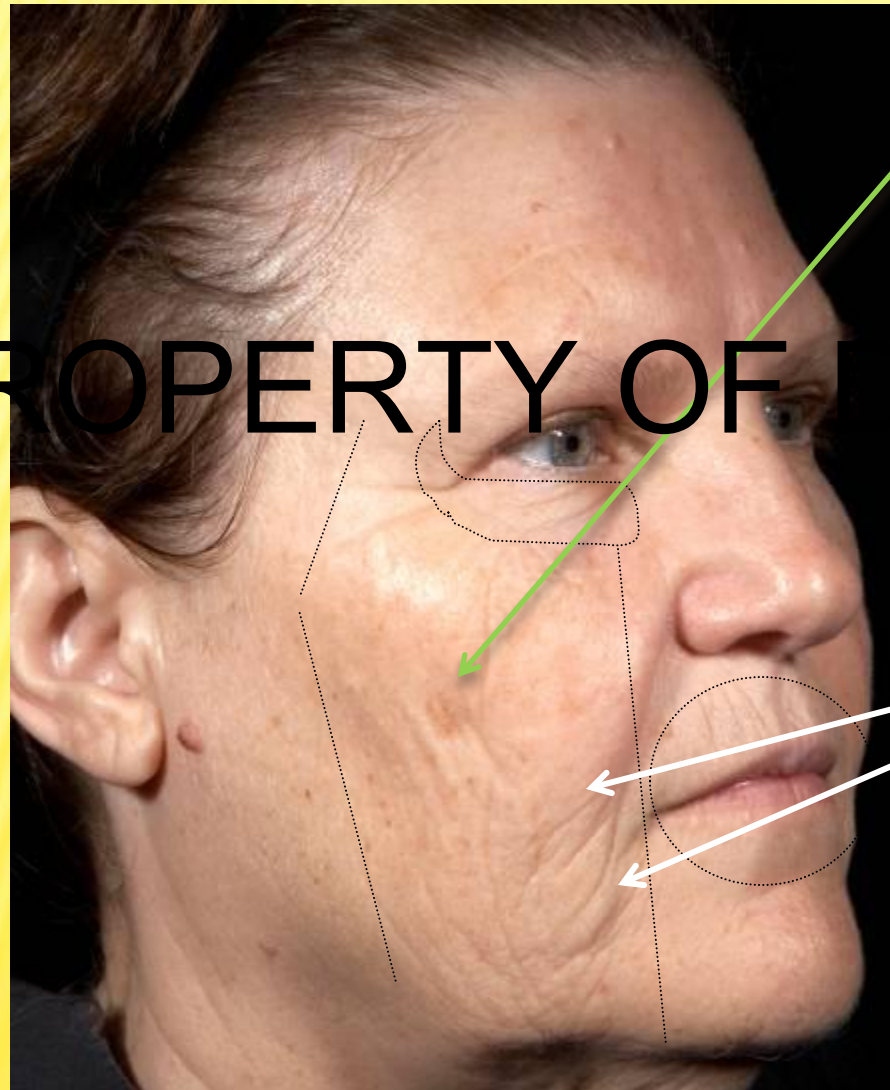
PROPERTY OF DR. JILL LEZAIC

Photos courtesy of Janet Turkle, MD

Full Face Pearl 3.5 J/cm². Pearl Fractional 160 mJ, density 3, two passes on cheeks & perioral area. Periorcular, 120 mJ, 1st pass density 2, 2nd pass density 1

Pearl Fusion

Fitzpatrick Wrinkle Score: 8



✗ Pearl

- + Full face, except periorbital

- + For solar lentigenes & other dyschromia

- + Single pass, 3.5J/cm², 0.4ms, 20% overlap

✗ Pearl Fractional

- + Cheeks, periorbital, perioral (no lids)

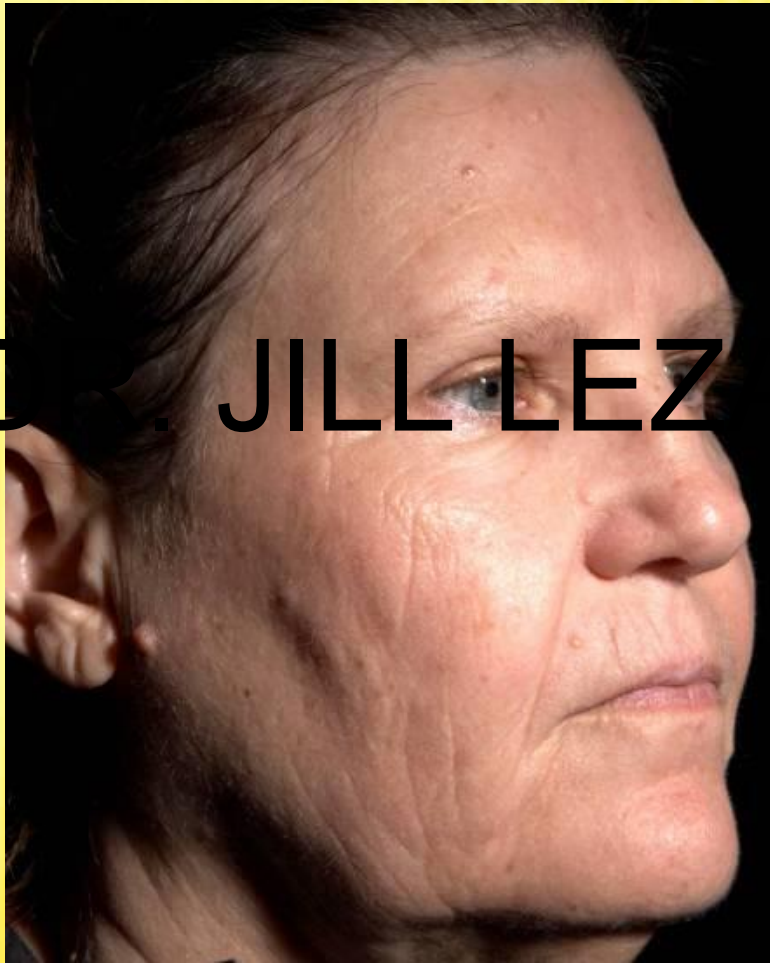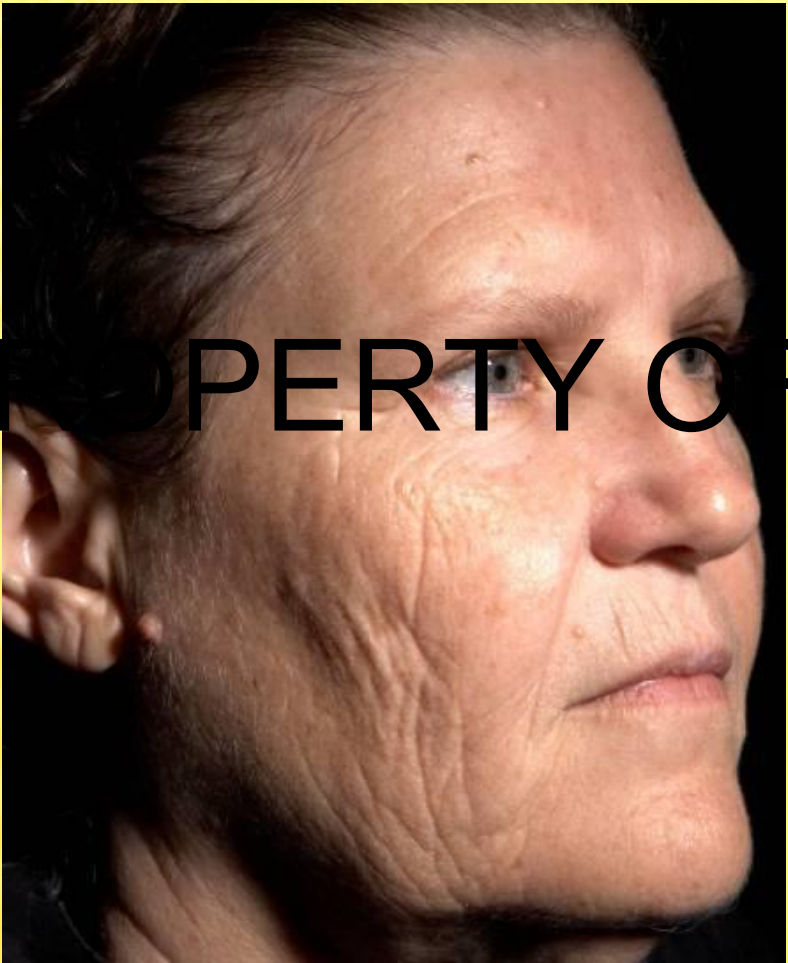
- + 160 mJ with density 2, 2 passes

PROPERTY OF DR. JILL LEZAIC

Pearl Fusion
Combination Pearl and Pearl Fractional

Pre Tx

6 Weeks Post, 1 Tx



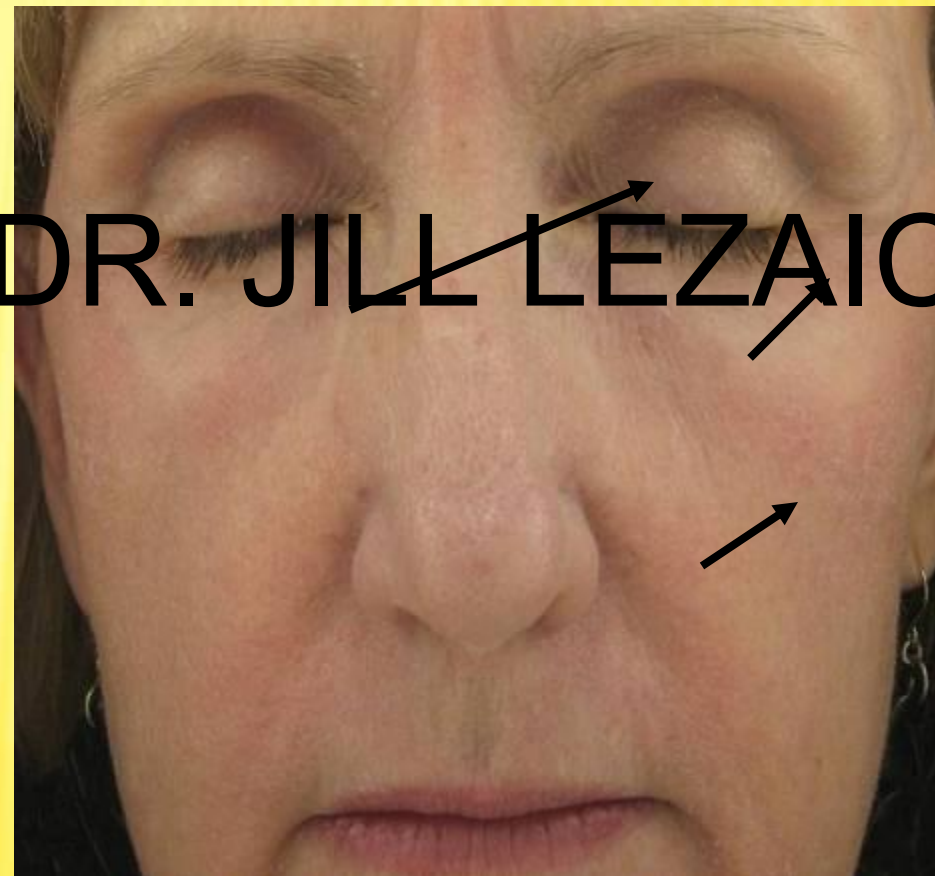PROPERTY OF DR. JILL LEZAK

Pearl 3.5 J/cm², 0.4ms, 20% overlap, 1 pass, full face save perioral area. Pearl Fractional 160 mJ, density 2, two passes on cheeks, periorbital (no upper lid) & perioral area. Photos courtesy of Adele Makow, MD

PEARL FUSION COMBINATION PEARL AND PEARL FRACTIONAL

Before

5 weeks Post 1 Tx

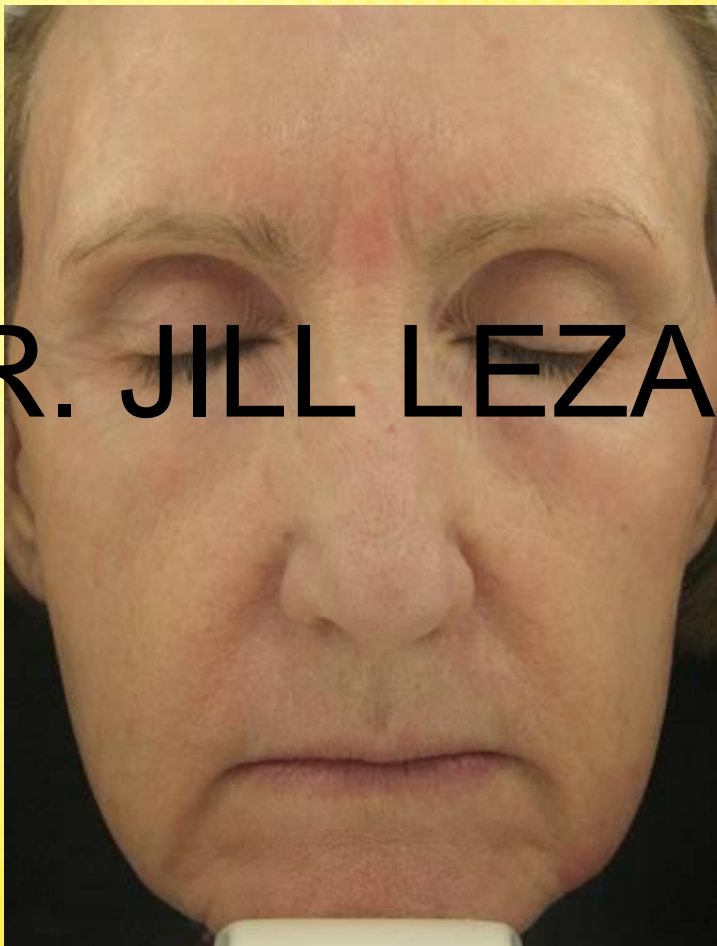

PROPERTY OF DR. JILL LEZAIC

Pearl 3.2 J/cm², 0.4ms, 20% overlap, 1 pass, full face. Pearl Fractional 160 mJ, 2 passes density 2, 3rd pass at density 2 in periorcular area. Photos courtesy of Jill Lezaic, DO

Pearl Fusion
Combination Pearl and Pearl Fractional
Pre Tx

5 Weeks Post, 1 Tx



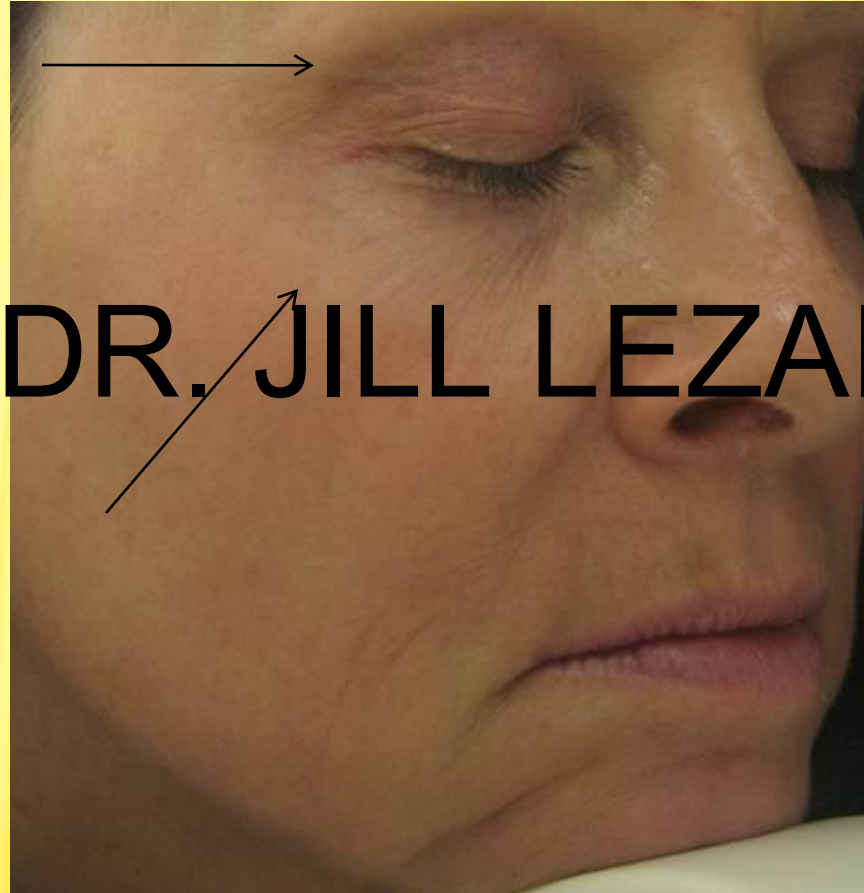PROPERTY OF DR. JILL LEZAIC

Pearl 3.2 J/cm², 0.4ms, 20% overlap, 1 pass, full face. Pearl Fractional 160 mJ, 2 passes density 2, 3rd pass at density 2 in periorcular area. Photos courtesy of Jill Lezaic, DO

Pearl Fusion
Combination Pearl and Pearl Fractional

Pre Tx

12 Weeks Post, 1 Tx



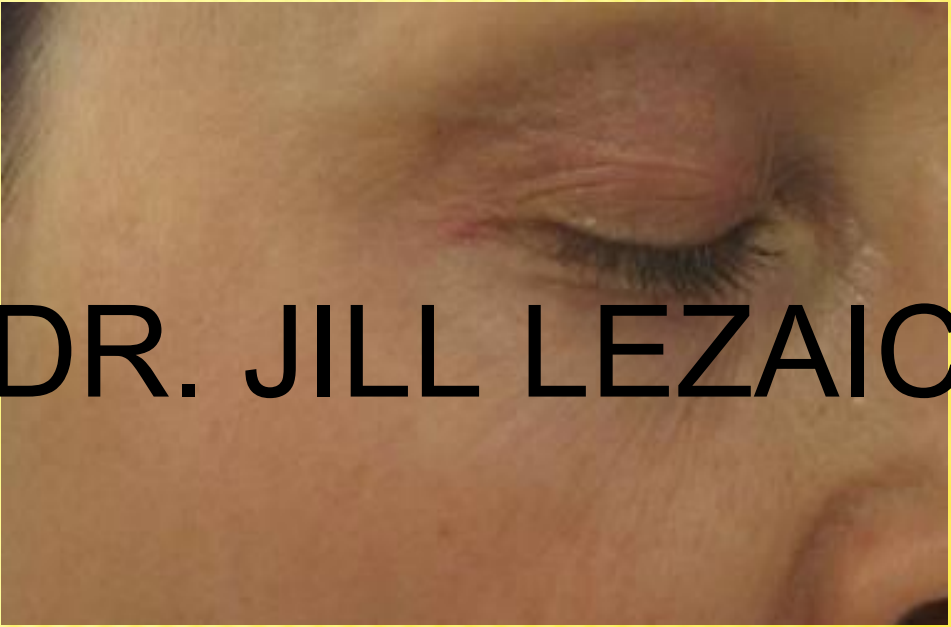PROPERTY OF DR. JILL LEZAIC

Pearl 3.0 J/cm², 0.4ms, 20% overlap, 1 pass, full face.
Pearl Fractional 120 mJ, density 2, 3 passes in periocular area. 160 mJ forehead & cheeks, density 2, 2 passes.
Upper lip 160 mJ/ density 3, 3 passes. Chin 160 mJ, density 2, 4 passes. Photos courtesy of Jill Lezaic, DO

Pearl Fusion
Combination Pearl and Pearl Fractional

Pre Tx

12 Weeks Post, 1 Tx




PROPERTY OF DR. JILL LEZAIC

Pearl 3.0 J/cm², 0.4ms, 20% overlap, 1 pass, full face.
Pearl Fractional 120 mJ, density 2, 3 passes in periocular area. 160 mJ forehead & cheeks, density 2, 2 passes.
Upper lip 160 mJ/ density 3, 3 passes. Chin 160 mJ, density 2, 4 passes. Photos courtesy of Jill Lezaic, DO

Pearl Fusion
Combination Pearl and Pearl Fractional

Pre Tx

12 Weeks Post, 1 Tx

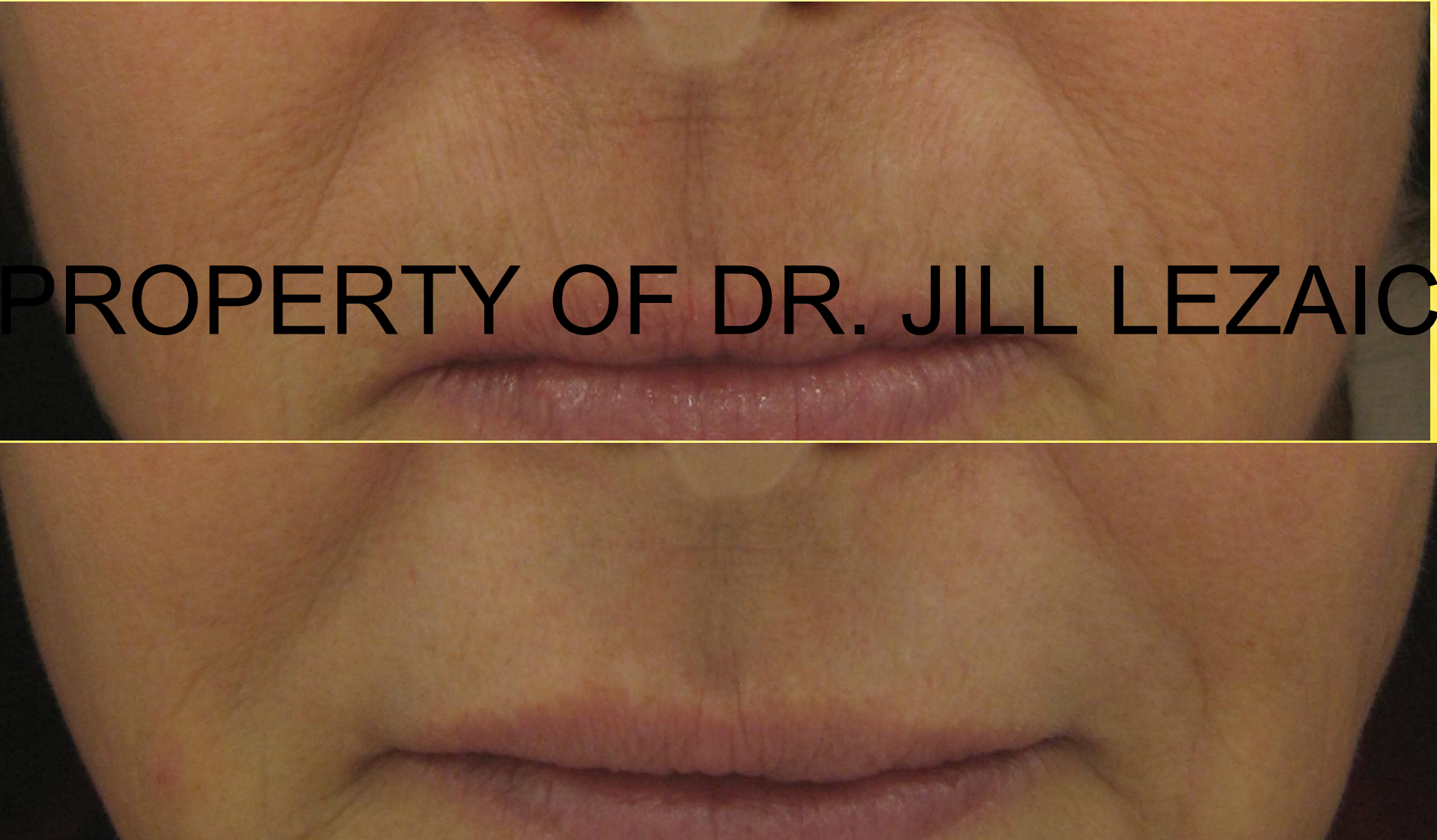

PROPERTY OF DR. JILL LEZAIC

Pearl 3.0 J/cm², 0.4ms, 20% overlap, 1 pass, full face.
Pearl Fractional 120 mJ, density 2, 3 passes in periocular area. 160 mJ forehead & cheeks, density 2, 2 passes.
Upper lip 160 mJ/ density 3, 3 passes. Chin 160 mJ, density 2, 4 passes. Photos courtesy of Jill Lezaic, DO

PEARL FUSION, FILLER IN LIPS, PERIORAL LINES & NLFS

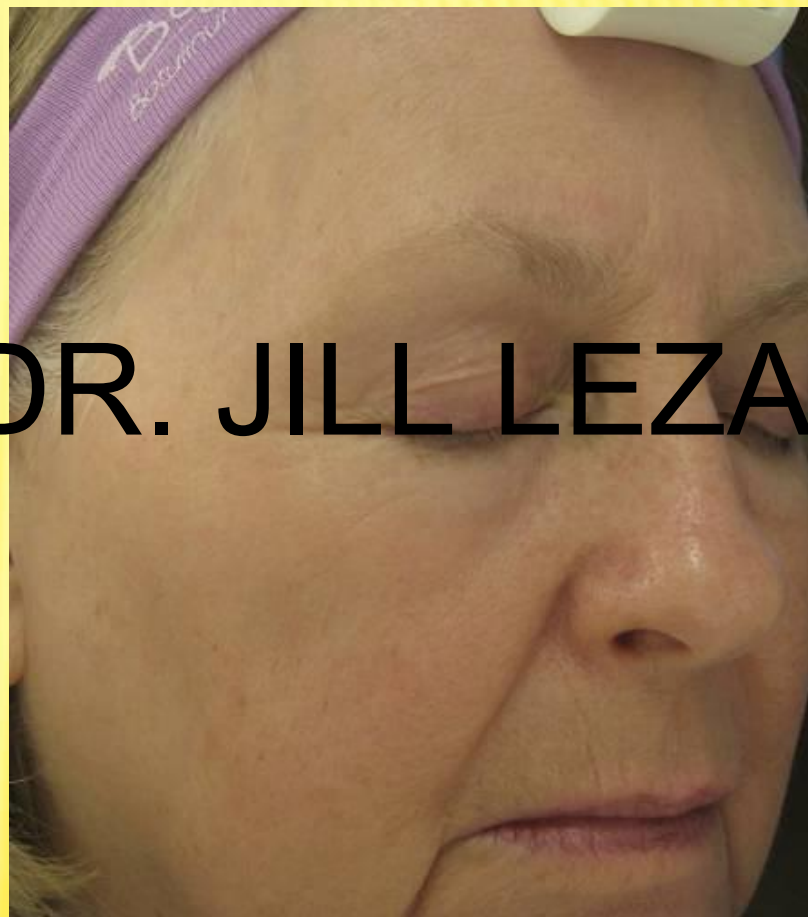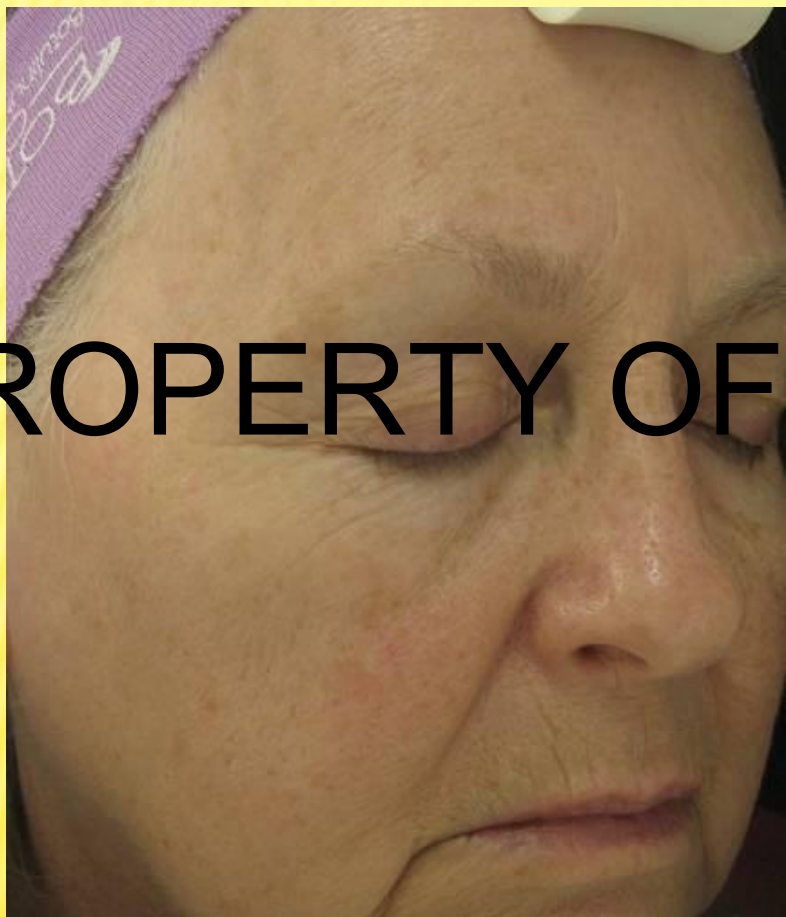PROPERTY OF DR. JILL LEZAIC



Pearl Fusion
Combination Pearl and Pearl Fractional

Pre Tx

13 Weeks Post, 1 Tx



PROPERTY OF DR. JILL LEZAIC

Pearl 3.2 J/cm², 0.4ms, 20% overlap, 1 pass, eyelids, 3.5 J/cm², eyelids, 1 pass.
Pearl Fractional 160 mJ full face. Forehead density 2, 2 passes.

Remainder of face and periocular area density 3, 3 passes plus density 1, 1 pass. Photos courtesy of Jill Lezaic, DO

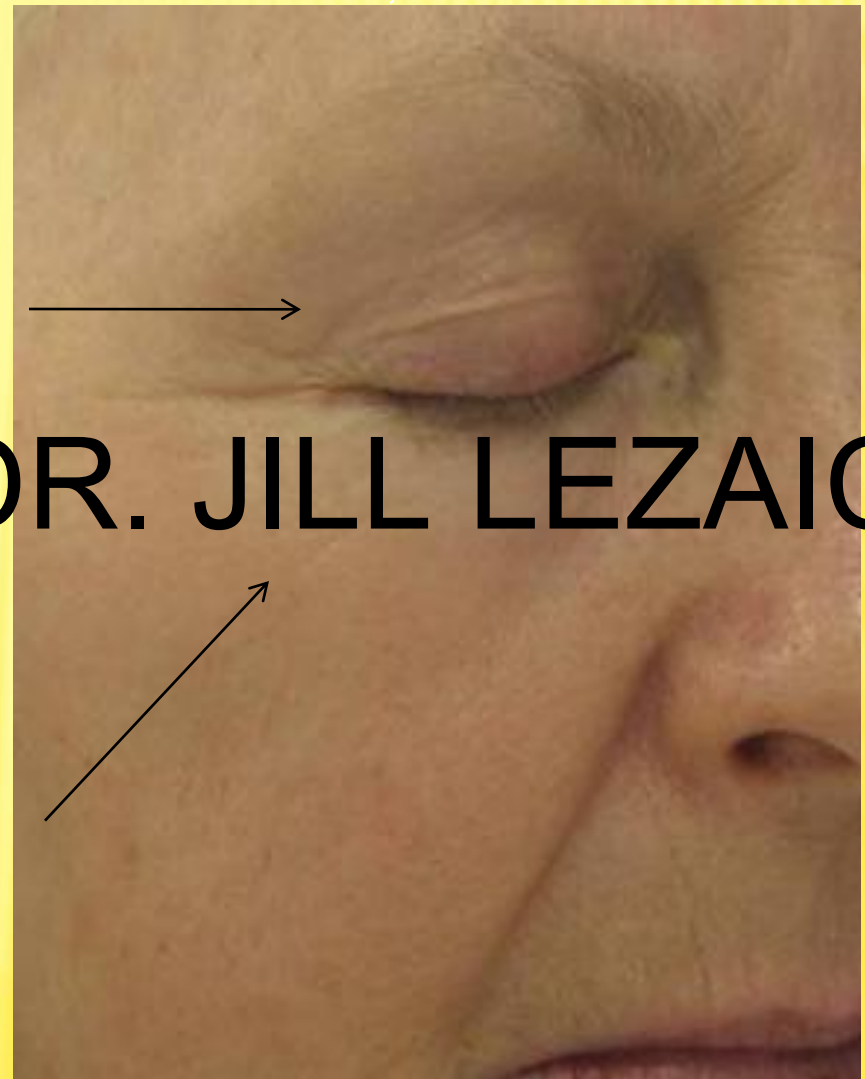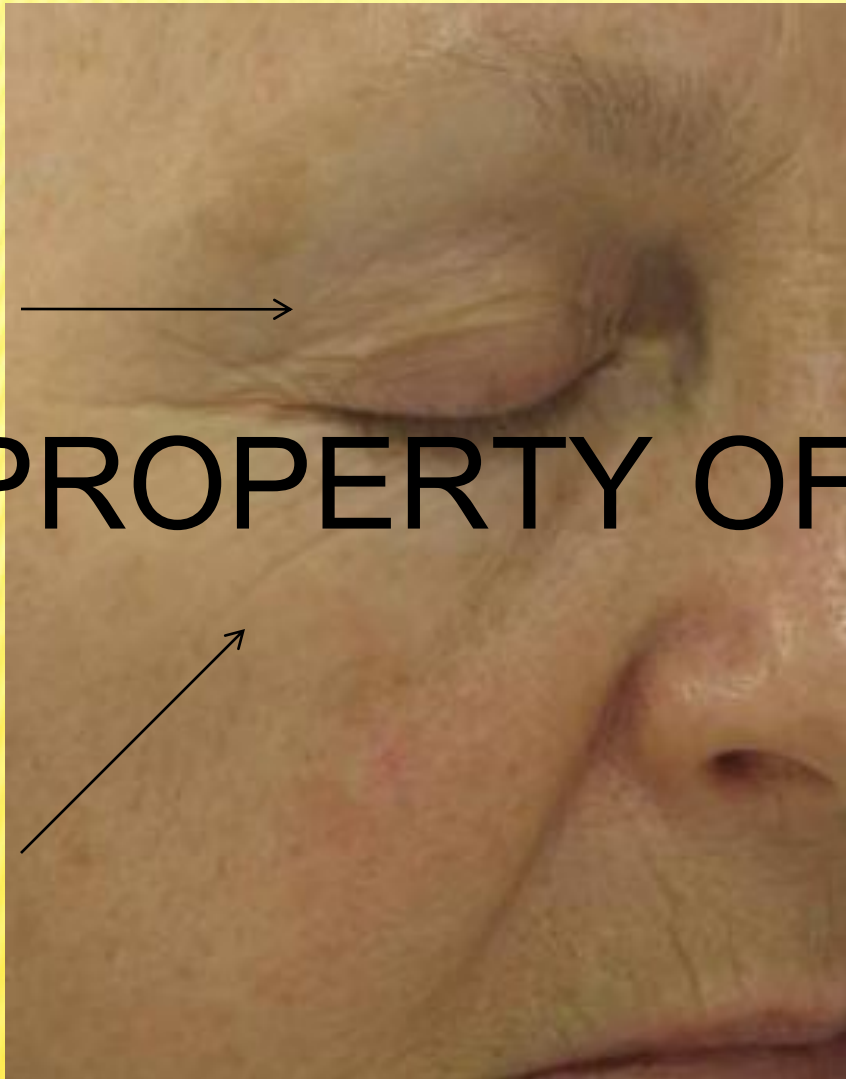Pearl Fusion

A Cutera Aesthetic Seminar

Combination Pearl and Pearl Fractional

Pre Tx

13 Weeks Post, 1 Tx



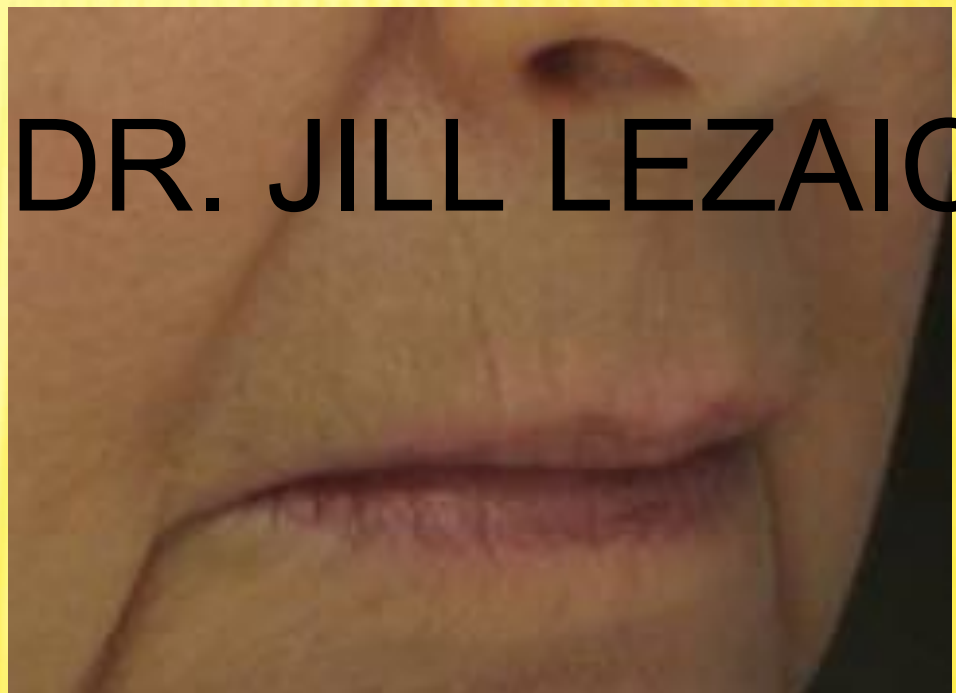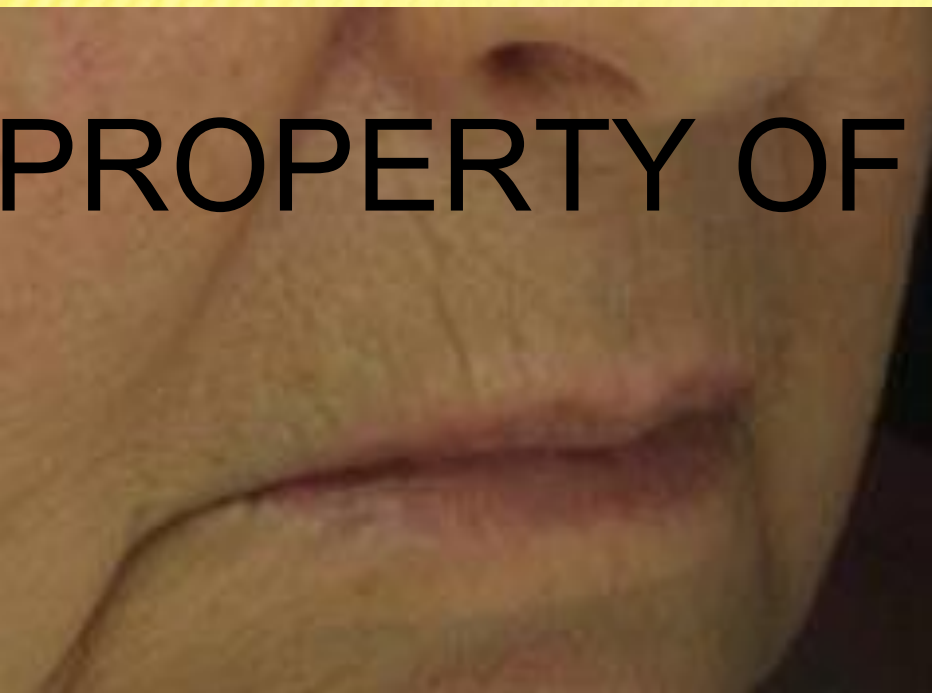PROPERTY OF DR. JILL LEZAIC

Pearl 3.2 J/cm², 0.4ms, 20% overlap, 1 pass, eyelids, 3.5 J/cm², eyelids, 1 pass. Pearl Fractional 160 mJ full face. Forehead density 2, 2 passes. Remainder of face and periorcular area density 3, 3 passes plus density 1, 1 pass. Photos courtesy of Jill Lezaic, DO

Pearl Fusion
Combination Pearl and Pearl Fractional

Pre Tx

13 Weeks Post, 1 Tx



PROPERTY OF DR. JILL LEZAIC

Pearl 3.2 J/cm², 0.4ms, 20% overlap, 1 pass, eyelids, 3.5 J/cm², eyelids, 1 pass.
Pearl Fractional 160 mJ full face. Forehead density 2, 2 passes.

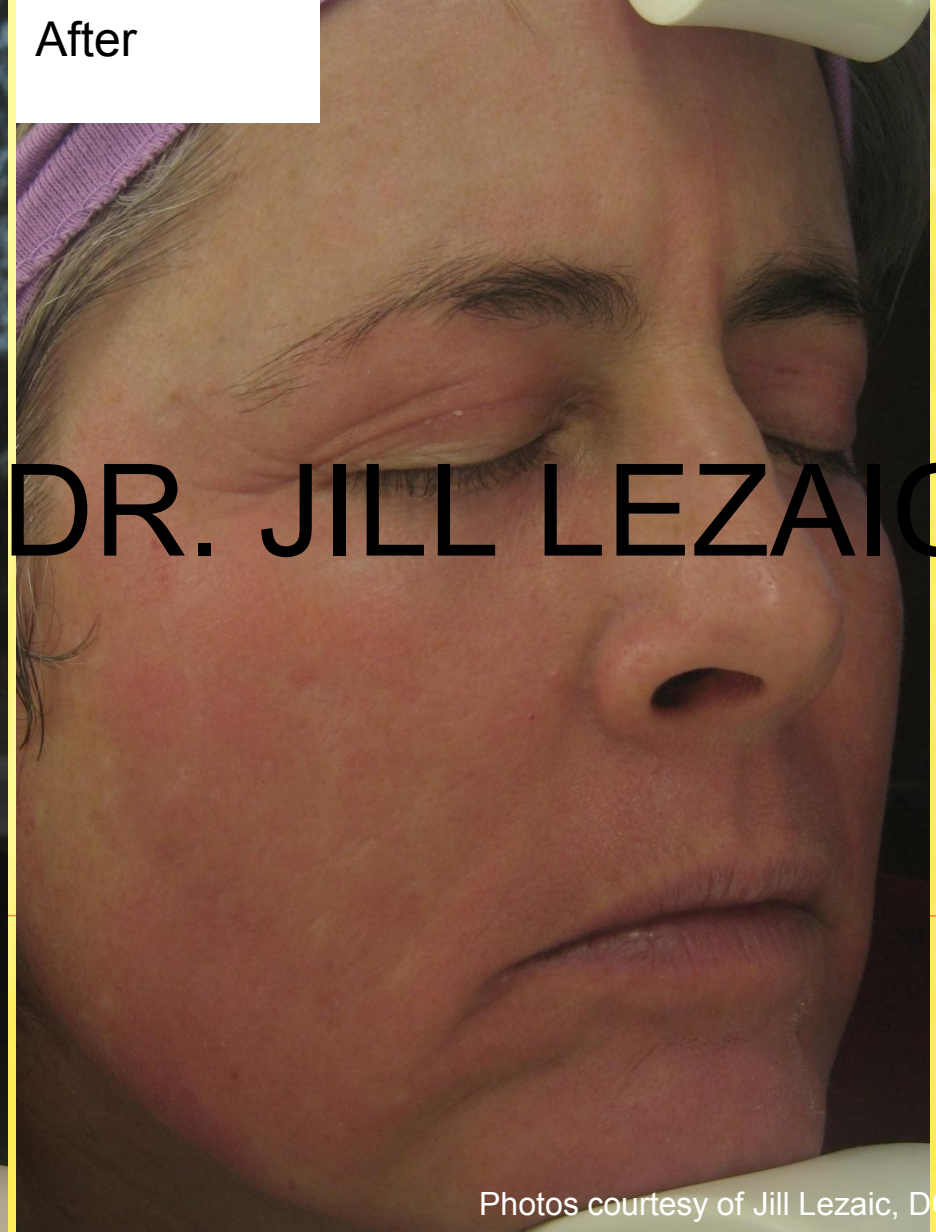
Remainder of face and periocular area density 3, 3 passes plus density 1, 1 pass. Photos courtesy of Jill Lezaic, DO

21 DAYS AFTER PEARL FUSION

Before



After



PROPERTY OF DR. JILL LEZAIC

28 DAYS AFTER PEARL FUSION

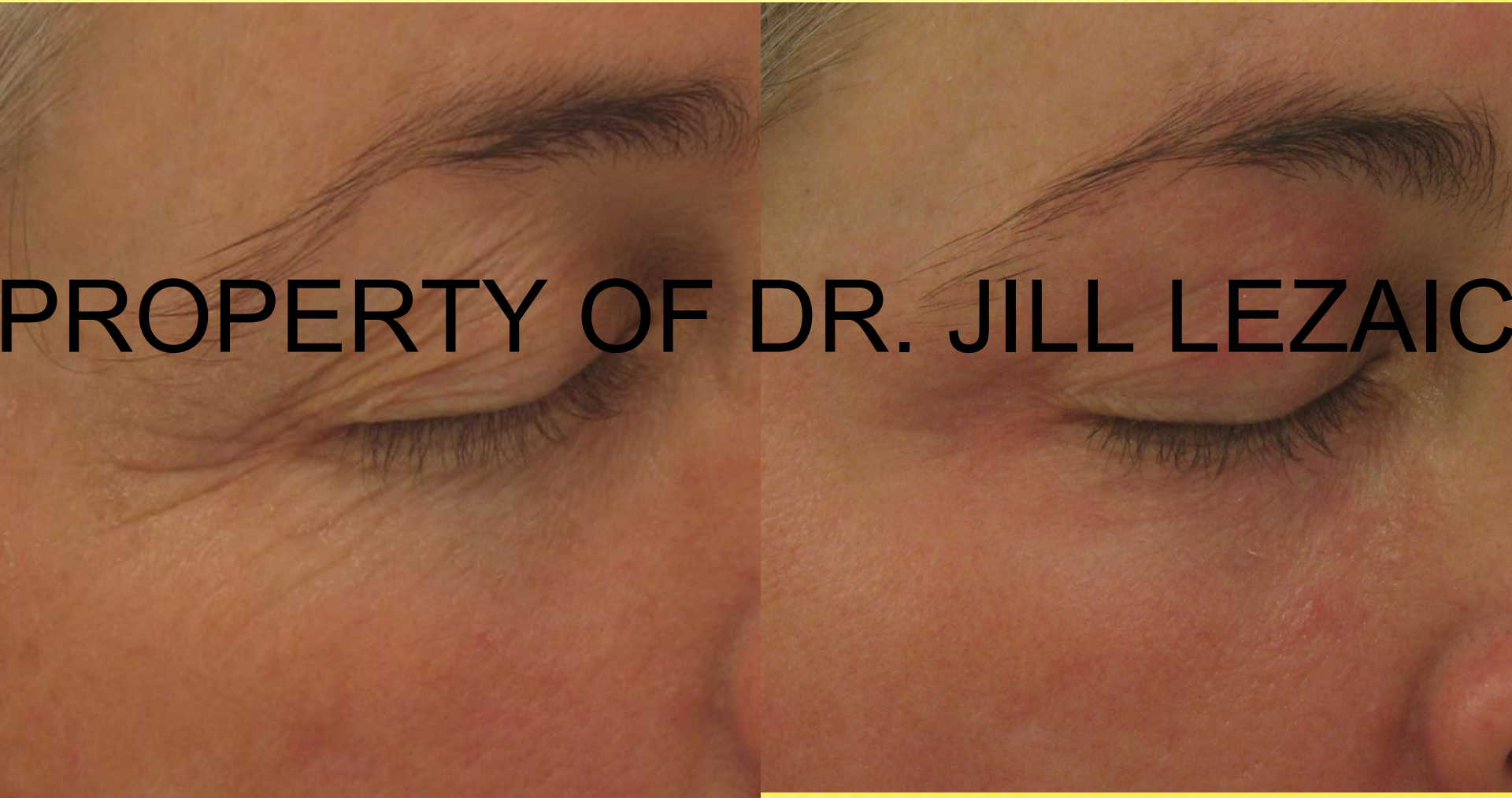A Cutera Aesthetic Seminar

PROPERTY OF DR. JILL LEZAIC



28 DAYS AFTER PEARL FUSION

A Cutera Aesthetic Seminar

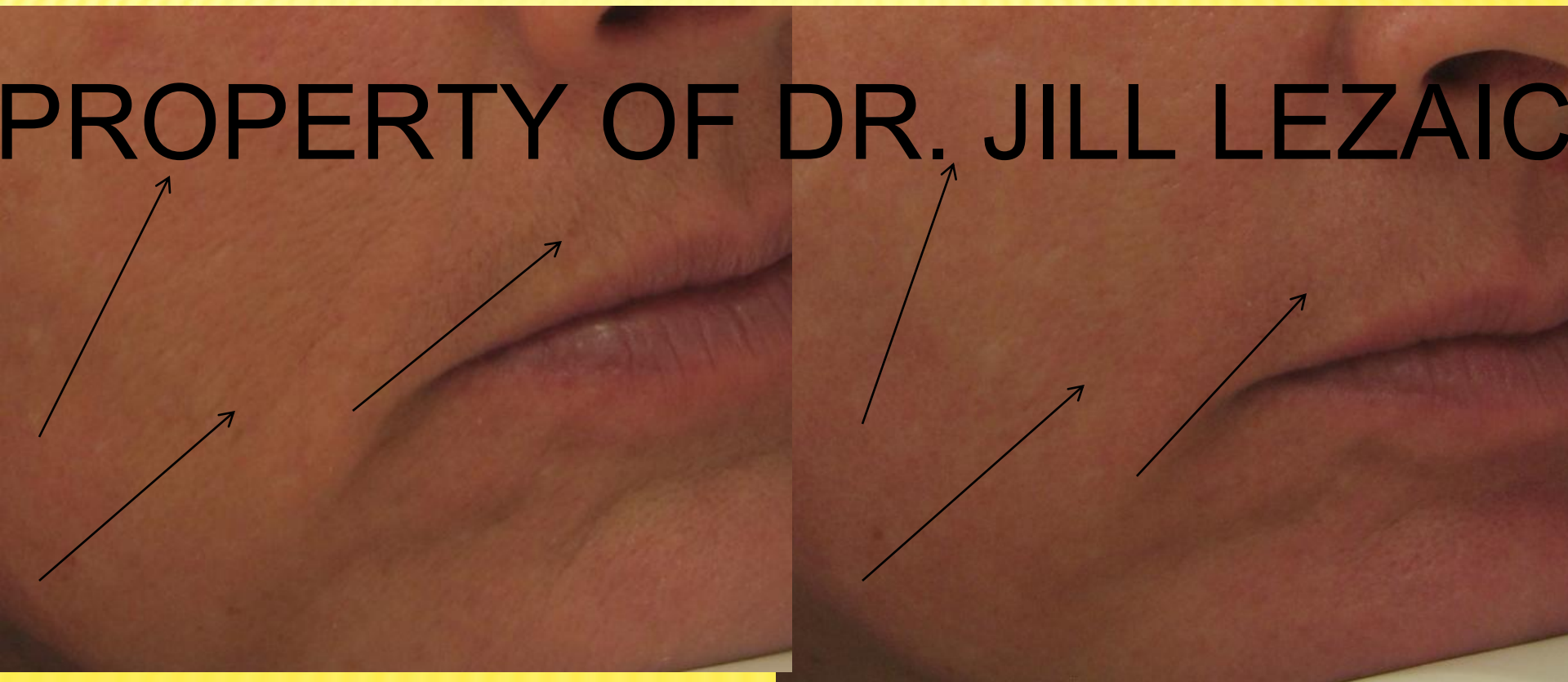

PROPERTY OF DR. JILL LEZAIC

28 DAYS AFTER PEARL FUSION

A Cutera Aesthetic Seminar


PROPERTY OF DR. JILL LEZAIC



Pearl Fusion
Combination Pearl and Pearl Fractional

Pre Tx

4 Weeks Post, 1 Tx



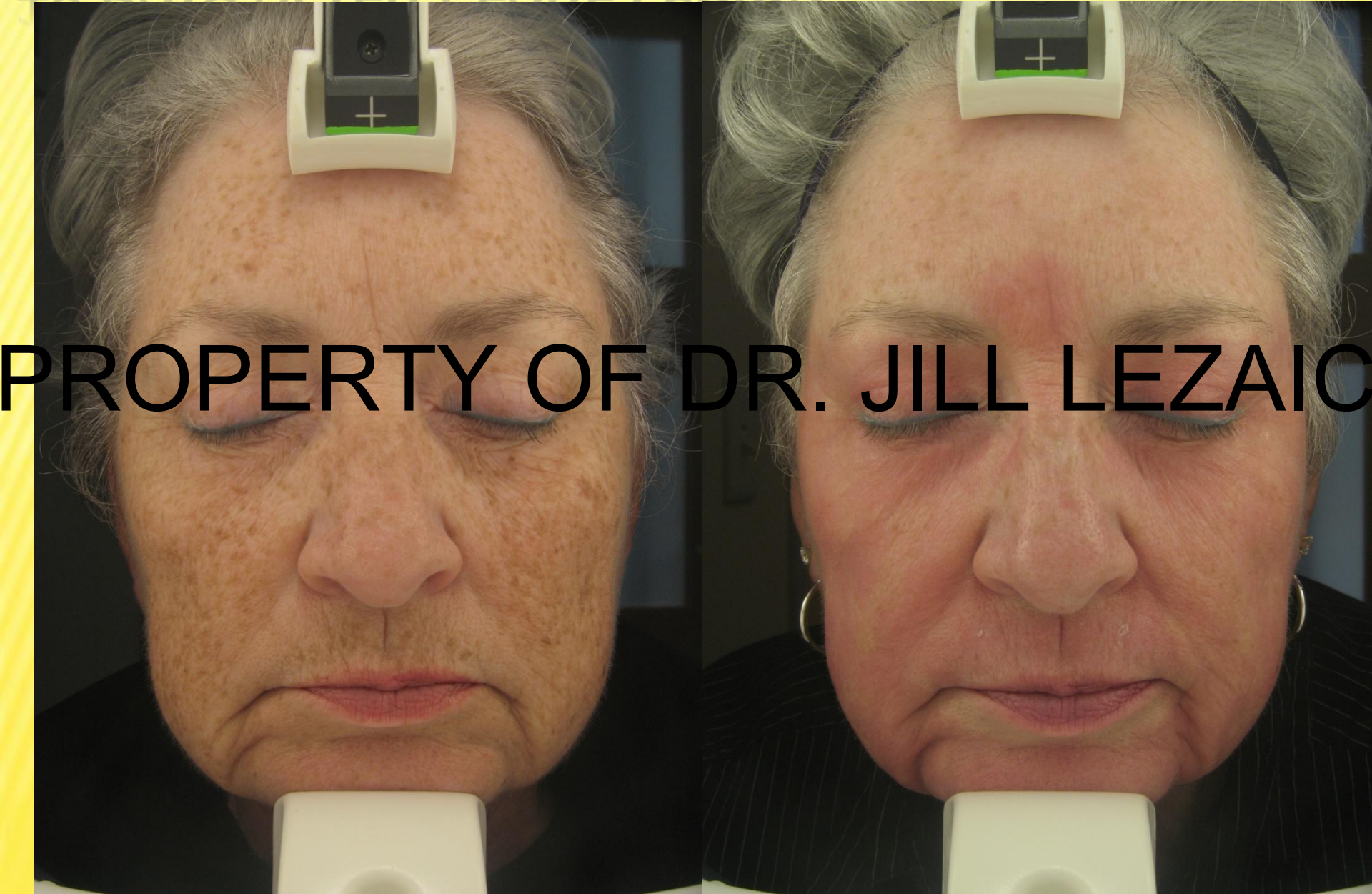PROPERTY OF DR. JILL LEZAIC

Pearl 3.2 J/cm², 0.4ms, 20% overlap, 1 pass, full face. Pearl Fractional 160 mJ, 2 passes density 2, 1 pass density 1. Photos courtesy of Jill Lezaic, DO

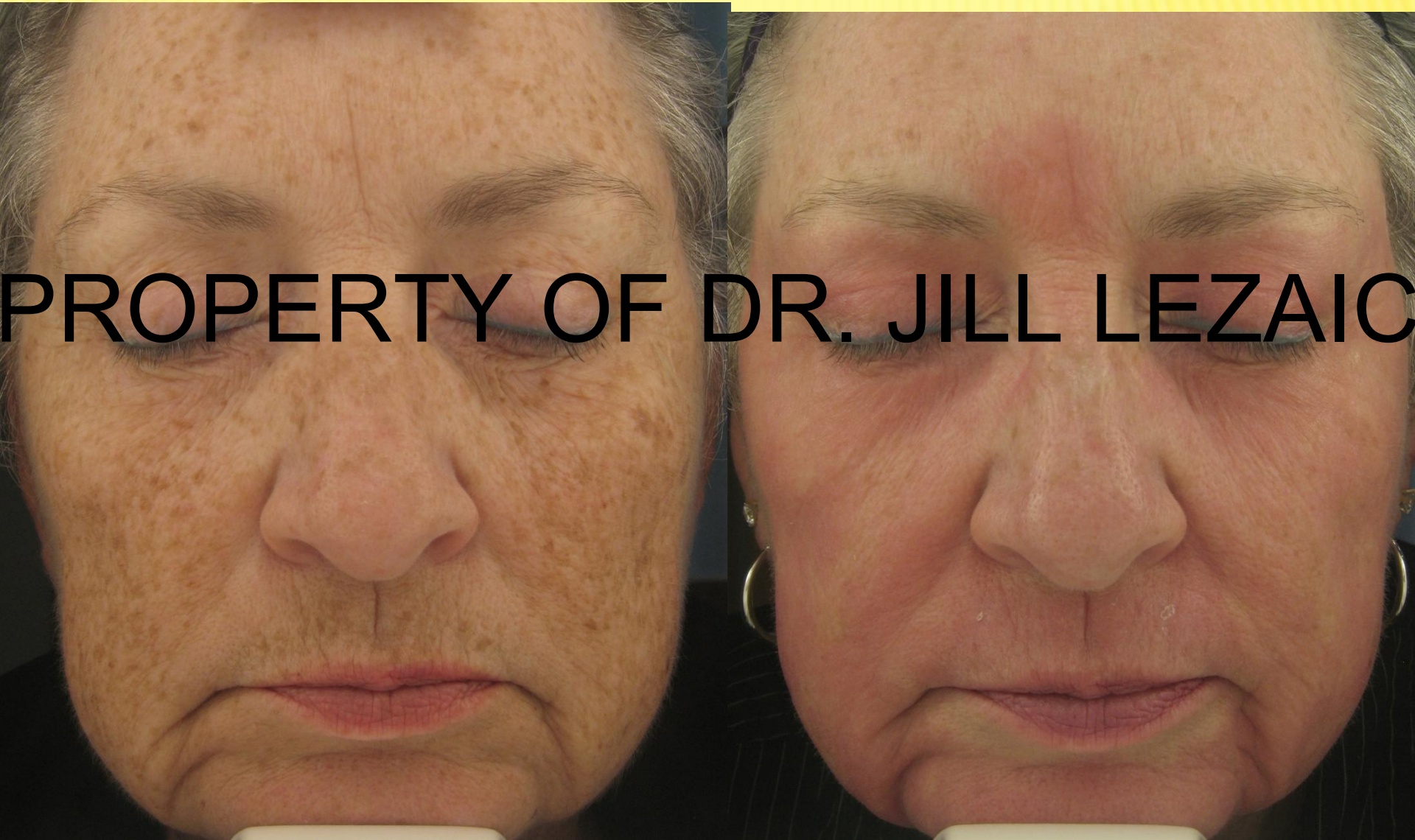1 YEAR AFTER 1 PEARL

A Cutera Aesthetic Seminar

10 DAYS AFTER PEARL FUSION



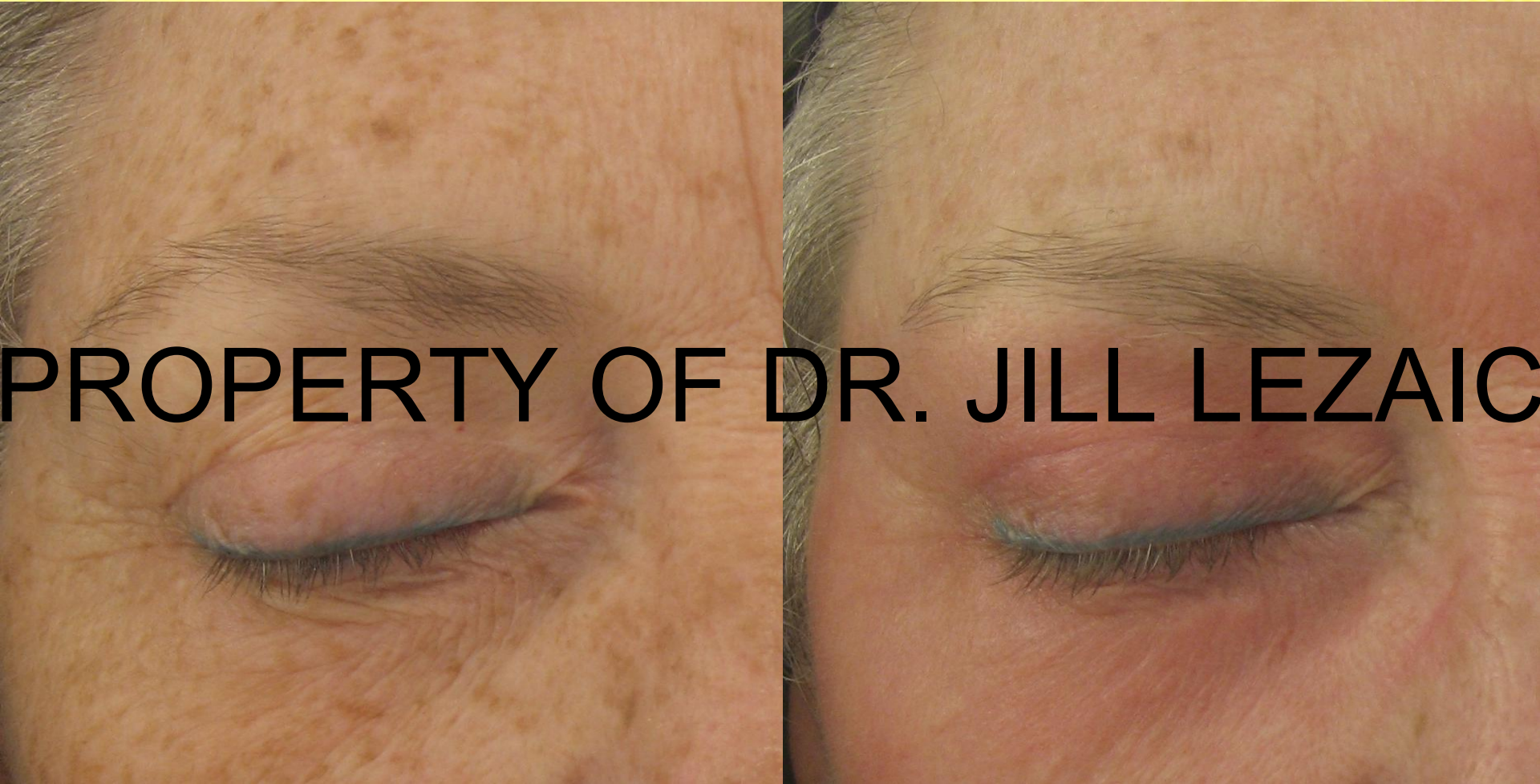PROPERTY OF DR. JILL LEZAIC



PROPERTY OF DR. JILL LEZAIC

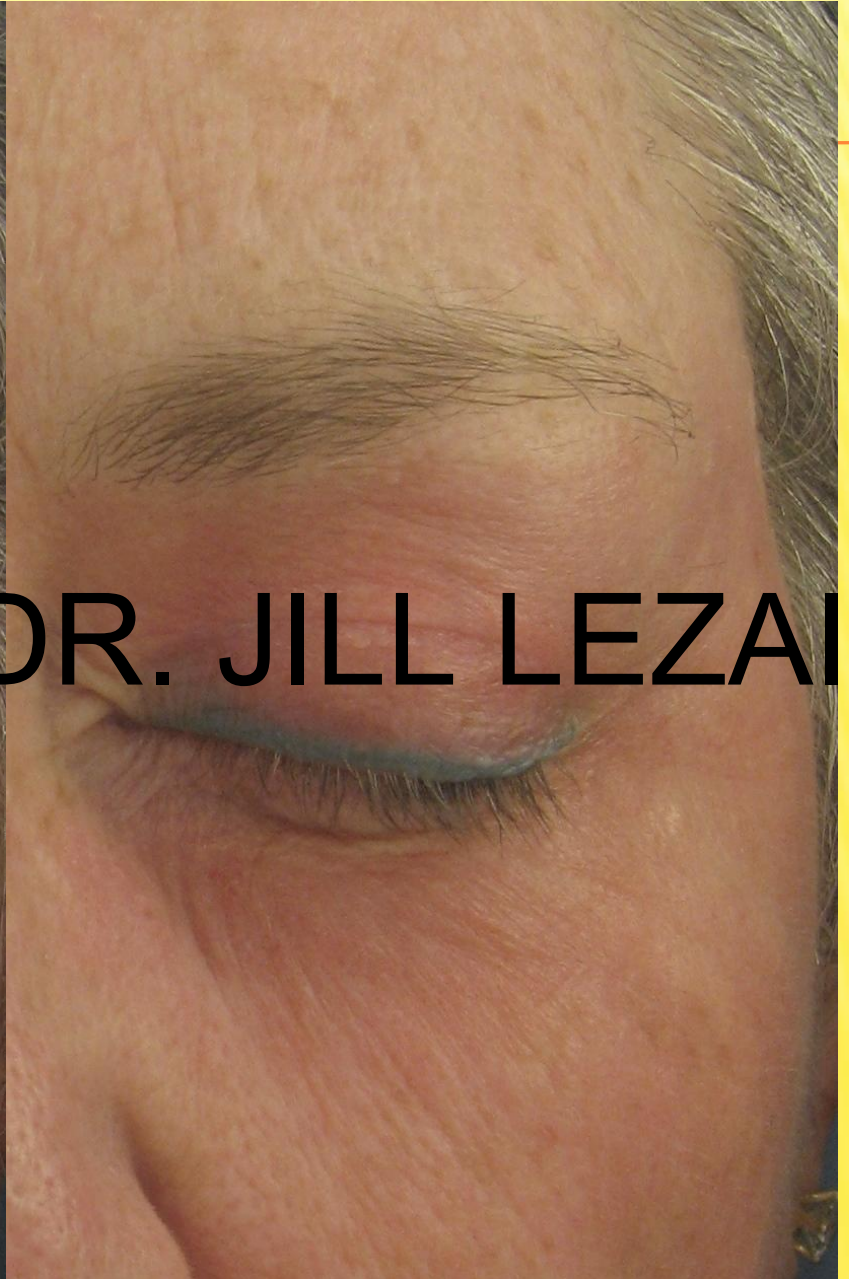
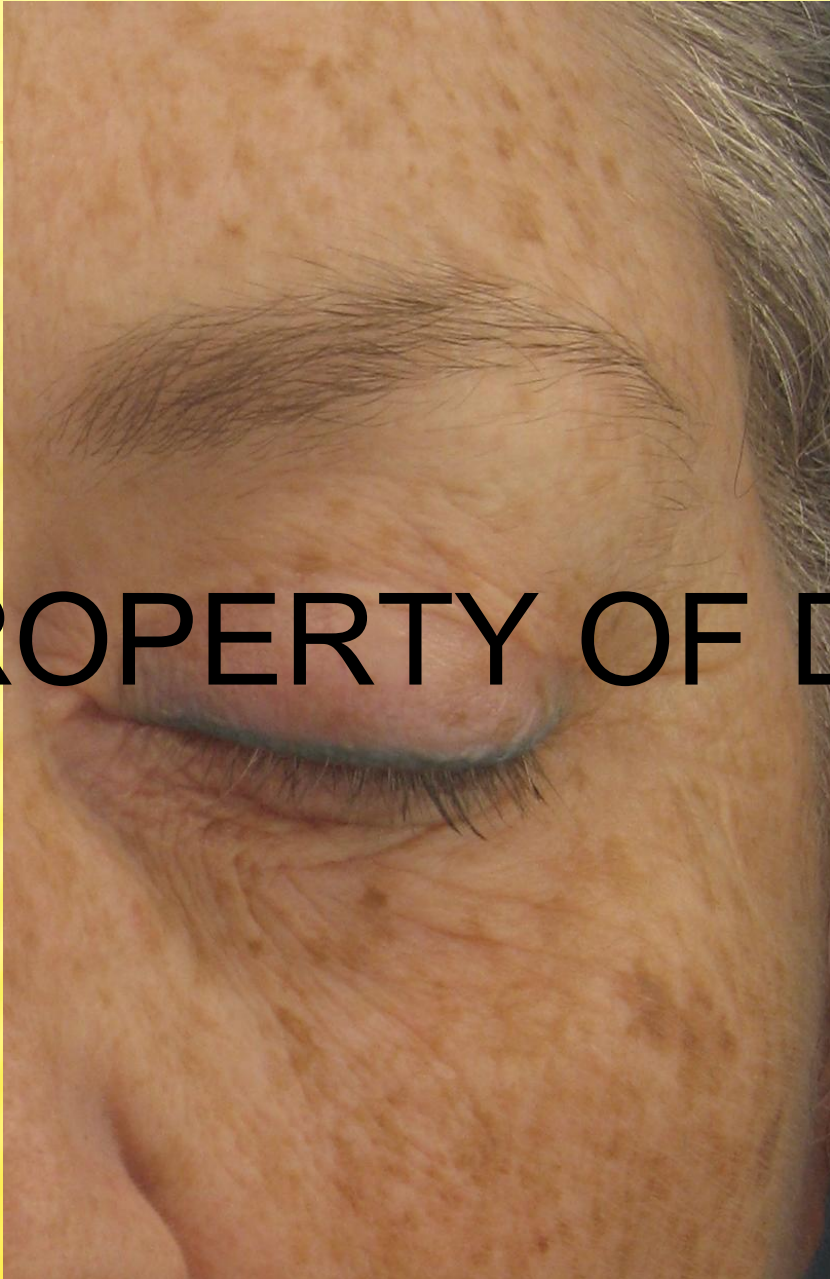
PROPERTY OF DR. JILL LEZAIC



PROPERTY OF DR. JILL LEZAIC

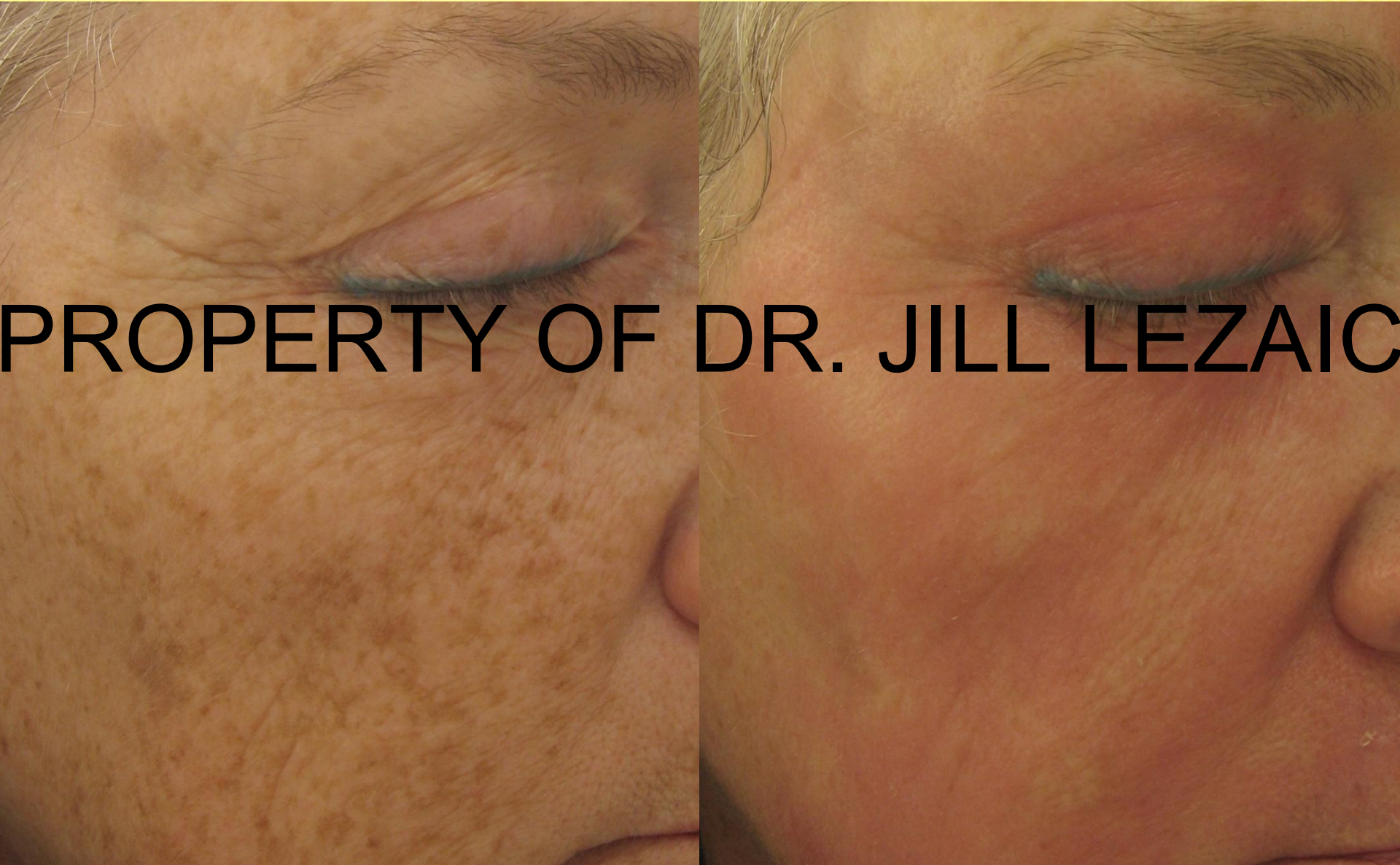PROPERTY OF DR. JILL LEZAIC



PEARL FUSION

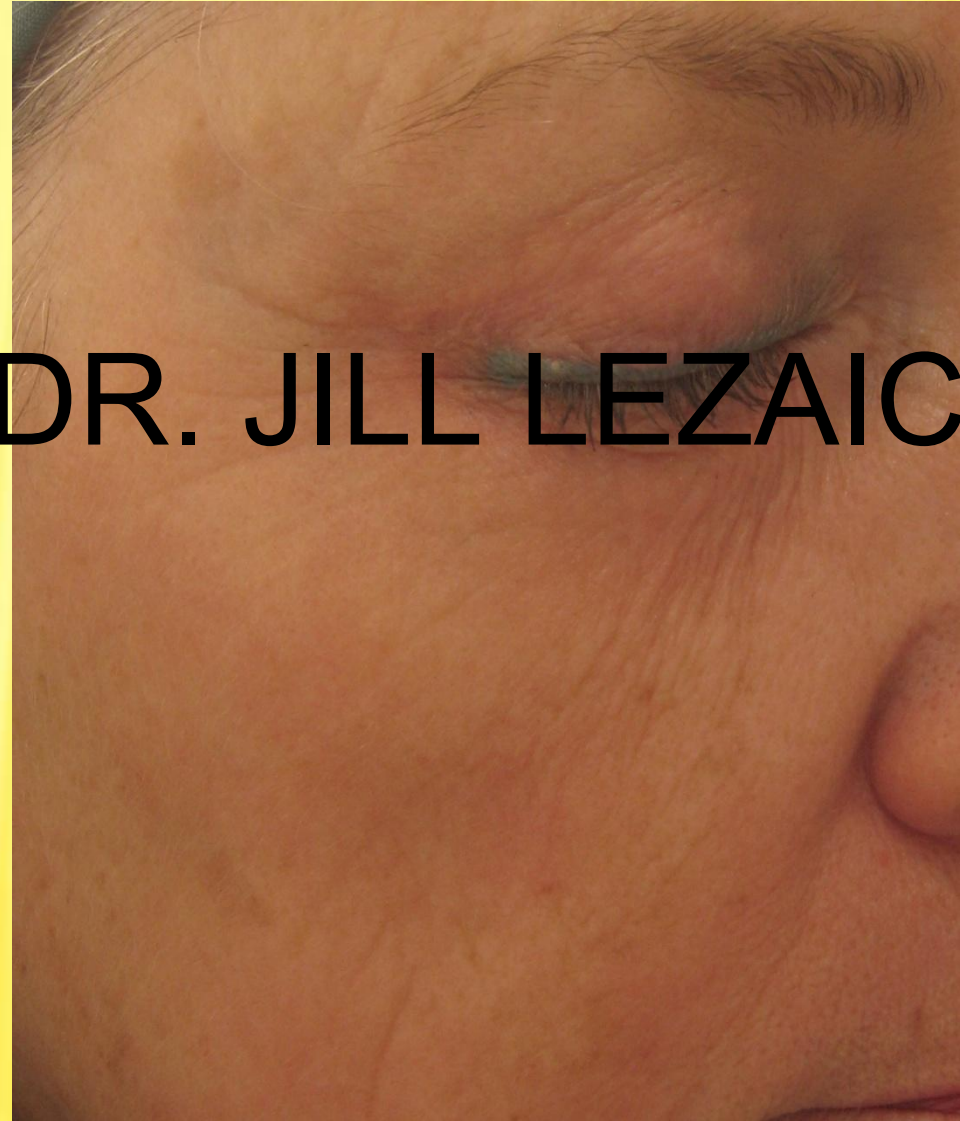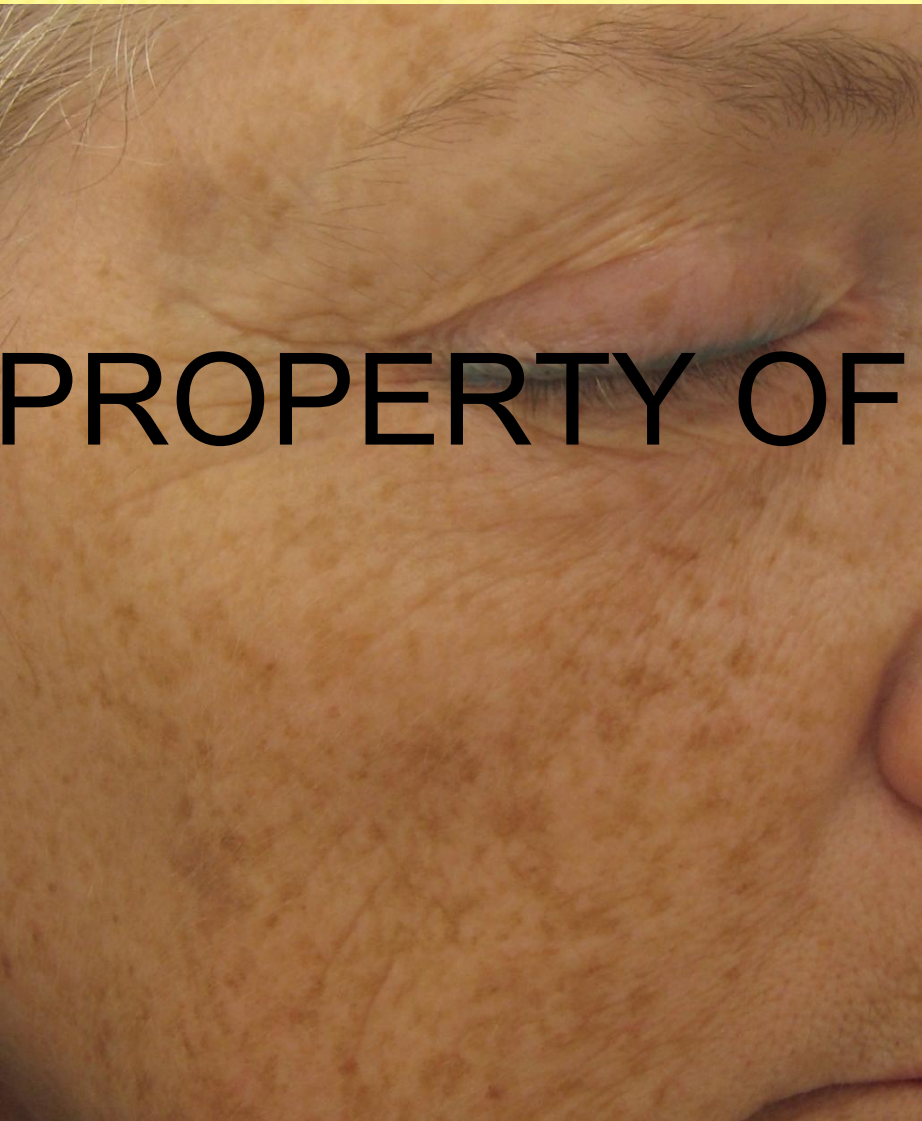A Cutera Aesthetic Seminar

10 DAYS POST TREATMENT

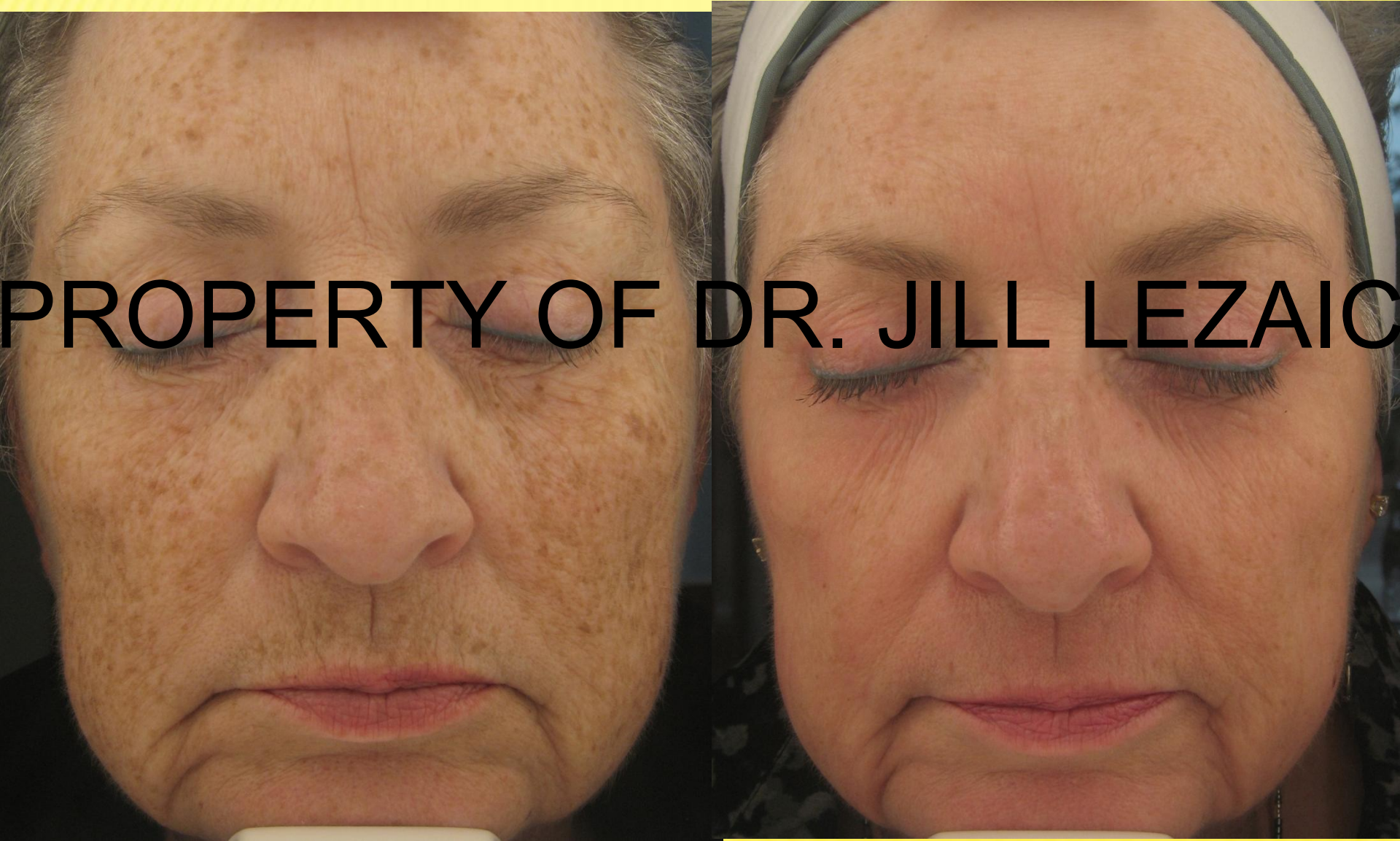

PROPERTY OF DR. JILL LEZAIC

PEARL FUSION 8 MONTHS POST TREATMENT



PROPERTY OF DR. JILL LEZAIC

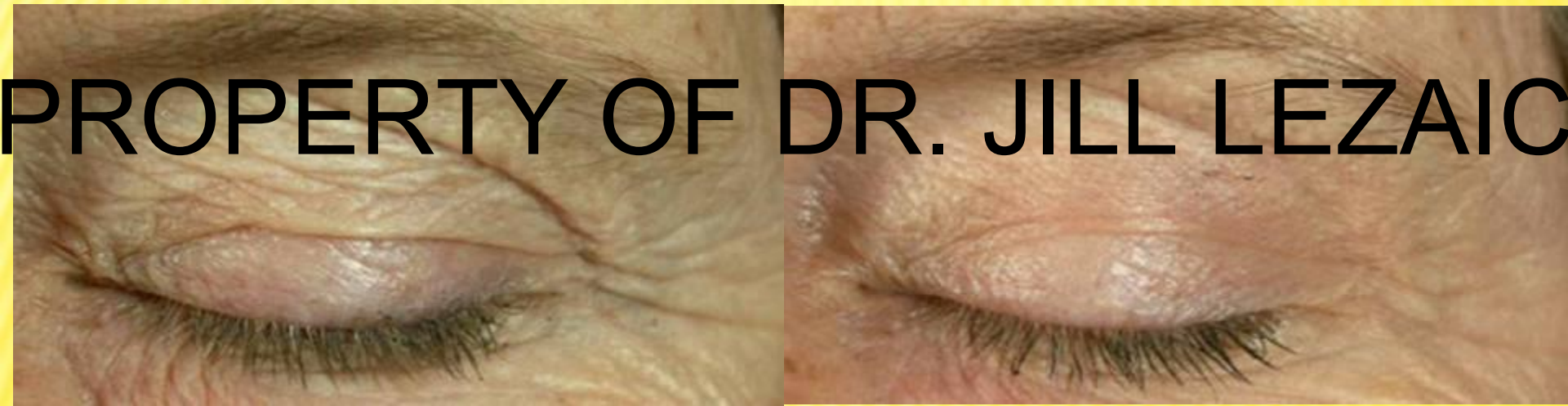

PROPERTY OF DR. JILL LEZAIO

Pearl Fusion
Combination Pearl and Pearl Fractional

Pre Tx

3 Weeks Post, 1 Tx

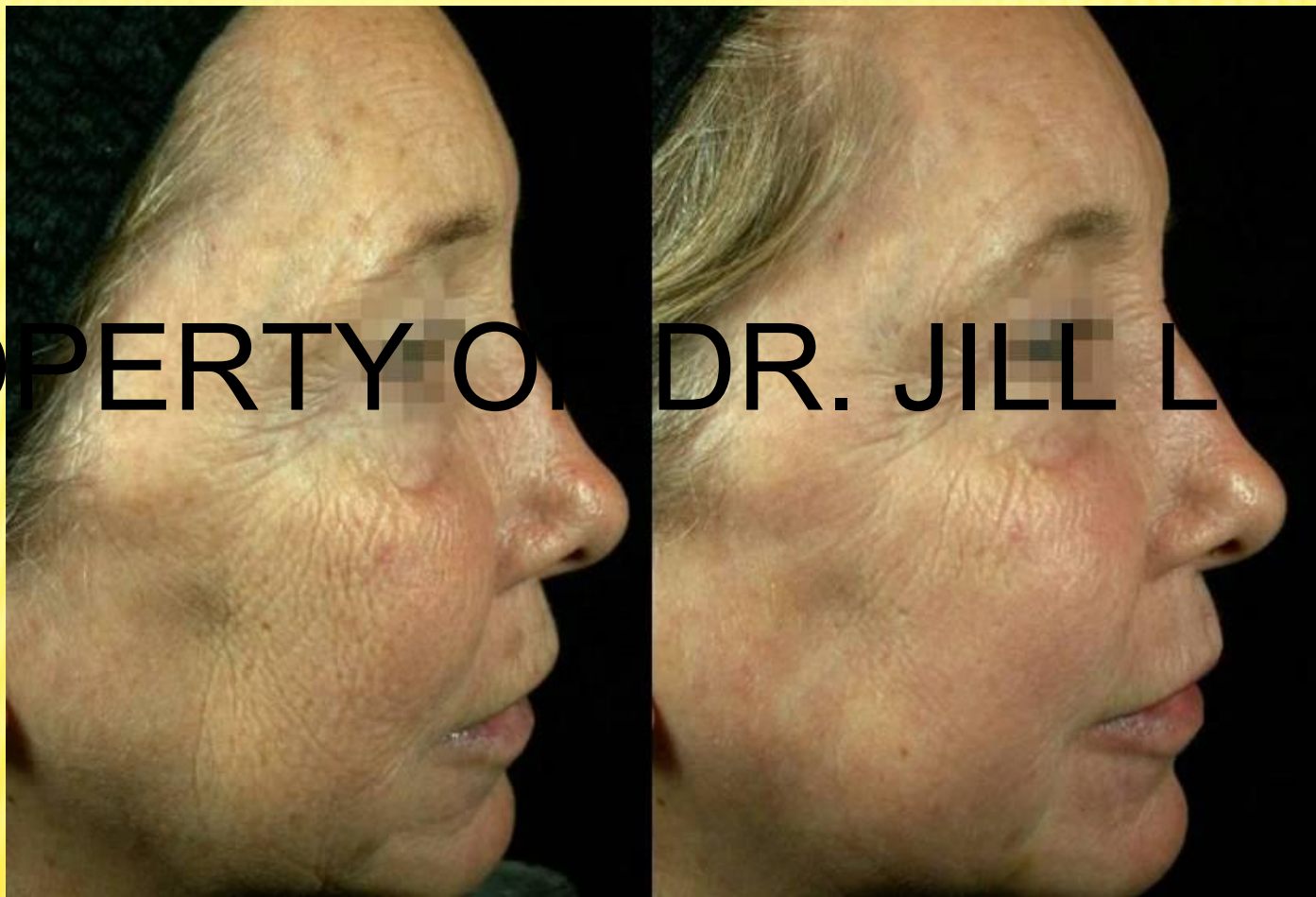

Pearl 3.0 J/cm², 10% overlap, 1 pass, full face. Pearl Fractional 160 mJ, 1 pass, density 4.
Photos courtesy of Brian S. Biesman, MD

Pearl Fusion
Combination Pearl and Pearl Fractional

Before

3 weeks post 1 tx

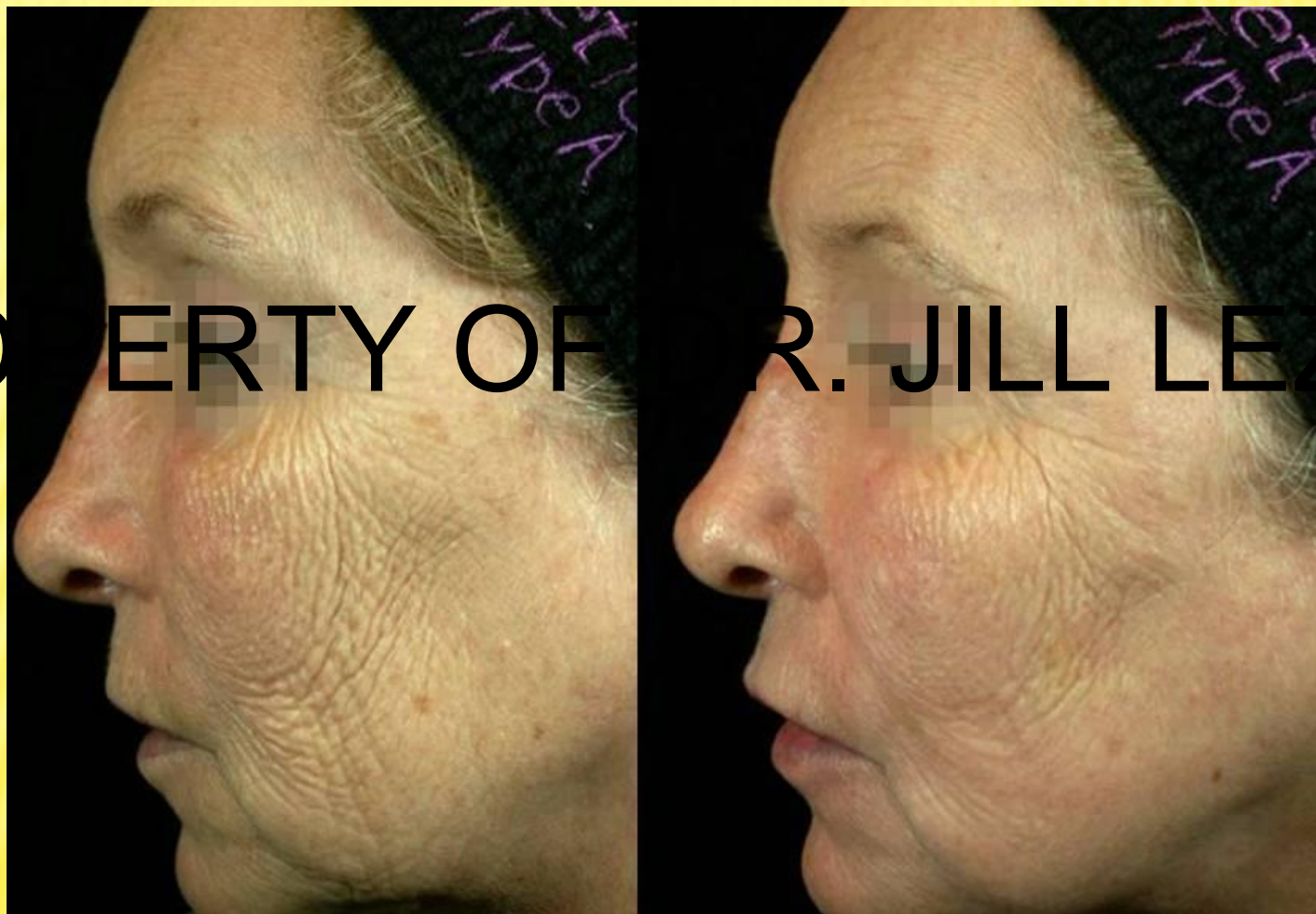

Pearl Full Face, Single Pass at 3.3 J/cm², 10% overlap
Pearl Fractional Full Face, Single Pass at 160 mJ, Density 4

Pearl Fusion
Combination Pearl and Pearl Fractional

Before

3 weeks post 1 tx

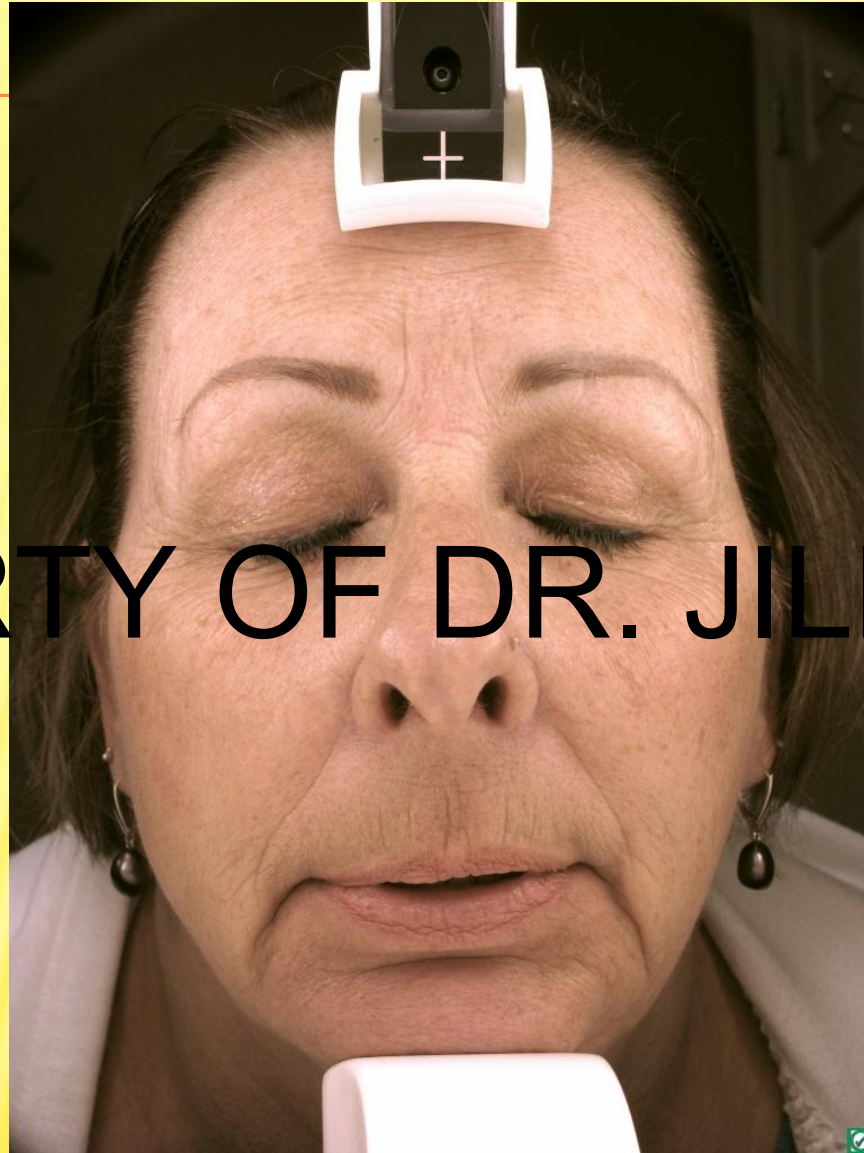

PROPERTY OF DR. JILL LEZAIC

Pearl Full Face, Single Pass at 3.3 J/cm², 10% overlap
Pearl Fractional Full Face, Single Pass at 160 mJ, Density 4

Photos courtesy of Brian Biesman, MD

PROPERTY OF DR. JILL LEZAIC



2/15/2010

PROPERTY OF DR. JILL LEZAIC




2/15/2010

PROPERTY OF DR. JILL LEZAIC



2/15/2010

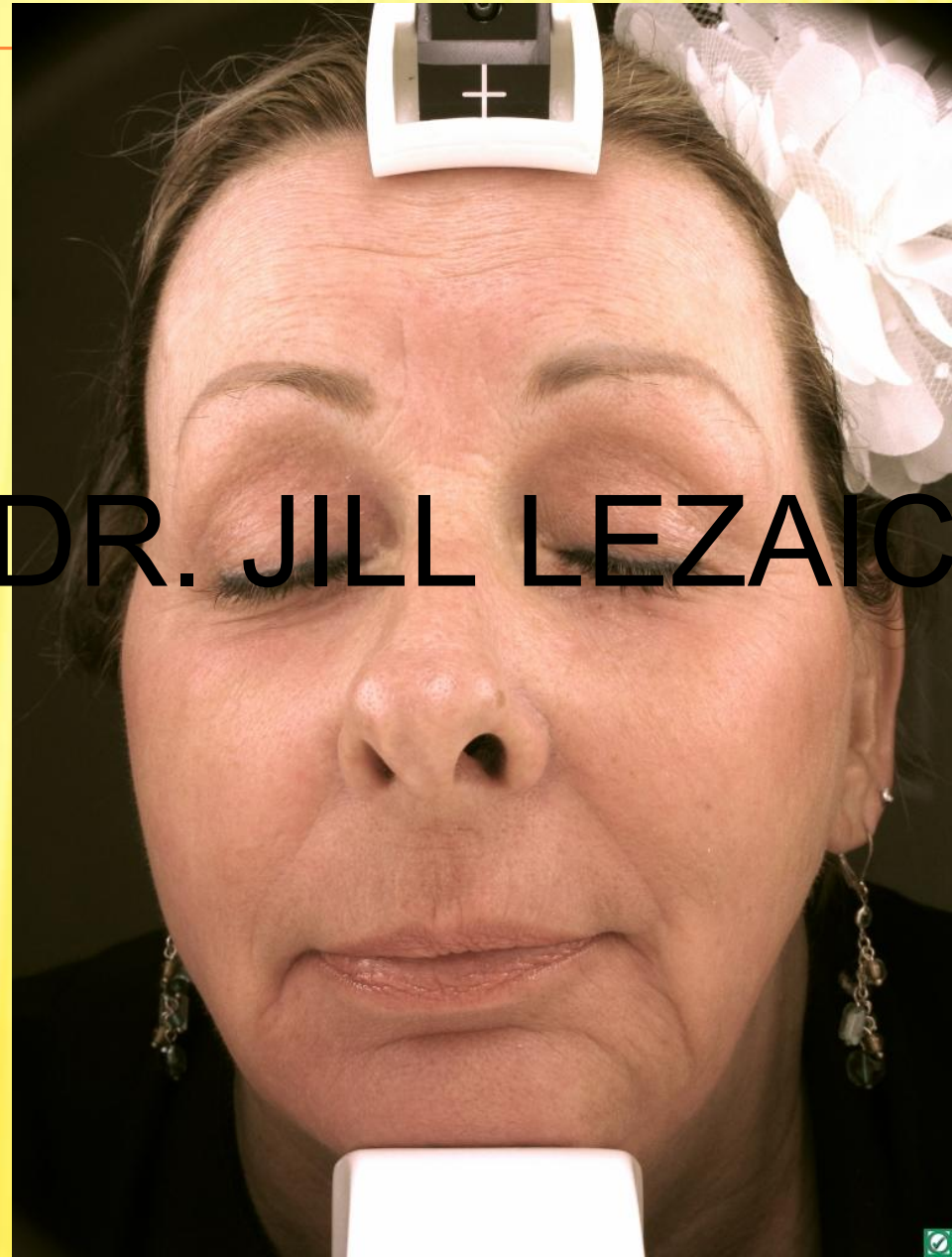PROPERTY OF DR. JILL LEZAIC



5/7/2010

BEFORE
RADIESSE

4 WEEKS AFTER 1 PEARL FUSION &
RADIESSE

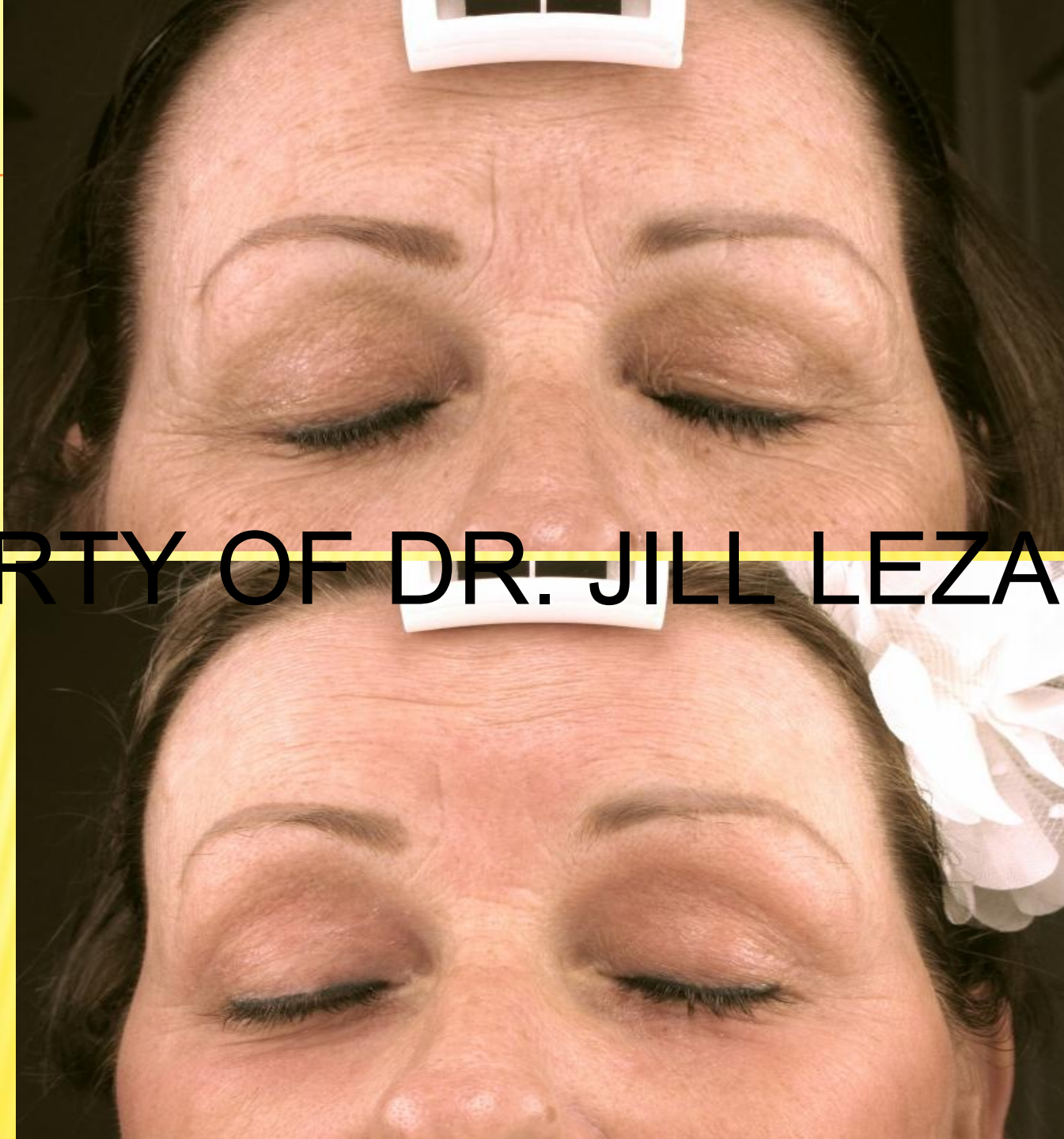

PROPERTY OF DR. JILL LEZAIC

Before

PROPERTY OF DR. JILL LEZAIC

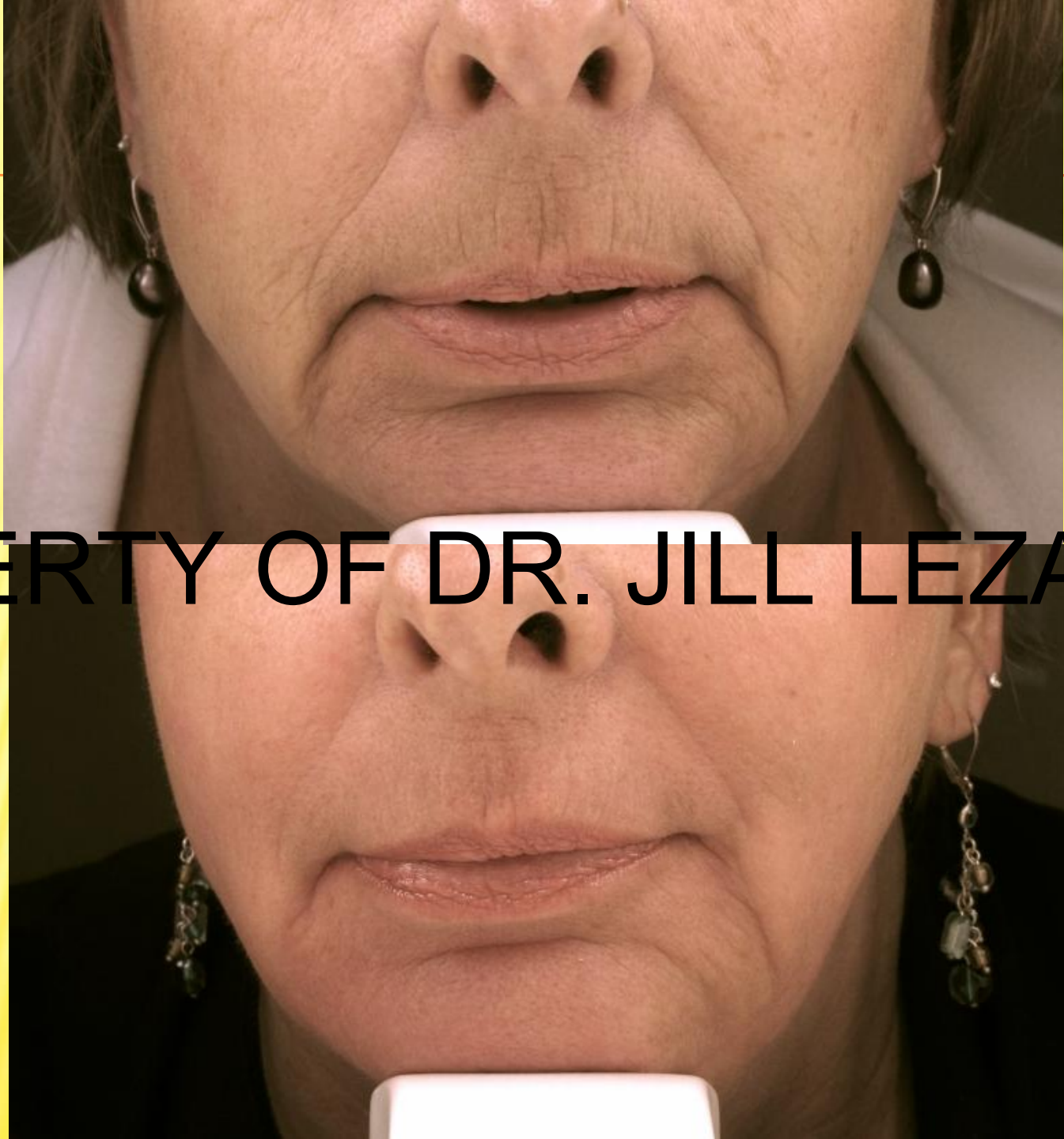
**4 Weeks
After 1
Pearl
Fusion &
Radiesse**



BEFORE

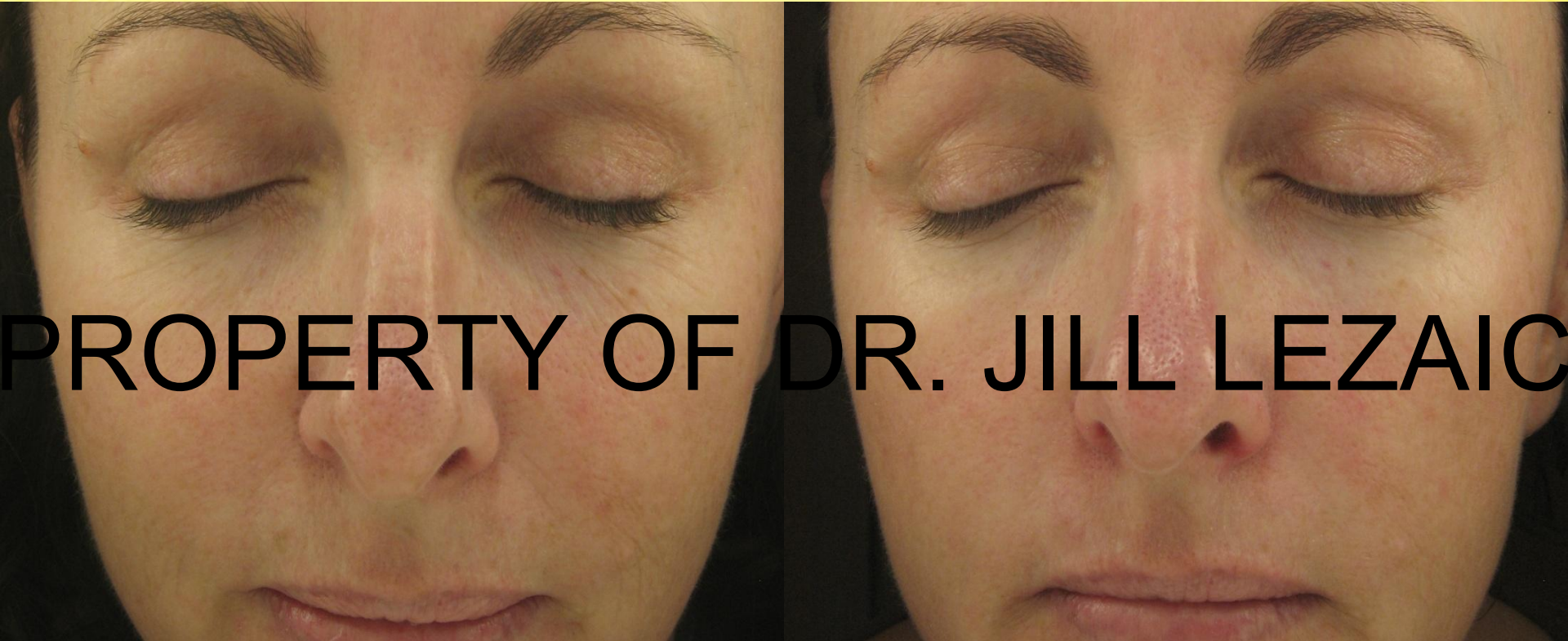PROPERTY OF DR. JILL LEZAIC

**4 WEEKS
AFTER 1
PEARL
FUSION &
RADIESSE**



BEFORE

AFTER 5 TREATMENTS



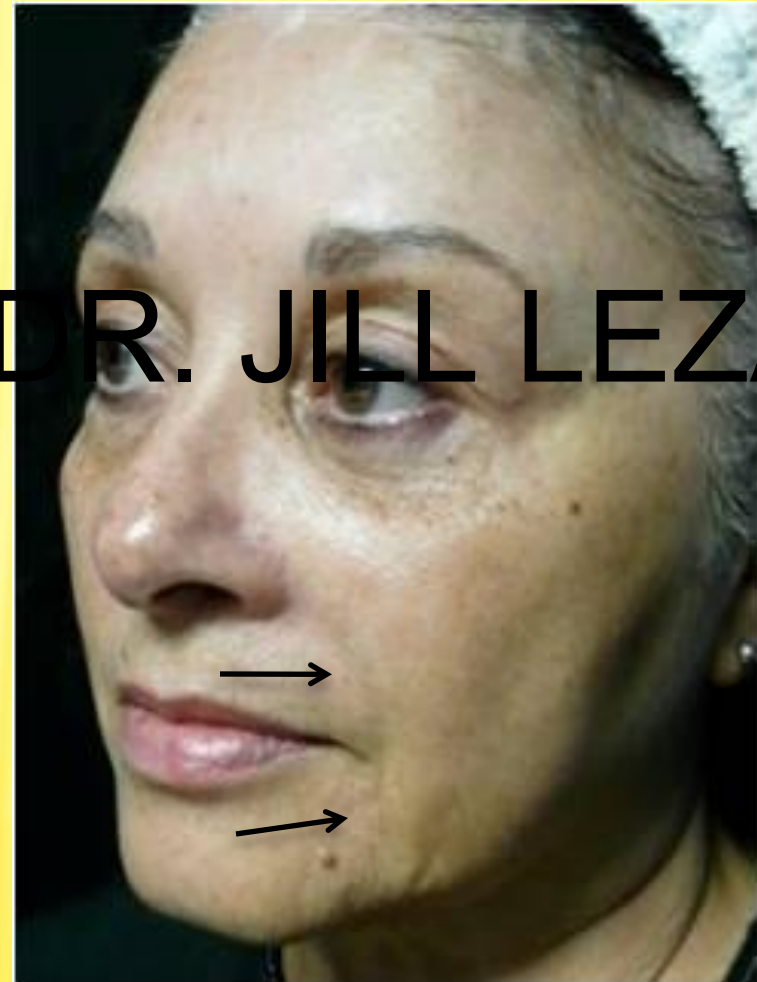PROPERTY OF DR. JILL LEZAIC

ANTI-AGING PACKAGE: VIBRADERM/GENESIS/IPL

RADIESSE TO NLFS & ORAL COMMISSURES

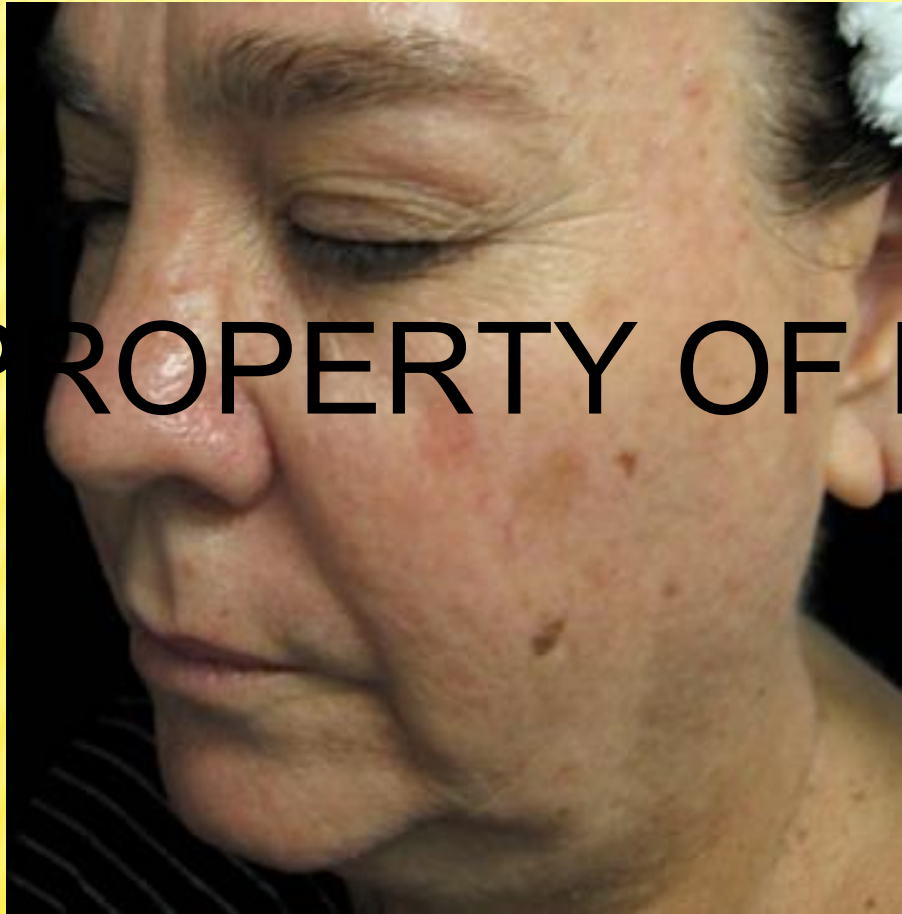0.8CC SYRINGE, 0.4CC TO EACH SIDE

(IPL 1 TREATMENT)

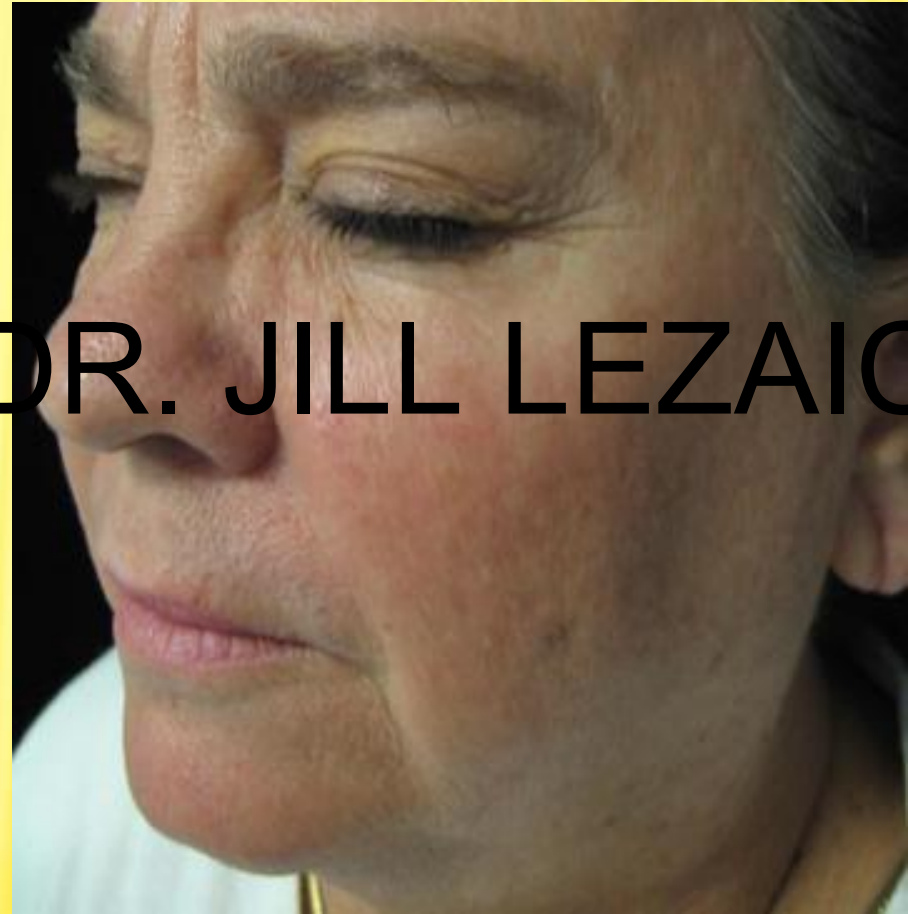

PROPERTY OF DR. JILL LEZAIC

IPL WITH ALA



Before



After one treatment

PROPERTY OF DR. JILL LEZAIC

PROPERTY OF DR. JILL LEZAIC

LASER HAIR REMOVAL

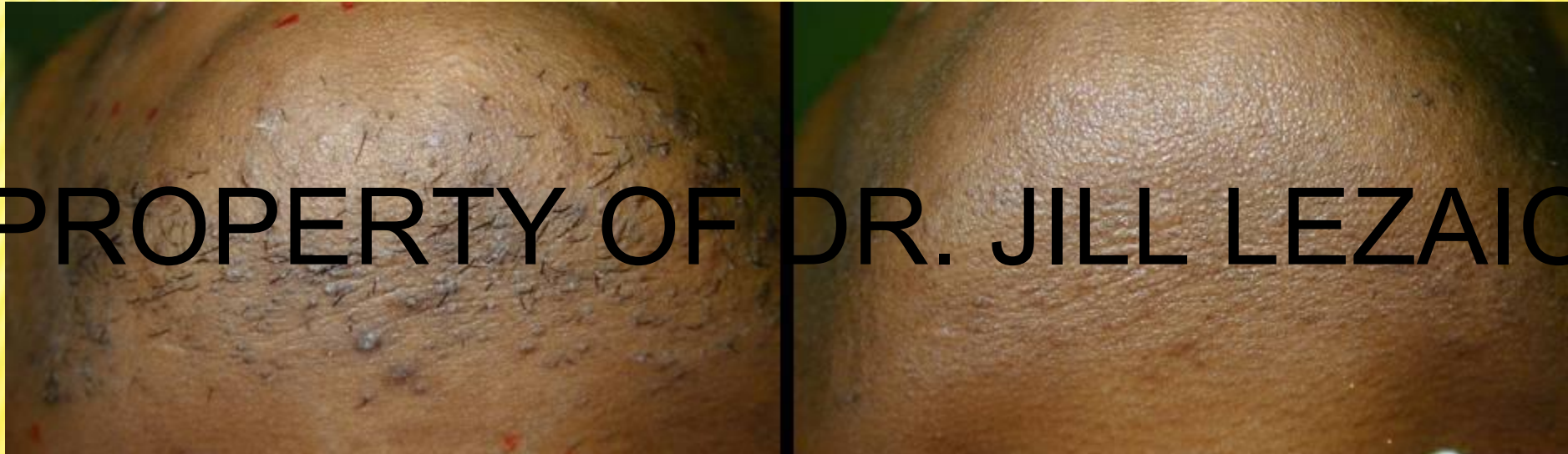LASER HAIR REMOVAL

- ◉ Removes 70-90% of hair follicles permanently.
- ◉ Most patients tolerate the procedure very well.
 - > Less than 30% of my patients use topical numbing cream.
- ◉ Hair grows in 3 separate growth cycles. Only actively growing hairs will be effectively treated.
- ◉ This is the reason that a series of treatments are required in order to destroy all hair follicles.
 - > Removal takes either a 5 treatment package or a 9 treatment package depending on area & amount.
 - > Treatments are performed every 4 to 6 weeks.
 - > 1 to 2 follow-up treatments may be necessary per year.

PROPERTY OF DR. JILL LEZAIC

HAIR REMOVAL TREATMENT

Treatment with Cutera 1064 nm system

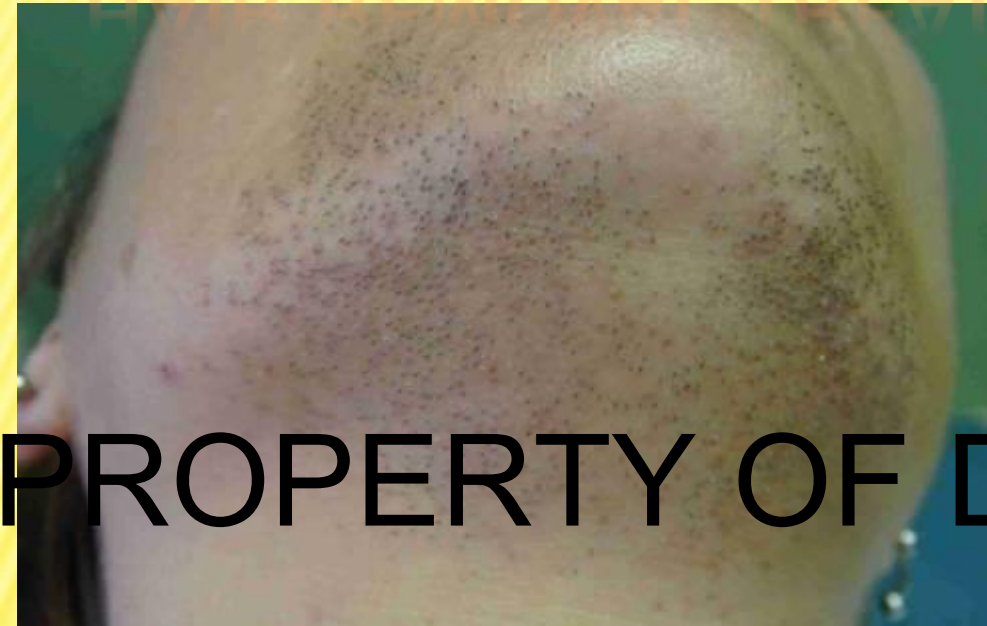

Before

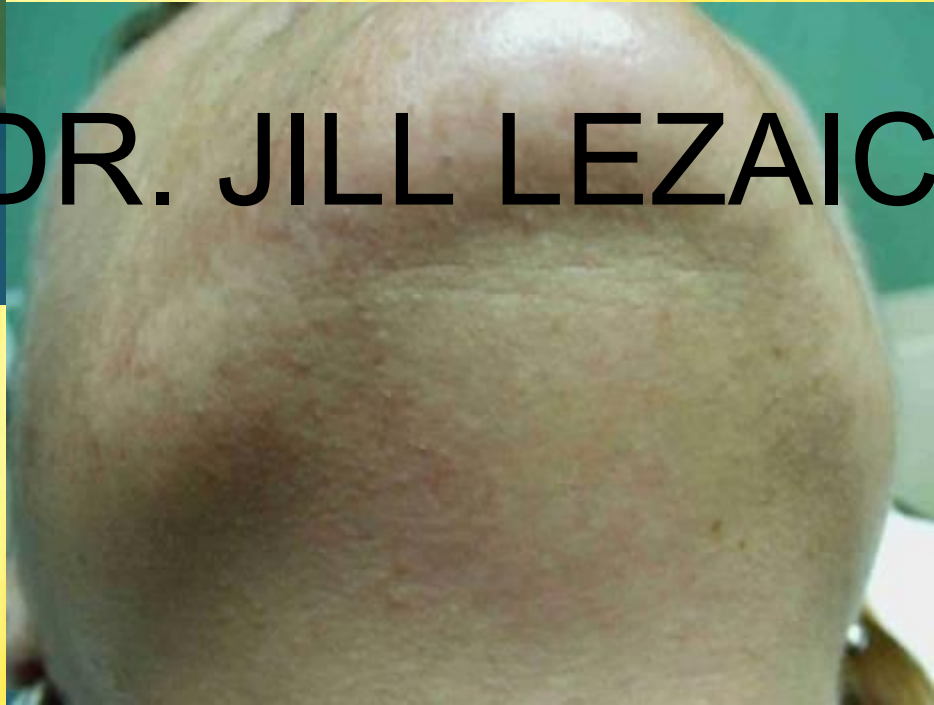After

PROPERTY OF DR. JILL LEZAIC

HAIR REMOVAL TREATMENT

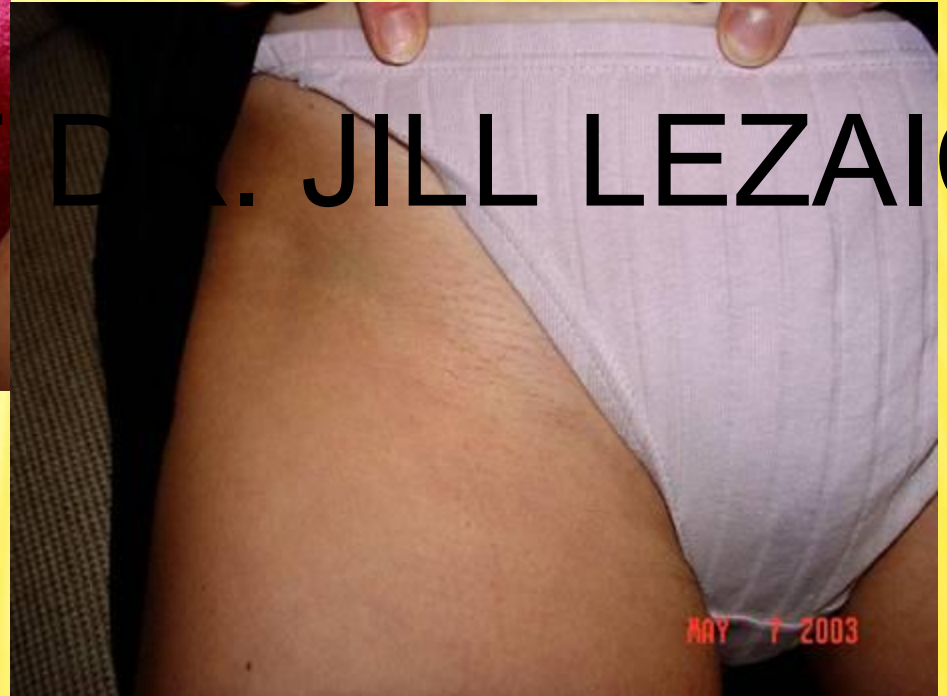
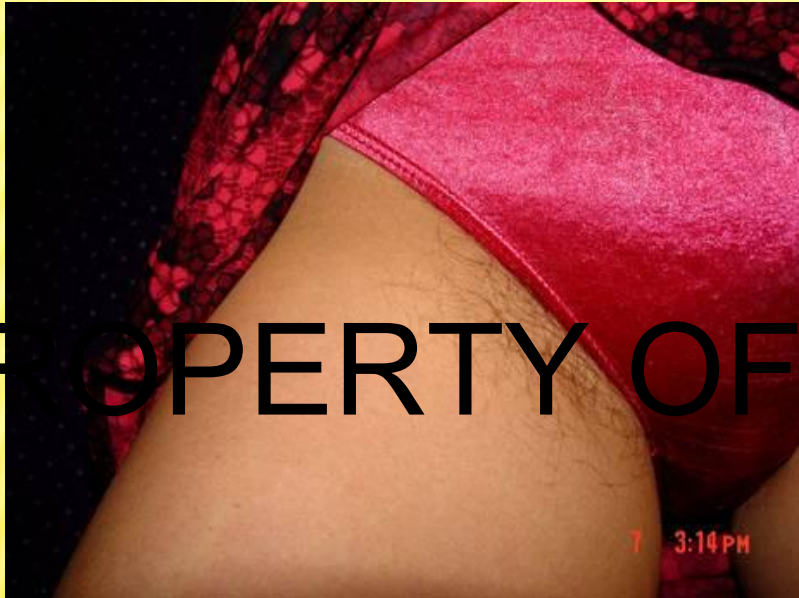
PROPERTY OF DR. JILL LEZAIC



Treatment with Cutera 1064 nm system

HAIR REMOVAL TREATMENT



PROPERTY OF DR. JILL LEZAIC

Treatment with Cutera 1064 nm system

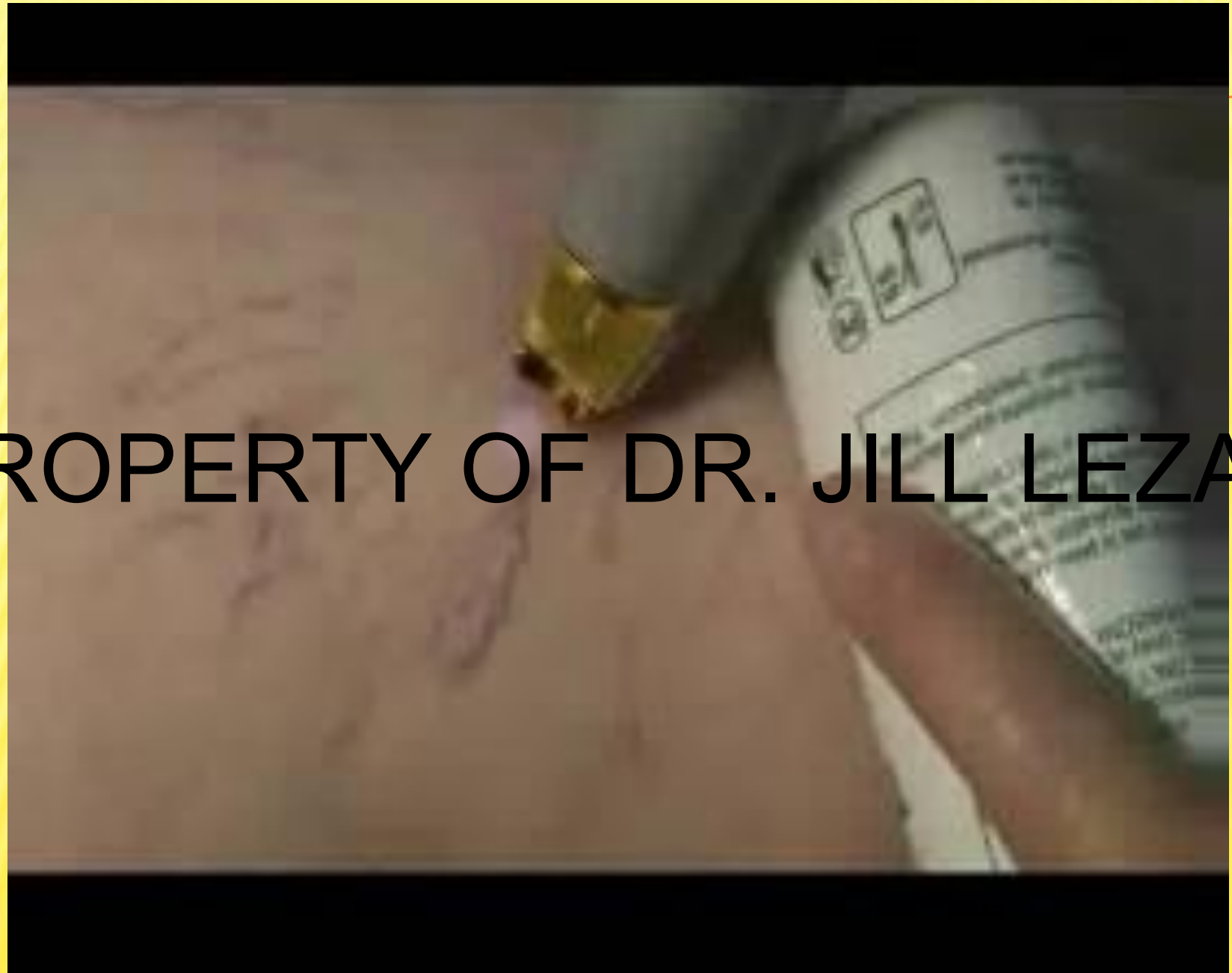PROPERTY OF DR. JILL LEZAIC

LASER VEIN REMOVAL

LASER VEIN REMOVAL

- ✘ Very effective for the face & legs

PROPERTY OF DR. JILL LEZAIC

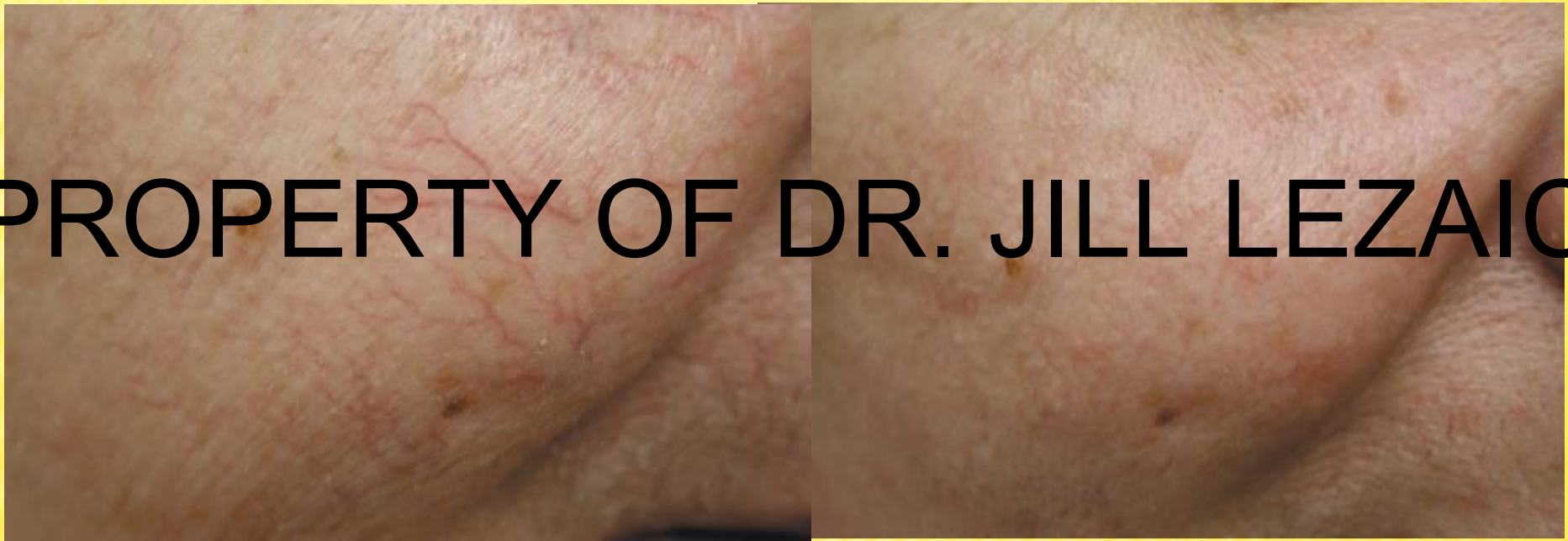

PROPERTY OF DR. JILL LEZAIC

CoolGlide Nd:YAG

Before

5 weeks After 1 Treatment



Photos courtesy of Don Groot, MD

COOLGLIDE ND:YAG: LEG VEINS

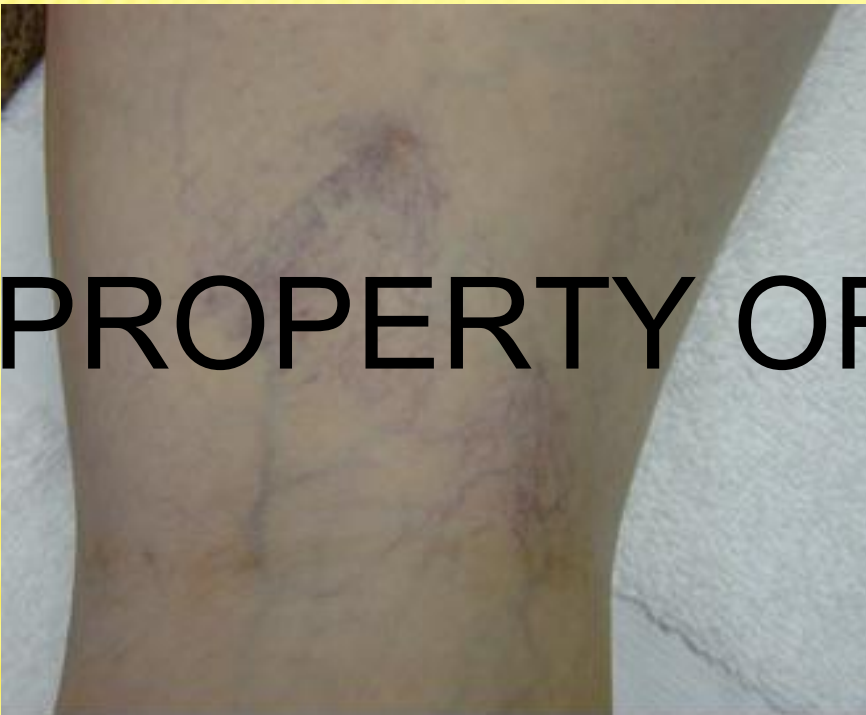

Photo Courtesy of Samuel Lederman, MD
Lakeworth, FL

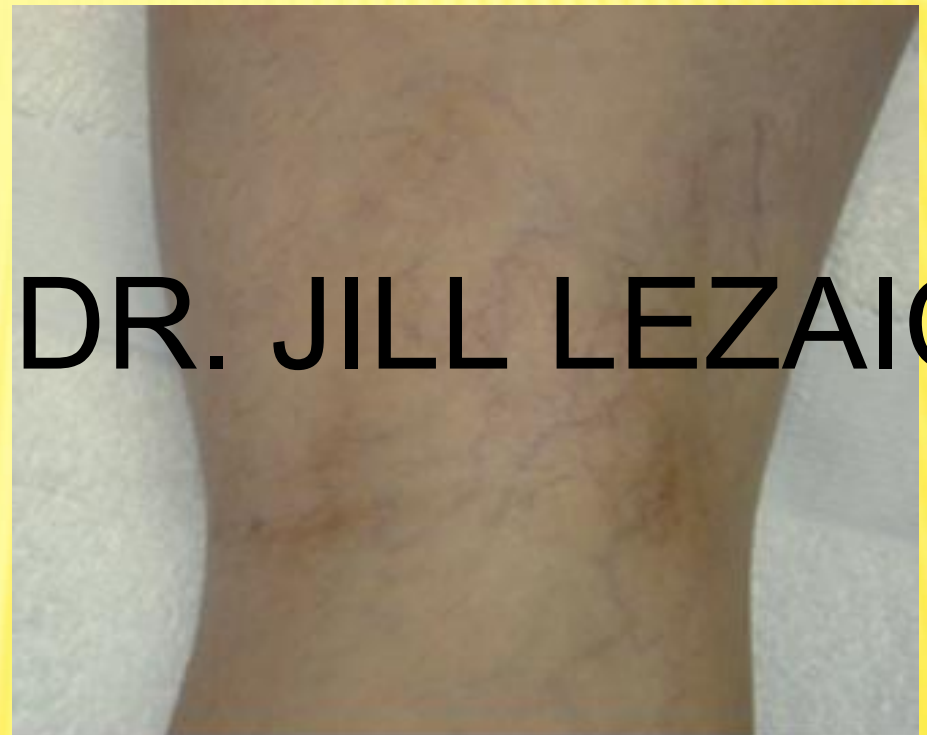

Photo Courtesy of Samuel Lederman, MD
Lakeworth, FL

PROPERTY OF DR. JILL LEZAIC

COOLGLIDE ND:YAG: LEG VEINS

PROPERTY OF DR. JILL LEZAIC

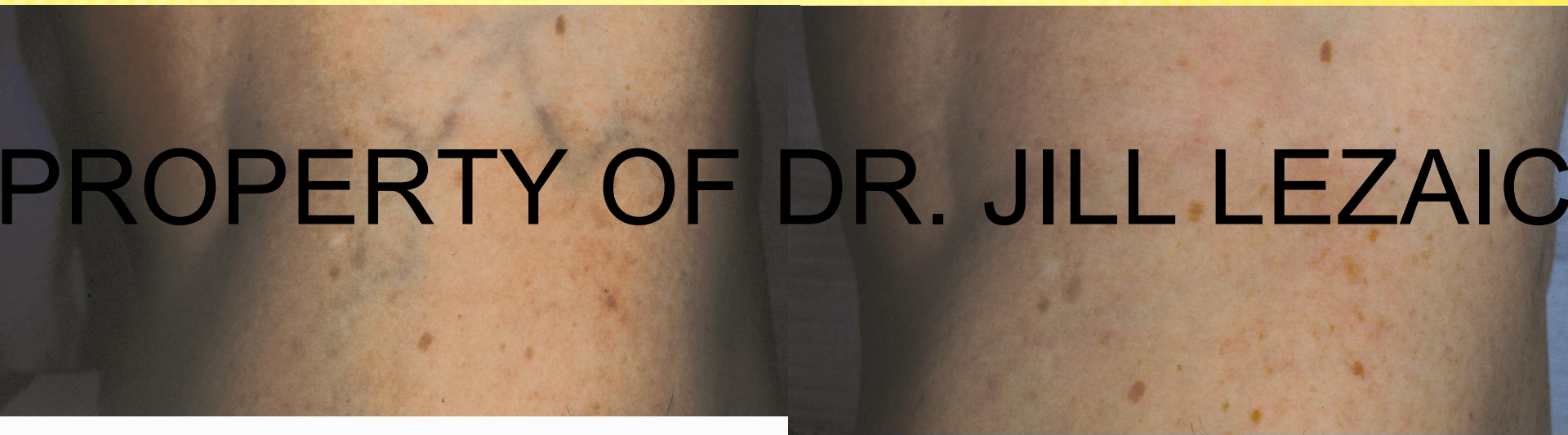


Photo Courtesy of Arielle Kauvar, MD
Laser and Skin Surgery Center, NY

Photo Courtesy of Arielle Kauvar, MD
Laser and Skin Surgery Center, NY

LATERAL THIGH VESSELS

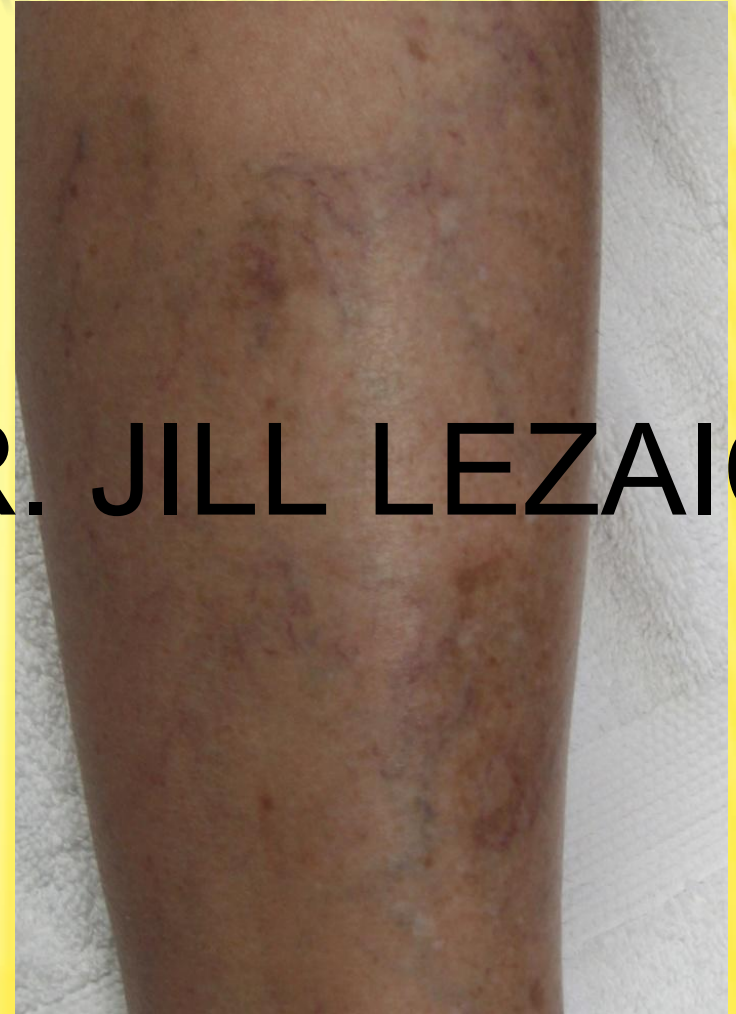
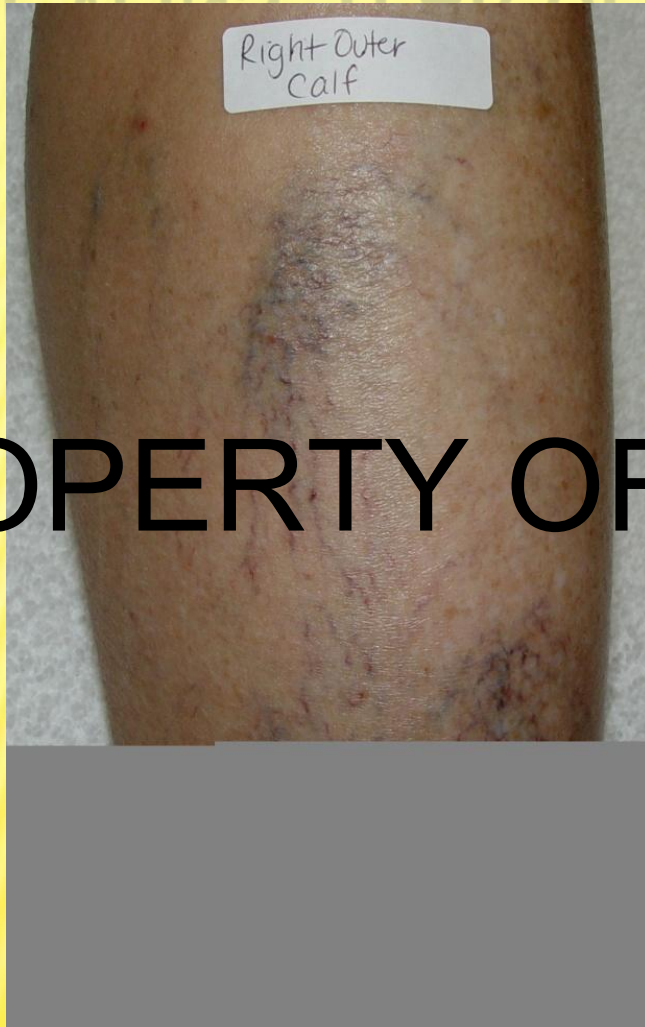
PROPERTY OF DR. JILL LEZAIC

✘ Before

✘ 2 weeks after 1 treatment

CALF VEINS: YEAR OLD FEMALE, SKIN TYPE IV

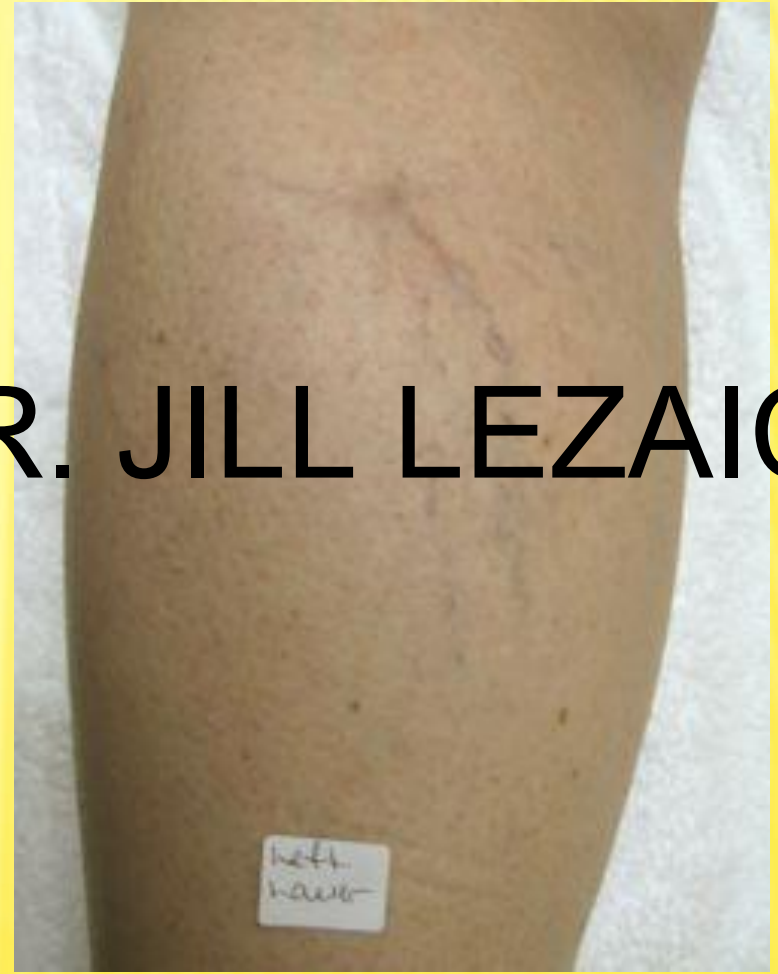
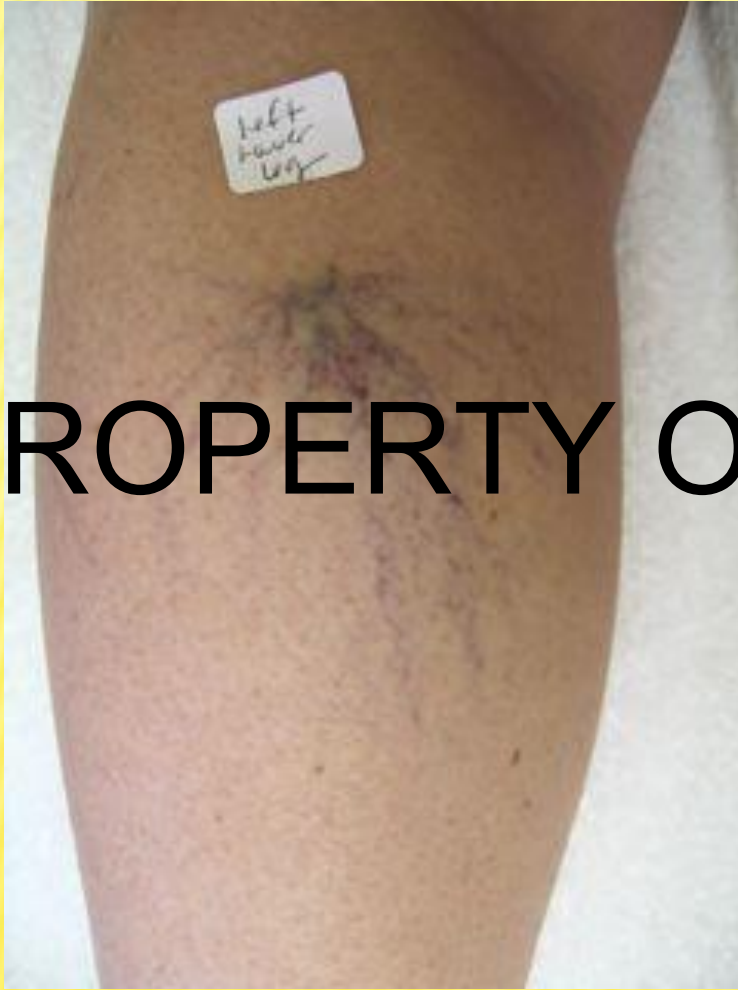
PROPERTY OF DR. JILL LEZAIC

✘ Before

✘ After 1 Treatment

LASE VEIN REMOVAL

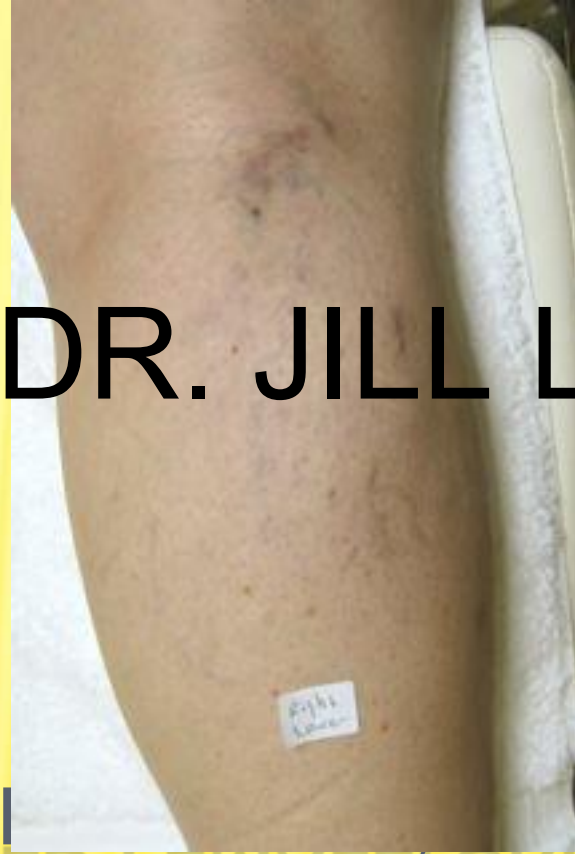
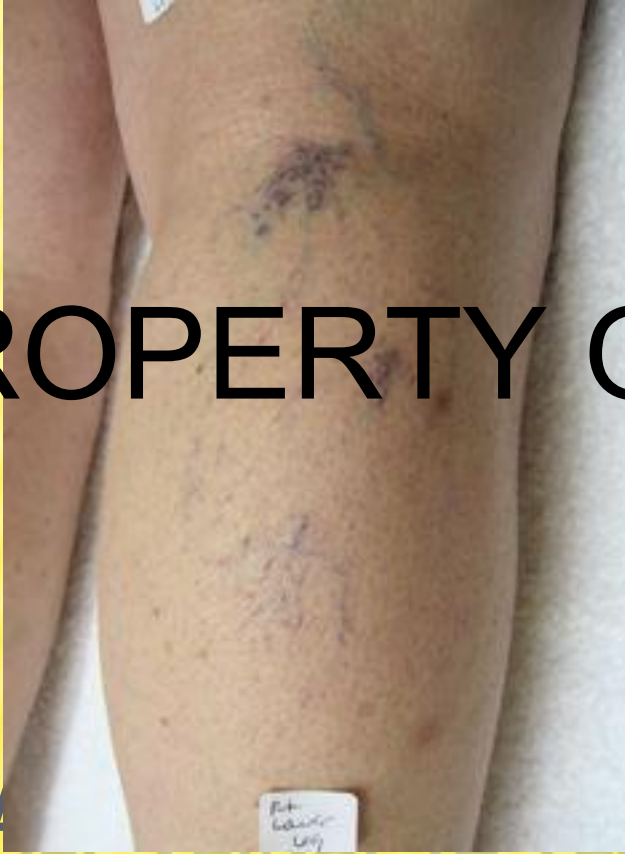
PROPERTY OF DR. JILL LEZAIC

✘ Before

✘ After 2 Treatments

PROPERTY OF DR. JILL LEZAIC



CA
BEFORE

AR OI

N TYPE

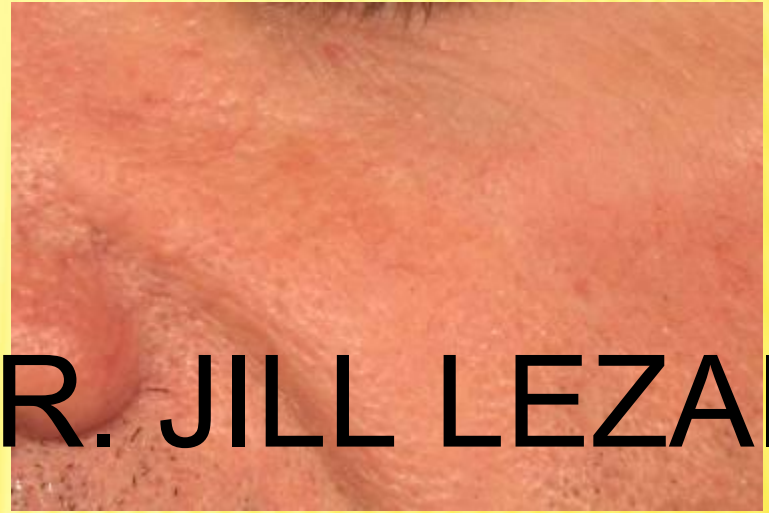AFTER 2 TREATMENTS

EQUIVALENT TO PDL

Before



6 weeks after 2 Tx

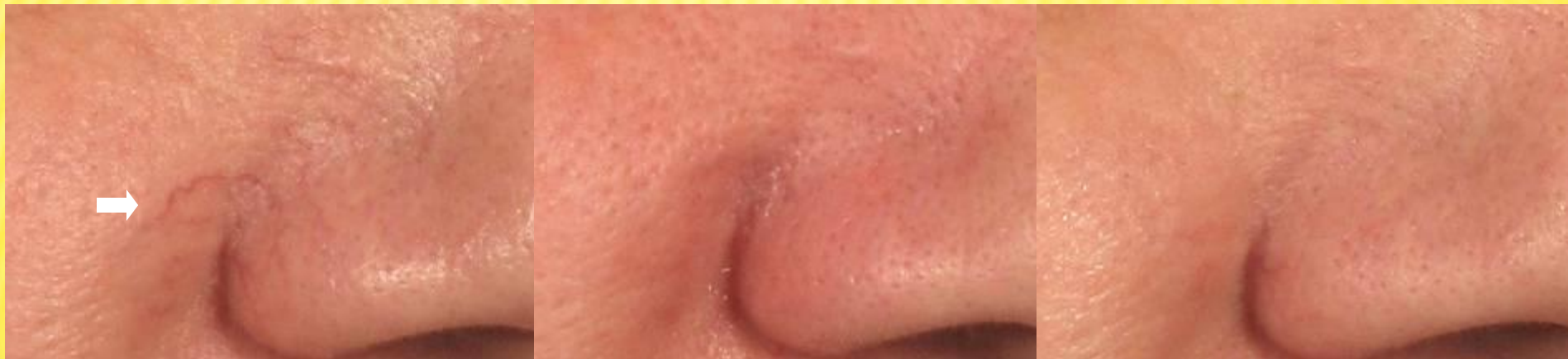

PROPERTY OF DR. JILL LEZAIC

Before

Immediate

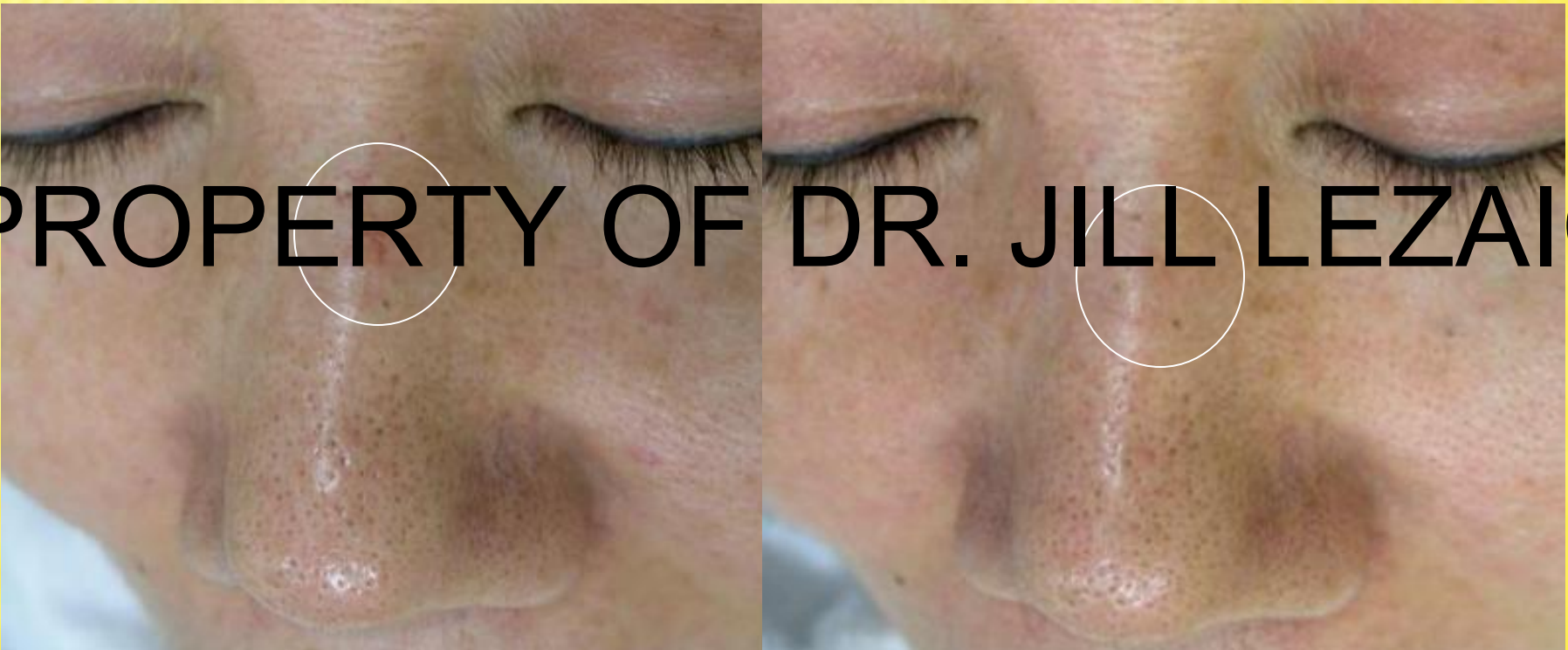1 month after 1 Tx



EQUIVALENT TO PDL ON SKIN TYPE IV WITH LOW RISK OF PIH

Before

4 weeks after 2 Tx



PROPERTY OF DR. JILL LEZAIC

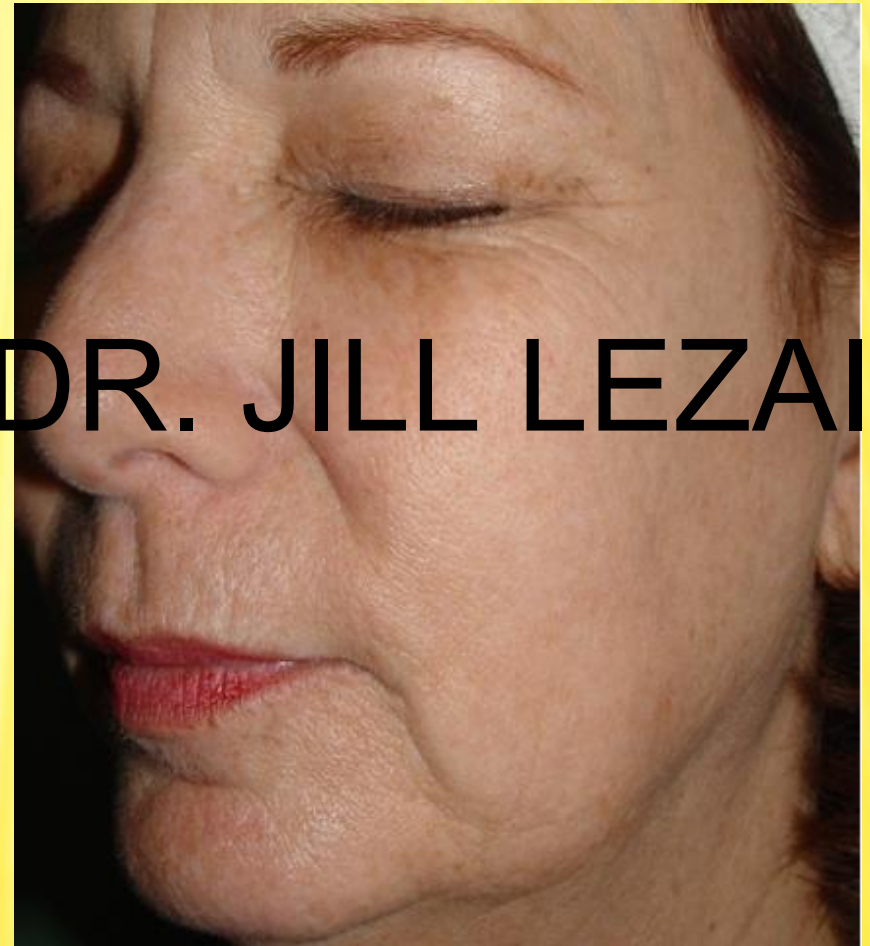PROPERTY OF DR. JILL LEZAIC

THE POWER OF COMBINATION
THERAPIES

LIMELIGHT



Before

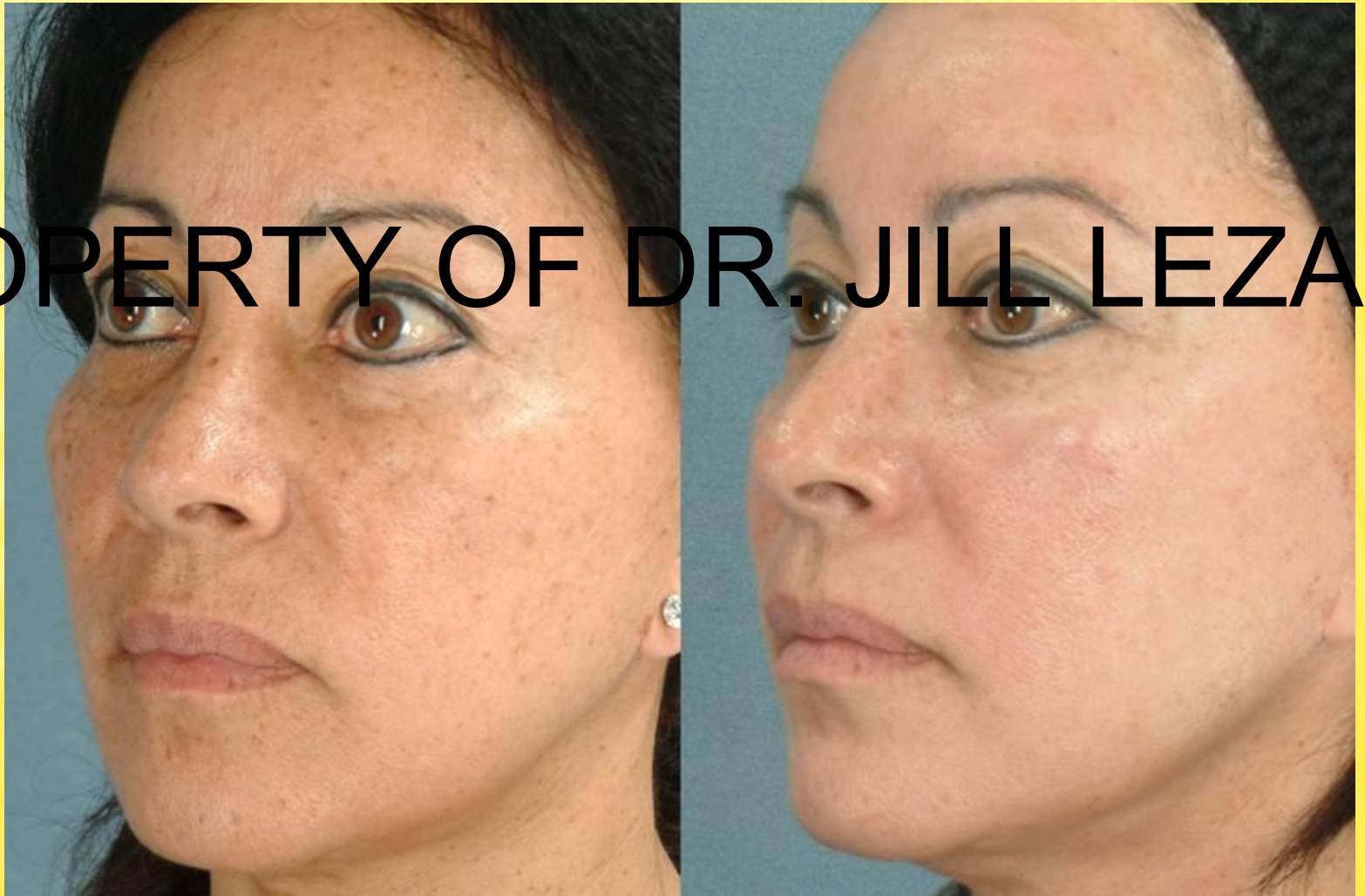

After 4 IPL Treatments
A Cutera Aesthetic Seminar

PROPERTY OF DR. JILL LEZAIC

LIMELIGHT IPL – SOLAR LENTIGINES

Program C Photos Courtesy of Barry DiBernardo, MD



PROPERTY OF DR. JILL LEZAIC

MULTI-MODALITY THERAPY

- Often there is more than one issue contributing to signs of aging & sun exposure on your skin
- Complementary treatments combine to increase your results & satisfaction by treating more symptoms in a single visit

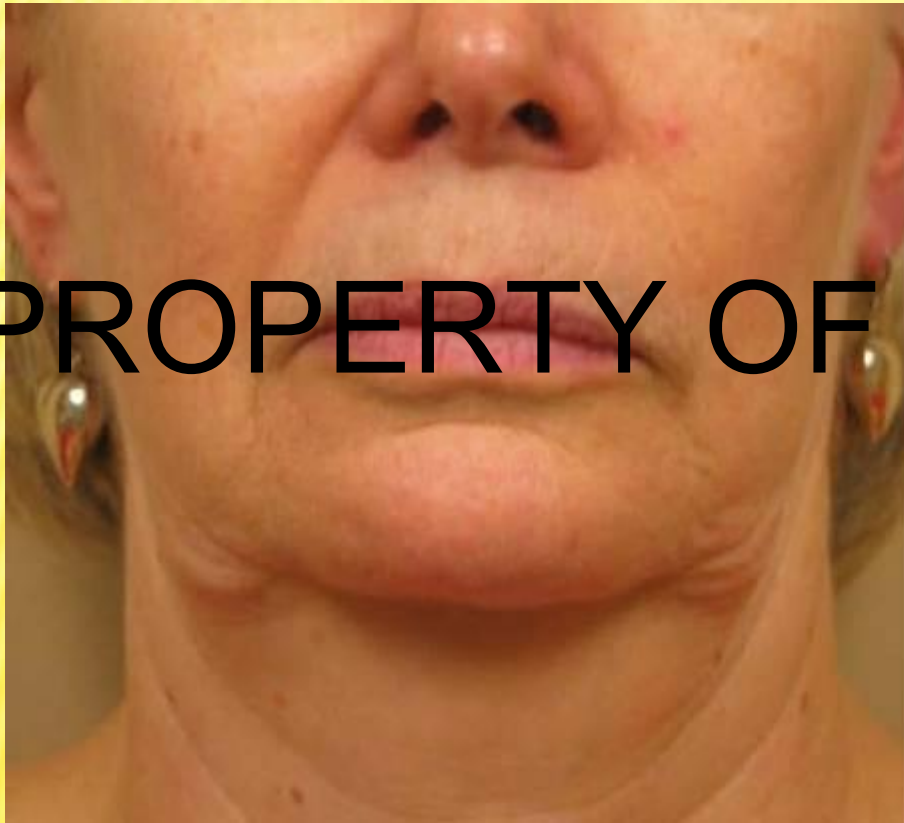PROPERTY OF DR. JILL LEZAIC

Can create better overall results

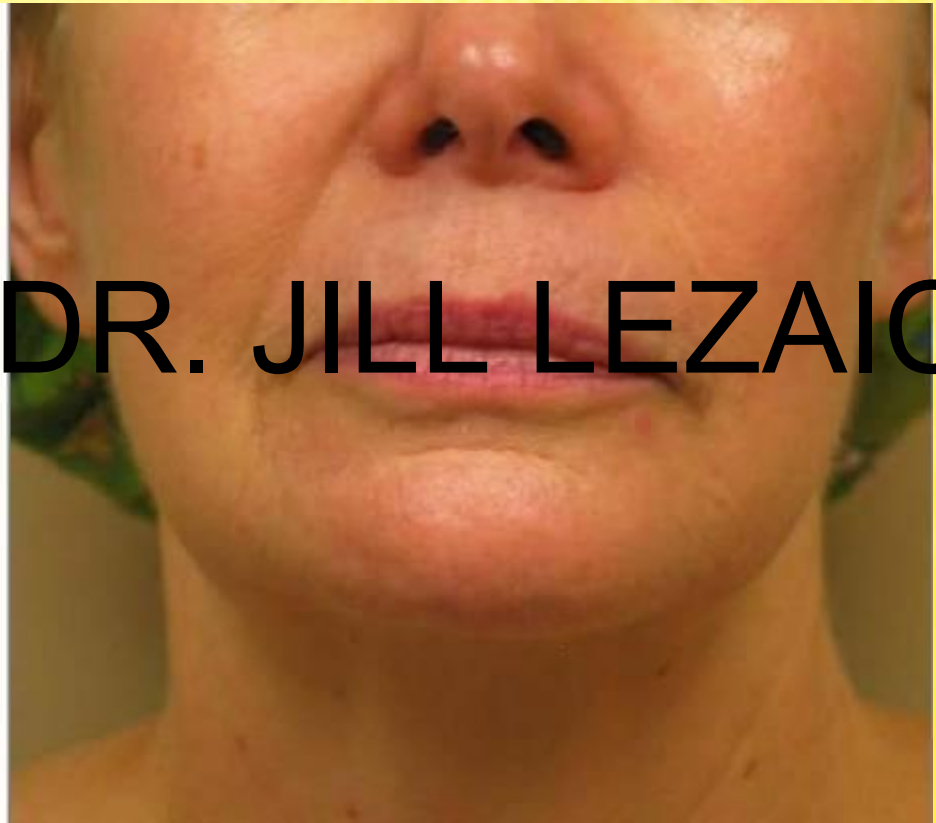- > Allows your physician to offer a tailor-made solution for each patient
- Complementary treatments
 - > Zero-downtime combination: Titan, Laser Genesis and LimeLight
 - > Minimal-downtime combination: Pearl, Pearl Fractional and LimeLight
 - > Fillers, microdermabrasion, chemical peels and topical creams
 - > Any combination of the above options

TITAN, LASER GENESIS & LIMELIGHT

Before



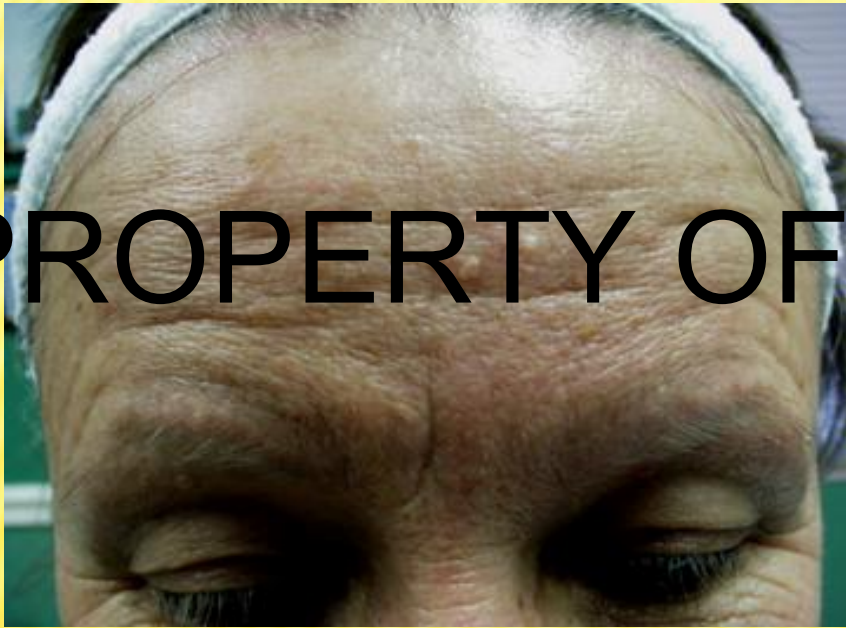2 Weeks After 2nd Treatment



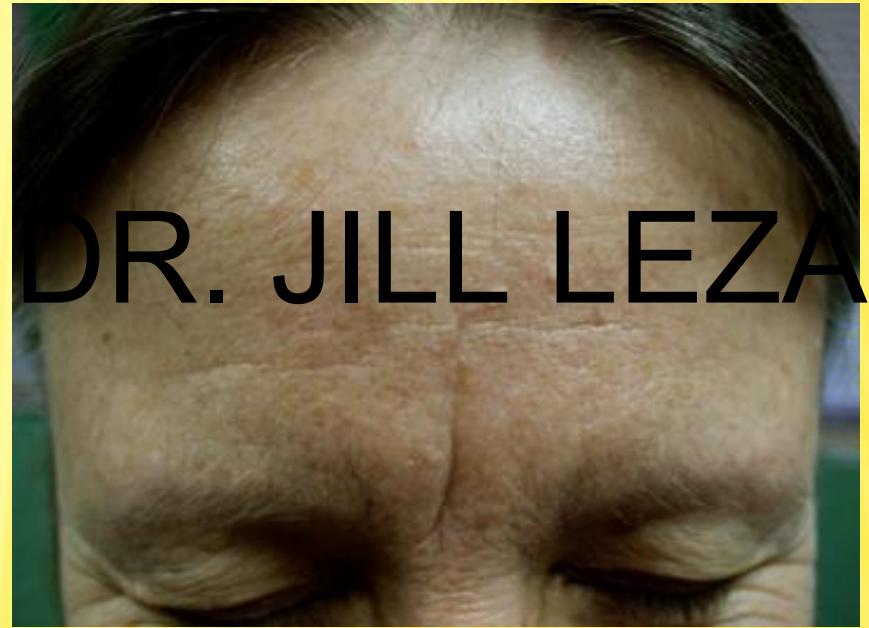PROPERTY OF DR. JILL LEZAIC

Photos courtesy of Amy Hannahs & Mary Boaglio, RN
Flourish Skin & Laser

Laser Genesis



Before



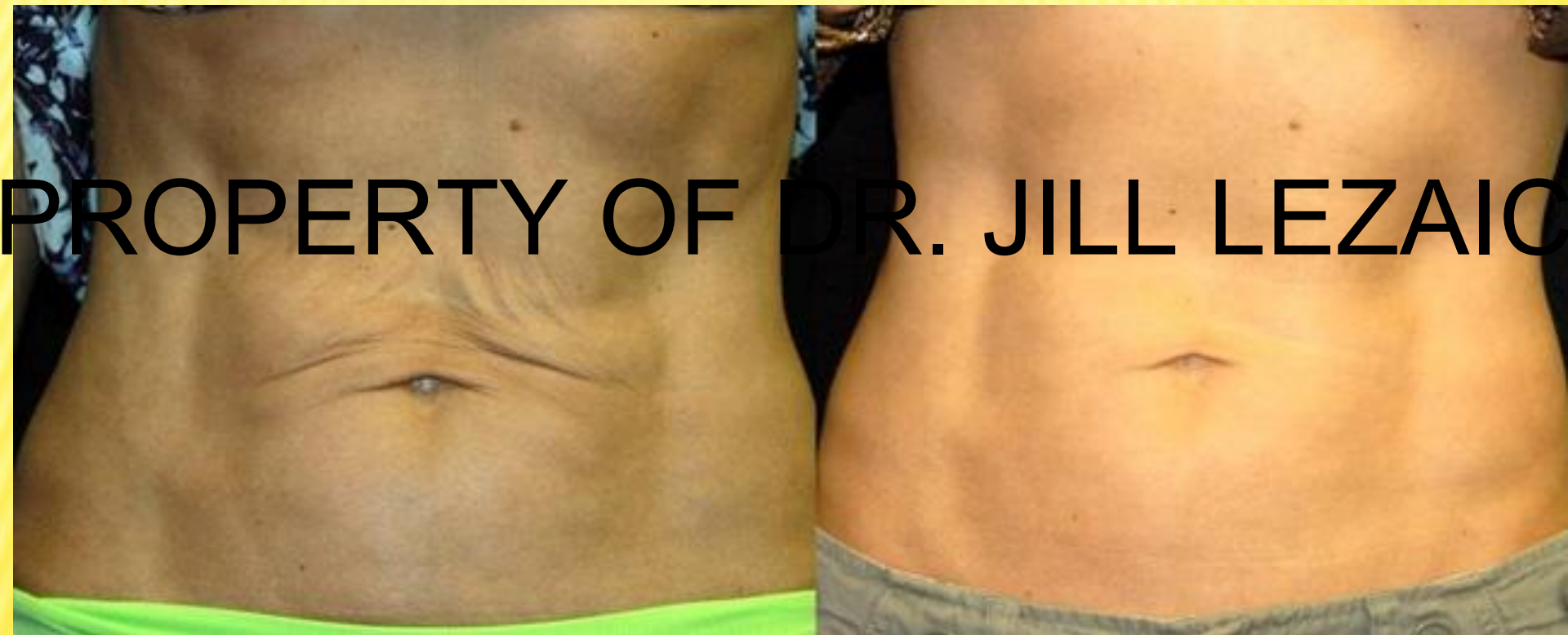After 5 treatments

PROPERTY OF DR. JILL LEZAIC

Titan & Laser Genesis

Before


After 3 Treatments



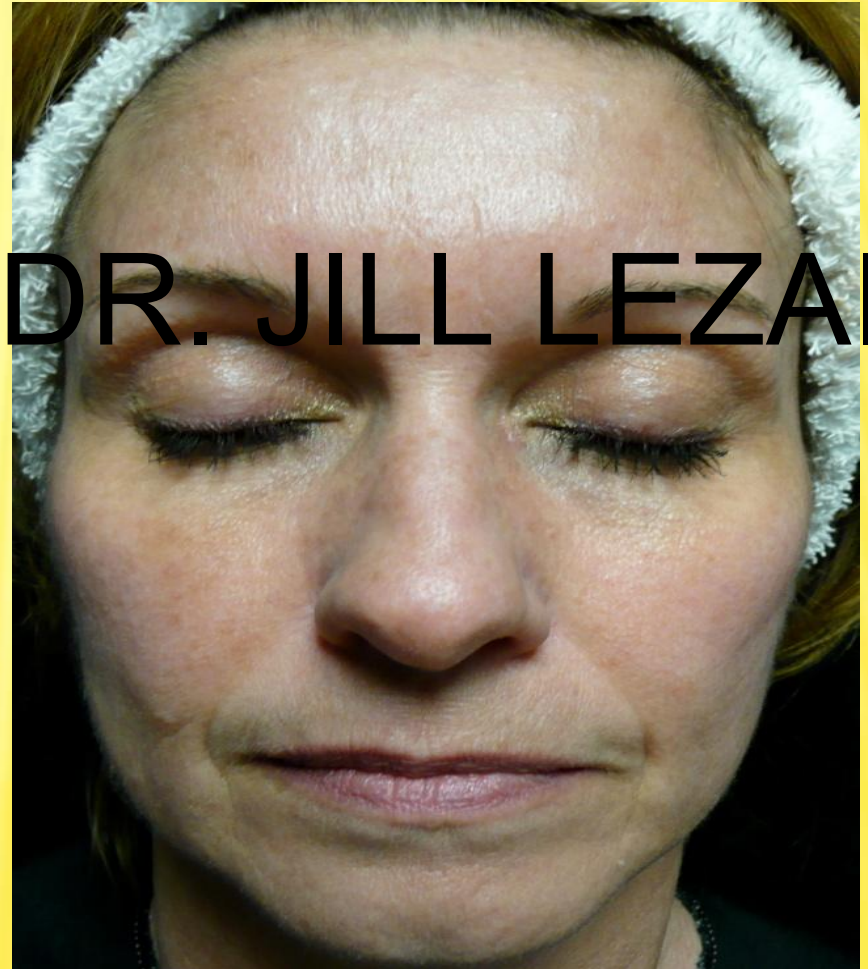Photos courtesy of Echo Rowe, MD

TITAN, GENESIS, IPL

✘ Before

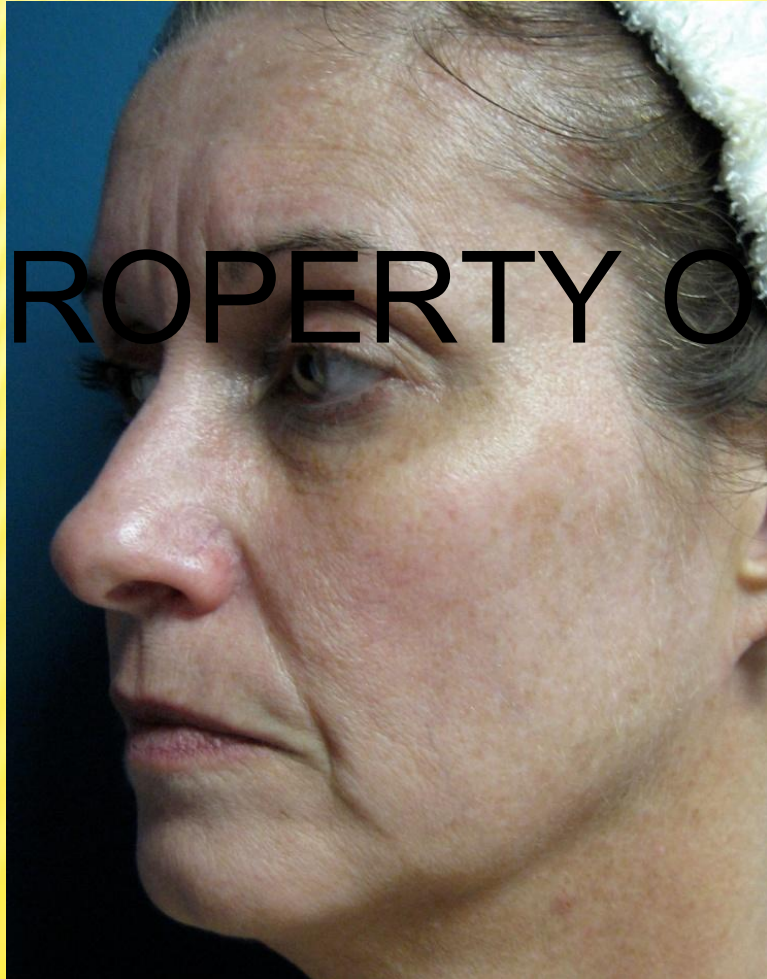

✘ After



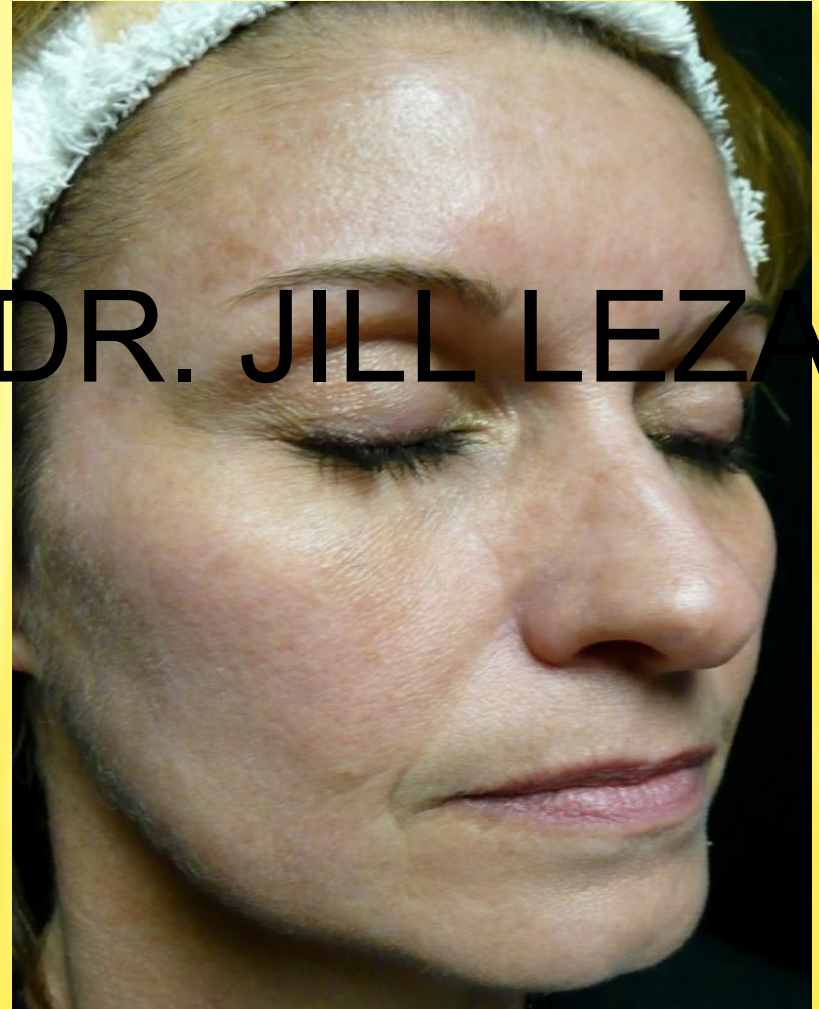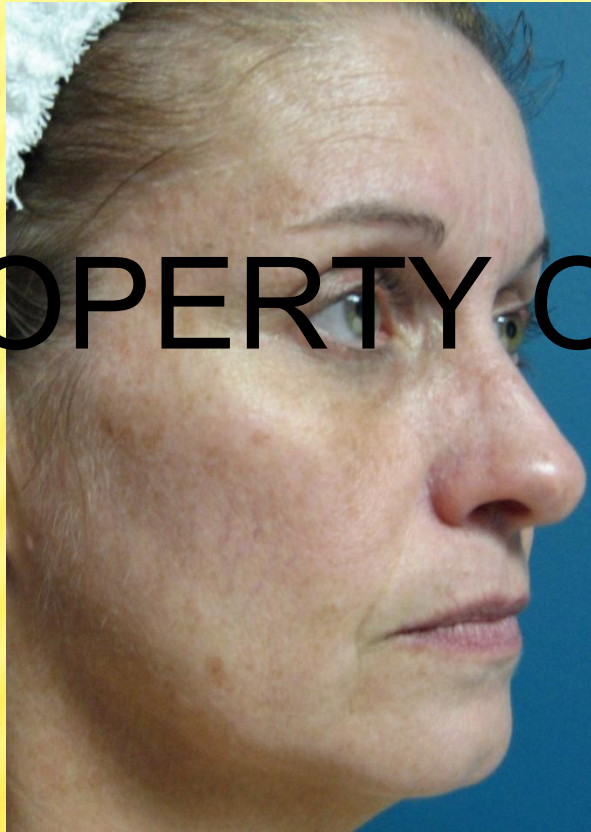PROPERTY OF DR. JILL LEZAIC

LASER GENESIS, IPL



PROPERTY OF DR. JILL LEZAIC

LASER GENESIS, IPL



PROPERTY OF DR. JILL LEZAIC

CONSULTATIONS

- If you are interested in any procedure, please ask us for more information.
- If you'd like to schedule a consultation or treatment, please see Sharon before leaving tonight.
- We have appointments available on Tuesdays & Saturdays as needed.

PROPERTY OF DR. JILL LEZAIC

- Consultations include:
 - Tailored recommendations for the best possible ways to treat any of your concerns.
 - Fillers can be a consultation & treatment in the same visit.
 - Some laser procedures require some preparation & must be scheduled after a thorough consultation.
 - Some laser procedures (hair removal, Genesis) can be done in the same visit.

PROPERTY OF DR. JILL LEZAIC

THANK YOU!

Laser Skin Solutions Jacksonville